COLUMBIA LIBRARIES OFFSITE
HEALTH SCIENCES STANDARD
HX00014680

OPERATIVE SURGERY

TH. KOCHER

Columbia University
in the City of New York

College of Physicians and Surgeons

Library

Digitized by the Internet Archive
in 2010 with funding from
Open Knowledge Commons (for the Medical Heritage Library project)

http://www.archive.org/details/textbookofoperat00koch

B. P. Watson. M. D.

TEXT-BOOK

OF

OPERATIVE SURGERY

B. P. Watson. M.D.

TEXT-BOOK

OF

OPERATIVE SURGERY

BY

DR. THEODOR KOCHER

PROFESSOR OF SURGERY AND DIRECTOR OF THE SURGICAL CLINIC
IN THE UNIVERSITY OF BERN

TRANSLATED WITH THE SPECIAL AUTHORITY OF THE AUTHOR FROM
THE SECOND REVISED AND ENLARGED GERMAN EDITION

BY HAROLD J. STILES, M.B., F.R.C.S. EDIN.

SENIOR DEMONSTRATOR OF SURGERY AND FORMERLY DEMONSTRATOR OF ANATOMY
IN THE UNIVERSITY OF EDINBURGH
ASSISTANT SURGEON, ROYAL EDINBUROH HOSPITAL FOR SICK CHILDREN

WITH 185 ILLUSTRATIONS

LONDON
ADAM AND CHARLES BLACK
1895

RD32
K811
1895

TRANSLATOR'S PREFACE

No apology is needed for the endeavour to render more accessible to the profession in this country, a work on Operative Surgery by so eminent an authority as Professor KOCHER.

The book is essentially a record of the Author's personal experience, and of his own methods of operation. To avoid an appearance of egotism he has written in the first person plural, and this plan has been followed in the translation.

It has been found necessary to make a few alterations in the translation of the more purely anatomical descriptions, to keep them in harmony with those employed by English anatomists. Otherwise the aim has been to adhere to the original as closely and as literally as possible.

I desire to express my thanks to my friends Dr. G. LOVELL GULLAND and Mr. ALEXIS THOMSON for the assistance they have given me with the translation, and to Dr. ERNEST FORTUNE for aiding me with the proofs.

I gladly take this opportunity to express my warm thanks to Professor KOCHER for entrusting to me the translation of his text-book, and for the valuable privileges I enjoyed while attending his Clinic.

HAROLD J. STILES.

5 CASTLE TERRACE,
EDINBURGH, *May* 1895.

AUTHOR'S PREFACE TO THE SECOND EDITION

In expressing our thanks both for the numerous very favourable reviews of the first edition and also for those written in a more critical spirit, we consider it necessary again to emphasise the fact that in writing this text-book we have aimed at making it not merely useful for teaching purposes, but also, in view of the author's extensive experience, a reliable guide to general practitioners and surgeons in operating on the living subject. It may be that the book loses in this way the definiteness of arrangement desirable for teaching. We are of opinion, however, that the student ought to learn everything in the way in which he will require to do it in practice.

We have described the methods of exposing some of the less important nerves and arteries because they run in the lines of incisions which have frequently to be employed. We refer especially to those incisions which we have described and illustrated as "normal incisions." Considering the serious functional results which often arise in consequence of incisions made by unskilful and unpractised hands, it does not appear to be superfluous to lay down definite rules for every part of the body. As it is probable that technical mistakes will be subjected to severer criticism in the future, we have in the case of the more important operations mentioned only those methods concerning which we possess reliable personal experience. Part of the descriptions have been taken down to dictation in shorthand by an assistant during the performance of the operation on the living subject. That which is of no practical use has not been mentioned, because the text-book ought to be a preparation for that examination to which the practitioner has daily to be subjected in his calling.

We crave indulgence from our specialist colleagues for not being able to do full justice to the work of other authors; but the complete recasting and extending of the work, especially as regards the illustrations, which have been mostly reproduced from operations on the cadaver and

on the living subject, have occupied all our available time. Should a new edition be called for, these omissions will be filled in. Meanwhile, for comparative methods we must refer the reader to the excellent recent works of HEINECKE, BERGMANN, ROTTER, F. TREVES, and especially to the admirably illustrated work of ESMARCH and KOWALZIG.

The illustrations have been drawn with great skill, partly by the former artist, Mr. KEINER, drawing-master in St. Imier, and partly by Mr. WESSER. The woodcuts are the work of Mr. G. FISCHER'S able engraver. Our former first assistant, Dr. LARDY, now chief surgeon to the French Hospital in Constantinople, was good enough to construct the plate showing the normal incisions, which have since been somewhat supplemented. In the investigations upon cranio-cerebral topography I have been assisted chiefly by Dr. LANZ, and in the performance of the operations for the illustrations, in addition to him, by Drs. DUMONT, FLACH, DE QUERVAIN, MOSSIMANN, ARND, and others.

I am greatly indebted to my publisher, who has spared no sacrifice in perfecting the production of the book.

CONTENTS

PART I

Principles

PAGE

A. INTRODUCTION 1

B. ANÆSTHESIA 3

Local Anæsthesia—Ether Spray—Cocaine Injection—General Anæsthetics—Ether—Chloroform—Ethyl Bromide—Methylene Chloride.

C. WOUND TREATMENT 9

Air Infection—Contact Infection—Implantation Infection—Carbolic Acid and Corrosive Sublimate—Heat (steam and boiling)—Disinfection of Hands—Asepsis and Antisepsis—Wound Suturing and Open Wound Treatment—Drainage and Secondary Suture—Healing under a Scab—Permanent Antisepsis—Subnitrate of Bismuth and Iodoform.

D. DIRECTION OF SKIN-INCISIONS 21

Drain Openings—Normal Incisions.

PART II

Special Operations

E. CRANIUM 34

(*a*) *Soft parts* 34

PAGE

(1) Temporal Artery and Vein . 34
Auriculo-Temporal Nerve . 34
(2) Supraorbital Artery . . . 35
Supraorbital, Supratrochlear, and Nasal Nerves. . . 35
(3) Supratrochlear Nerve . . 36
(4) Nasal Nerve 37
(5) Occipital Artery . . . 37
Great and Small Occipital Nerves 37
(6) Great Occipital Nerve . . 37

(*b*) *Relations of the Cerebral Convolutions to the Skull* 39

(*c*) *Cortical Centres of the Brain* 42

(*d*) *Trephining* 46

(7) Longitudinal Sinus . . . 47
(8) Lateral Sinus 47
(9) Middle Meningeal Artery . 48
(10) Frontal Sinus . . . 50
(11) Mastoid Process . . . 52
(12) Cerebellum 53

PAGE

F. FACIAL PORTION OF THE HEAD 53

(13) Ligature of the Facial Artery . 53
(14) Operations on the Nose and Nasal Cavities . . . 54

Exposure of the Base of the Skull and of the Roof of the Nose 55

Operations on the Nerves of the Face 57

(15) Facial Nerve 57

Trigeminal Nerve 59

(16) Second Division of 5th Nerve . 59
(17) Orbital Branch . . . 59
(18) Superior Maxillary Nerve at the Foramen Rotundum . . 60
(19) Mental Nerve 63
(20) Inferior Dental Nerve . . 63
(21) Lingual Nerve . . . 65
(22) Auriculo-Temporal Nerve . 65
(23) Buccinator Nerve . . . 65
(24) Inferior Maxillary Nerve . . 66
(25) Resection of the Upper Jaw . 69
(26) Osteoplastic Total Resection of the Upper Jaw . . . 71
(27) Resection of the Lower Jaw . 72
(28) Osteoplastic Resection of the Lower Jaw 73
(29) Transverse Splitting of the Cheek 74
(30) Incisions into the Tongue and the Floor of the Mouth . 74
(31) Excision of the Tongue . . 75
(32) Tonsillotomy 77

G. THE SUPERIOR LATERAL TRIANGLE OF THE NECK 77

The Normal Incision for

(33) External (and Internal) Carotid 79
(34) Superior Thyroid Artery . . 80
(35) Lingual Artery . . . 80
(36) Ligature of the Internal Carotid 82
(37) Exposure of the Hypoglossal Nerve 83
(38) Exposure of the Lingual Nerve 83
(39) Superior Laryngeal Nerve . 83
(40) Ligature of the Internal Jugular Vein 83
(41) Spinal-Accessory Nerve . . 83
(42) Lateral Pharyngotomy . . 85
(43) Subhyoid Pharyngotomy . 86

H. THE ANTERIOR TRIANGLE OF THE NECK 89

(44) Common Carotid Artery . . 89
(45) Ligature of the Internal Jugular Vein 90
(46) Resection of the Vagus Nerve . 90
(47) Ligature of the Inferior Thyroid and Vertebral Arteries 90
(48) Vertebral Artery . . . 92
(49) Œsophagotomy . . . 92
(50) Retropharyngeal Space . . 93

Laryngotomy and Tracheotomy 94

(51) Tracheotomy 94
(52) Laryngotomy and Laryngectomy 96
(53) Laryngectomy 97
(54) Excision of the Diseased Thyroid Gland 99
(55) Resection of Goitre . . 105
(56) Innominate Artery . . 105

J. THE INFERIOR LATERAL TRIANGLE OF THE NECK 107

(57) Subclavian Artery . . . 107
(58) Spinal-Accessory Nerve . . 109
(59) Transverse Superficial Cervical Nerve 109
(60) Great Auricular Nerve . . 109

K. BACK OF THE NECK 110

L. THORAX 110

(61) Internal Mammary Artery . 110
(62) Intercostal Artery . . . 112
(63) Intercostal Nerve . . . 112
(64) Amputation of the Mamma, with clearing out of the Axilla . 112
(65) Opening the Pleural Cavity . 115
(66) Resection of Ribs . . . 116
(67) Exposure of the Convex Surface of the Liver . . . 117
(68) Resection of larger pieces of the Chest Wall . . . 117
(69) Operations on the Lung . . 119

PAGE

M. BACK 119

(70) Ligature of the Posterior Scapular Artery . . . 119
(71) Suprascapular Nerve . . 120
(72) Dorsalis Scapulæ Artery from behind 120
(73) Opening the Posterior Mediastinum 121
(74) Opening the Spinal Canal . 121

N. LUMBAR REGION 121

(75) Nephrotomy and Nephrectomy 122
(76) Ureterotomy 125
(77) Splenectomy 125

O. ABDOMEN 126

Normal Incisions 126

Epigastrium 126

(78) Gastrostomy 126
(79) Gastro-Enterostomy . . 127

Pylorectomy 132

(80) Resection of the Pylorus . . 133

Hypochondrium 140

(81) Cholecystotomy . . . 140
(82) Cholecystectomy . . . 142

Umbilical Region 142

(83) Radical Operation for Umbilical Hernia 143

Hypogastric and Iliac Regions 143

(84) Puncturing the Abdomen . 143

The Groin 144

(85) Exposure of the Spermatic Cord. Operation for Varicocele. Castration. Excision of the Tunica Vaginalis . 144
(86) Herniotomy and Radical Operations for Inguinal and Femoral Hernia . . . 145
(87) Isolation of the Round Ligament. Alexander's Operation for Prolapsus Uteri . . 150
(88) Resection of the Vermiform Appendix 152
(89) Ileo-Cæcal Resection . . 153
(90) Making a Fæcal Fistula . . 155
(91) Making an Artificial Anus . 156
(92) Resection of Intestine . . 156

Operations on the Bladder 160

(93) Suprapubic Cystotomy . . 160
(94) Opening the Bladder, with Resection of the Symphysis . 162
(95) Puncturing the Bladder . 162

P. PERINEUM 162

(96) Perineal Lithotomy . . 162
(97) Opening the Spongy and Bulbous Urethræ . . . 163
(98) Opening the Membranous and Prostatic Urethræ . . 163
(99) Internal Pudic Artery and Nerve in the Perineum . 166

Q. SACRAL REGION 167

(100) Excision of the Rectum . 167

Excision of the Rectum by the Parasacral Incision 169

PAGE

R. UPPER EXTREMITY 171

(a) *Region of the Shoulder* 171

(101) First part of Axillary Artery . 171
(102) Superior Thoracic Artery . 173
(103) Acromio-Thoracic Artery . 173
(104) Long Thoracic Artery . . 174

(b) *Axilla* 174

(105) Third part of Axillary Artery 174
(106) Anterior Circumflex Artery . 174
(107) Posterior Circumflex Artery and Circumflex Nerve . 177
(108) Subscapular Artery and Subscapular Nerves . . . 177
(109) Long Subscapular Nerve . 177
(110) Dorsalis Scapulæ Artery . 177

(c) *Upper Arm* 177

(111) Brachial Artery (middle third) 179
(112) Superior Profunda Artery . 179
(113) Inferior Profunda Artery . 180
(114) Anastomotica Magna Artery . 180
(115) Median Nerve . . . 180
(116) Ulnar Nerve in the lower half of the Upper Arm . . 180
(117) Musculo-Spiral Nerve . . 180
(118) Musculo-Cutaneous Nerve . 181

(d) *Region of the Elbow* 181

(119) Brachial Artery at the Bend of the Elbow 181
(120) Median Nerve . . . 183
(121) Ulnar Nerve 183
(122) Musculo-Spiral Nerve . . 184

(e) *Forearm—Anterior Surface* 184

(123) Radial Artery 184
(124) Ulnar Artery 185
(125) Interosseous Artery . . 187
(126) Median Nerve . . . 187
(127) Palmar Cutaneous Nerve . 187
(128) Interosseous Branch of the Median Nerve . . . 187

Deep Incisions upon the Anterior Aspect of the Forearm 188

(f) *Forearm—Posterior Surface* 188

(129) Posterior Interosseous Nerve . 188

Incisions upon the Posterior Aspect of the Forearm 189

(g) *Wrist-Joint—Anterior Aspect* 190

(130) Ulnar Artery at the Pisiform Bone 190
(131) Median Nerve . . . 190

(h) *Hand—Dorsal Aspect* 190

(132) Radial Artery at the Back of the Hand 190
(133) Radial Artery upon the Os Trapezium 191
(134) Dorsal Branch of the Ulnar Nerve 191
(135) Radial Nerve 192

(i) *Palm of the Hand* 192

(136) Superficial Palmar Arch . 192
(137) Deep Palmar Arch . . . 193
(138) Median Nerve . . . 193
(139) Common Digital Arteries . 193

Fingers 195

S. LOWER EXTREMITY 196

Buttock 196

(141) Gluteal Artery . . . 196
(142) Sciatic Artery . . . 196
(143) Small Sciatic Nerve . . 197
(144) Great Sciatic Nerve . . 197
(145) Internal Pudic Artery . . 197

Region of the Groin 197

(146) Common Iliac Artery (and Abdominal Aorta) . . 197
(147) Spermatic Artery . . . 199
(148) Ureter 199
(149) Inferior Mesenteric Artery . 199
(150) External Iliac Artery . . 199
(151) Deep Epigastric Artery in the Anterior Abdominal Wall . 202
(152) Deep Circumflex Iliac Artery 203
(153) Internal Iliac Artery . . 203
(154) Obturator Artery and Obturator Nerve . . . 203

PAGE

Thigh—Anterior Surface 204
(156) Femoral Artery . . . 204
(157) (*a*) Profunda Artery at its Origin, and External Circumflex Artery . . 208
(*b*) Terminal Branch of the External Circumflex Artery 210
(*c*) Profunda Artery at the Adductor Longus . 210
(158) Internal Circumflex Artery . 210
(159) Anastomotica Magna Artery . 210
(160) Anterior Crural Nerve . . 211
(161) Internal Saphenous Nerve . 211
(162) External Cutaneous Nerve . 211

Thigh—Posterior Surface 211
(163) Great Sciatic Nerve . . 211

Popliteal Space 214
(164) Popliteal Artery . . . 214
(165) External Popliteal Nerve . 216
(166) Peroneal communicating Nerve 216

Leg—Anterior and Outer Surfaces 216
(167) Anterior Tibial Artery . . 216
(168) Anterior Tibial Nerve near its Origin 217
(169) Musculo-Cutaneous Nerve . 217

Leg—Posterior and Inner Surfaces 217
(170) Posterior Tibial Artery above origin of Peroneal . . 217
(171) Posterior Tibial Artery below origin of Peroneal . . 220
(172) Internal Saphenous Nerve . 222
(173) Peroneal Artery . . . 222
(174) Cutaneous Branch of the External Popliteal Nerve . 224
(175) Communicans Tibialis Nerve . 224
(176) Posterior Tibial Nerve . . 224

Foot 224
(177) Plantar Arteries at their Origin 224
(178) Internal Plantar Artery and Internal Plantar Nerve . 224
(179) Internal Plantar Nerve . . 225
(180) External Plantar Artery . 225
(181) External Plantar Nerve . . 225
(182) Plantar Arch 225
(183) Dorsalis Pedis Artery . . 228

PART III

Excisions and Resections

T. PRINCIPLES 229

U. LOWER EXTREMITY 231
(184) Excision of the Phalanges, and of the Metatarsal Bones . 231
(185) Resection of the Tarso-Metatarsus, and of the Anterior Tarsus 231
(186) Resection of the Mid-Tarsus . 233
(187) Excision of the Astragalus . 235
(188) Excision of the Os Calcis . 236
(189) Resection of the Calcaneo-Astragaloid Joint, and Resection of the Posterior Tarsus . 237
(190) Resection of the Ankle-Joint . 237
(191) Resection of the entire Tarsus 240
(192) Resection of the Lower Third of the Leg 241
(193) Resection of the Tibia . . 241
(194) Resection of the Fibula . . 242
(195) Arthrotomy of the Knee, and Resection of the Knee . . 242
(196) Resection of the Patella . . 248
(197) Osteotomy and Cuneiform Resection of the Tibia . . 248
(198) Supracondyloid Osteotomy of the Femur 248
(199) Osteotomy and Subtrochanteric Cuneiform Resection of the Femur 249
(200) Resection of the Diaphysis of the Femur 250
(201) Resection of the Hip-Joint . 250
(202) Resection of one-half of the Pelvis 254

PAGE

V. UPPER EXTREMITY 254

(203) Excision of the Phalanges, of the Metacarpal Bones, and of the Interphalangeal and Metacarpo-Phalangeal Joints 254
(204) Resection of the Wrist-Joint . 255
(205) Resection of the Ulna . . 260
(206) Resection of the Radius . . 260
(207) Resection of the Elbow-Joint . 260
(208) Resection of the Diaphysis of the Humerus . . . 264
(209) Resection of the Shoulder-Joint 264
(210) Resection of the Clavicle, of the Sterno-Clavicular Joint, and of the Acromio-Clavicular Joint 269
(211) Resection of the Scapula . 270

PART IV

Amputations and Disarticulations

INTRODUCTION 272

Evolution of the Methods of Amputation 273

X. LOWER EXTREMITY 280

Amputations at the Foot 280

(212) Removal of a Toe with and without its Metatarsal Bone 280
(213) Disarticulation of all the Toes 280
(214) Amputation through the Metatarsus . . . 280
(215) Tarso-Metatarsal Disarticulation 281
(216) Anterior Intertarsal Disarticulation 283
(217) Posterior Intertarsal Disarticulation 283
(218) Amputation through the Posterior Tarsus . . . 284
(219) Subastragaloid Disarticulation 284
(220) Osteoplastic Subastragaloid Amputation . . . 285
(221) Disarticulation at the Ankle . 285
(222) Osteoplastic Amputation at the Ankle 285
(223) Amputation through the Leg . 286
(224) Disarticulation at the Knee . 289
(225) Amputation through the Thigh 289
(226) Amputation through the Condyles 290
(227) Supracondyloid Amputation . 290
(228) Amputation through the Middle of the Thigh . . 291
(229) Amputation through the Upper Third of the Thigh . . 292
(230) Disarticulation at the Hip . 292

Y. UPPER EXTREMITY 295

(231) Amputation and Disarticulation of the Finger . . 295
(232) Disarticulation at the Wrist . 296
(233) Amputation through the Fore-Arm 297
(234) Disarticulation at the Elbow . 297
(235) Amputation through the Upper Arm 298
(236) Disarticulation at the Shoulder 299
(237) Disarticulation of the Arm together with the Shoulder Girdle 301

LIST OF ILLUSTRATIONS

FIG.		PAGE
1.	Chloroform Mask	6
2–6.	Diagrams showing the Behaviour of Incisions for Drainage	22–24
7–15.	The Author's "Normal Incisions"	25–32
16.	Ligature of the Facial and Temporal Arteries. Trephining the Jaw to expose the Inferior Dental Nerve	35
17.	Ligature of the Supraorbital Artery. Exposure of the Supraorbital and Infra-orbital Nerves. Opening of the Frontal Sinus	36
18.	Ligature of the Occipital Artery. Exposure of the Great and Small Occipital Nerves	38
19, 21.	Fixed Points for determining the Relations of the Cerebral Convolutions to the Surface of the Cranium	40, 44
20, 22.	Relation of the Fixed Points to the Cerebral Convolutions (Centres in Fig. 20 mapped in according to HORSLEY)	41, 45
23.	Centres upon the Inner Surface of the Hemisphere, after HORSLEY	46
24.	Post-Auricular Incision for opening the Mastoid Antrum, the Lateral Sinus, and the Lateral Ventricle	48
25.	Opening the Mastoid Antrum and the Lateral Sinus. Exposure of the Temporo-Sphenoidal Lobe and Puncture of the descending Horn of the Lateral Ventricle	49
26.	Ligature of the Middle Meningeal Artery	50
27.	Ligature of the Supraorbital Artery. Exposure of the Supraorbital and Infra-orbital Nerves. Opening of the Frontal Sinus	51
28.	Ligature of the Facial, Inferior Thyroid, and Vertebral Arteries	54
29.	Incision for resecting the Third Division of the Fifth Nerve at the Foramen Ovale. Exposure of the Facial Nerve	58
30, 31.	Resection of the Second Division of the Fifth Nerve	60, 61
32.	Ligature of the Facial and Temporal Arteries. Trephining the Jaw to expose the Inferior Dental Nerve	64
33.	Exposure of the Third Division of the Fifth Nerve at the Foramen Ovale	66
34.	Result after complete Excision of the Upper Jaw	69
35.	Action of the Facial Muscles after the healing of an extensive Transverse Splitting of the Cheek	75
36.	Ligature of the External Carotid and Subclavian Arteries	78
37.	Ligature of the Lingual, Common Carotid, Innominate, 1st part of the Axillary, and the Internal Mammary Arteries	81
38.	Exposure of the Spinal-Accessory Nerve in the Middle of the Neck	84
39.	Subhyoid Pharyngotomy	87
40.	Ligature of the Facial, Inferior Thyroid, and Vertebral Arteries	91
41.	High Tracheotomy	94
42, 43.	Excision of a Goitre by a Transverse Curved Incision	98, 99
44, 45.	Excision of a Goitre by an Angular Incision	100, 101
46.	Enucleation-Resection of an Hypertrophied Thyroid Nodule	104
47.	Ligature of the Lingual, Common Carotid, Innominate, 1st part of the Axillary, and the Internal Mammary Arteries	106

FIG.		PAGE
48.	Ligature of the External Carotid and Subclavian Arteries	108
49.	Ligature of 10th Intercostal and Posterior Scapular Arteries	111
50.	Amputation of the Mamma and clearing out of the Axilla	113
51.	Resection of a Portion of two Ribs	116
52.	Exposure of the Convex Surface of the Liver through the 7th Intercostal Space	118
53.	Ligature of the Posterior Scapular Artery	120
54.	Nephrotomy. Exposure of the Vessels and Nerves of the Buttock	123
55, 56.	Gastrostomy (Albert's Operation, modified)	128, 129
57.	Gastro-Jejunostomy	130
58–60.	Pylorectomy	135–137
61.	Cholecystotomy. Ligature of the Common Iliac, Deep Circumflex Iliac, and Common Femoral Arteries	141
62–65.	Radical Operation for Inguinal Hernia	148, 149
66.	Operation for Retroflexion and for Prolapse of the Uterus	151
67, 68.	Resection of the Vermiform Appendix	153, 154
69.	Formation of a Fæcal Fistula	155
70.	Formation of an Artificial Anus	156
71–73.	Resection of Intestine	158, 159
74.	Exposure of the Root of the Penis	164
75.	Exposure of the Prostate and Vesiculæ Seminales from the Perineum	165
76.	Ligature of the Lingual, Common Carotid, Innominate, 1st part of the Axillary, and Internal Mammary Arteries	172
77.	Ligature of the Axillary Artery above or immediately below the Pectoralis Minor	173
78.	Ligature of the Axillary (3rd part), Subscapular, Superior Profunda, Brachial, and Inferior Profunda Arteries. Exposure of the Median, Musculo-Spiral, and Ulnar Nerves	175
79.	Ligature of the Anterior Circumflex Artery. Exposure of the Musculo-Cutaneous Nerve	176
80.	Ligature of the Posterior Circumflex and Superior Profunda Arteries. Exposure of the Circumflex and Musculo-Spiral Nerves	178
81.	Ligature of the Brachial, Radial, and Ulnar Arteries	182
82.	Exposure of the Ulnar Nerve at the Internal Condyle	183
83.	Exposure of the Median Nerve at the Upper, Middle, and Lower Thirds of the Forearm	186
84.	Exposure of the Posterior Interosseous and Dorsal Branch of the Ulnar Nerves	189
85.	Ligature of the Radial Artery at the Back of the Wrist	191
86.	Ligature of the Superficial and Deep Palmar Arches	194
87.	Nephrotomy. Exposure of the Vessels and Nerves of the Buttock	198
88.	Cholecystotomy. Ligature of the Common Iliac, Deep Circumflex Iliac, and Common Femoral Arteries	200
89.	Ligature of the Common Iliac Artery	201
90.	Ligature of the Deep Epigastic Artery	202
91.	Ligature of the Obturator Artery	204
92.	Ligature of the Common Femoral Artery. Exposure of the External Cutaneous Nerve	206
93.	Ligature of the Femoral Artery at the Apex of SCARPA's Triangle, and at the Lower Part of HUNTER's Canal; and of the Anastomotica Magna and Upper Part of the Popliteal Arteries	207
94.	Ligature of the External Circumflex Artery	208
95.	Ligature of the Internal Circumflex and Profunda Arteries	209
96.	Exposure of the Internal Saphenous Nerve at the Internal Condyle of the Femur	212
97.	Exposure of the Great Sciatic, and of the Internal and External Popliteal Nerves	213
98.	Ligature of the Popliteal Artery	214
99.	Ligature of the Anterior Tibial Artery	215

FIG. PAGE
100. Exposure of the Anterior Tibial and Musculo-Cutaneous Nerves . . 218
101. Ligature of the Posterior Tibial Artery above the Origin of the Peroneal . 219
102. Exposure of the Internal Saphenous Nerve at the Inner Tuberosity of the Tibia. Ligature of the Posterior Tibial Artery 221
103. Ligature of the Peroneal Artery. Exposure of the Short Saphenous Nerve . 223
104. Ligature of the Plantar Arteries close to their Origin 225
105. Ligature of the Plantar Arteries and Exposure of the Plantar Nerves . . 226
106. Ligature of the Plantar Arch 226
107. Ligature of the Dorsalis Pedis Artery, and Exposure of the Anterior Tibial and Musculo-Cutaneous Nerves 227
108. Resection of the Phalanges, and of the 1st and 5th Metatarsal Bones . . 232
109. Resection of the Anterior Tarsus 232
110–112. Resection of the Mid-Tarsus 233–235
113. Excision of the Astragalus (External Incision) 236
114. Excision of Os Calcis 236
115. Coronal Section through the Ankle-Joint (HENLE) 236
116. Resection of the Posterior Tarsus 237
117, 118. Arthrotomy and Resection of the Ankle-Joint 238, 239
119. Resection of the entire Tarsus (WLADIMIROFF, MIKULICZ) . . . 241
120. Result after complete Resection of the Tarsus 241
121. Resection of the Lower Third of the Leg 241
122. Resection of the Knee 242
123, 124. Arthrotomy of the Knee 246, 247
125. Osteotomy of the Femur and Tibia 248
126, 127. Subtrochanteric Osteotomy of the Femur 249
128, 129. Resection of the Hip-Joint 251, 252
130. Incisions for Resection of the Innominate Bone, and of the Hip-Joint . . 253
131. Resection of the Phalanges, and of the 1st Metacarpal Bone 255
132. Resection of the Phalanges, and of the Metacarpal Bones. (Coronal Section of the Wrist, after HENLE) 255
133, 134. Resection of the Wrist 256, 257
135, 136. Arthrotomy and Resection of the Elbow-Joint 261, 263
137, 138. Resection of the Head of the Humerus by the Anterior Oblique Incision. 265, 266
139, 140. Arthrotomy and Resection of the Shoulder-Joint by the Posterior Curved Incision 267, 268
141. Resection of the Scapula 270
142. Relation of the Line of Suture to the Stump in the Transverse Circular Amputation 274
143. Relation of the Line of Suture in the Oblique Circular Amputation . . 274
144–148. Schemes showing the Evolution of the different Methods of Amputation from the Simple Transverse and Oblique Circular Methods . . 275, 276
149–151. Method of performing the Transverse Circular Amputation . . 277
152–154. Method of performing the Oblique Circular Amputation . . . 277
155. Disarticulation of the Toes at the Interphalangeal, Metatarso-Phalangeal, and Tarso-Metatarsal Joints 281
156. Disarticulation of all the Toes at the Metatarso-Phalangeal Joints . . 281
157. Amputation through the Metatarsus 281
158, 159. Disarticulation at the Tarso-Metatarsal Articulation (LISFRANC) . . 282
160. Anterior Intertarsal Disarticulation (JÄGER). (Horizontal Section of the Foot, after HEITZMANN) 283
161. Posterior Intertarsal Disarticulation (CHOPART) 283
162. Subastragaloid Disarticulation (MALGAIGNE, TEXTOR) 284
163. Disarticulation at the Ankle (SYME, modified) 285
164. Coronal Section through the Ankle-Joint, after HENLE 285
165. Osteoplastic Disarticulation of the Foot (PIROGOFF) 286
166. Amputation through the Malleoli 287
167. Amputations through the Leg 287

FIG.		PAGE
168.	Section through the Upper Half of the Leg	287
169.	Disarticulation at the Knee	288
170.	Section through the Knee-Joint at the Level of the Condyles of the Femur (after BRAUNE)	289
171.	Amputation through the Condyles of the Femur (CARDEN)	290
172.	Osteoplastic Amputation above the Condyles (GRITTI)	290
173.	Amputations through the Thigh	291
174.	Section through the Thigh	291
175.	Disarticulation at the Hip	293
176.	Coronal Sections through the Hip and Knee Joints, after HENLE	293
177.	Longitudinal Section through the Flexed Finger	295
178.	Disarticulation at the Interphalangeal, Metacarpo-Phalangeal, and Carpo-Metacarpal Joints	295
179.	Disarticulation at the Wrist, and Amputation through the Forearm	296
180.	Section through the Upper Third of the Forearm	297
181.	Disarticulation at the Elbow (Longitudinal Section of the Elbow, after BRAUNE)	298
182.	Ligaments of the Elbow-Joint	298
183.	Amputation through the Upper Arm	299
184.	Disarticulation at the Shoulder	300
185.	Disarticulation of the Upper Extremity, including the Shoulder Girdle	301

PART I

GENERAL CONSIDERATIONS

A. INTRODUCTION

Thanks to antiseptics, we are now able to bring about rapid healing in all sutured operation-wounds, however large; and the result has been that operative surgery has made extraordinary strides.

As soon as we are sure of our antisepsis, we may cut down upon any part of the body, not only with a therapeutic, but also with a diagnostic intent. It is all the more our duty therefore, in view of the extraordinary widening of the indications for operative treatment, to make our technique as perfect as possible, so that the first maxim of therapeutics—"*nil nocere*"—may be observed. A complete mastery of technique, which depends chiefly upon a minute knowledge of anatomy, is, next to a reliable antiseptic wound treatment, the condition most essential to the practice of operative surgery. In practice it is not possible to study anatomical handbooks and atlases previous to every operation; moreover, these text-books are generally written from the purely anatomical standpoint, and do not pay that minute attention to details which the surgeon desires. It is not, therefore, our intention to add to the many excellent text-books of operative surgery, one still more detailed, but we purpose to produce a book after the plan of Rosser's excellent *Vade mecum*, which shall be as succinct as possible, and suitable for rapid reference regarding any particular operation.

Although this book may be used as a guide to operations on the cadaver, the performance of operations on the *living subject* has been especially kept in view, and therefore only those methods which the author's large clinical experience has proved to be trustworthy and reliable have been recommended. We do not wish, however, to put forward our methods as better than those of other surgeons; on the contrary, we hope later to supply omissions, and also to give credit to the originators of operations which we have described, as well as

to those who have proposed other methods. We crave indulgence also for having omitted to deal more fully with the historical development and significance of different methods of operation.

The most important task entailed in the production of a text-book of operative surgery, which is to be of value as a guide to operations on the living subject, appears to us to be to place the reader in a position to obtain ready and accurate information regarding the route which the knife has to follow in cutting down, however deep, upon every region of the body.

The most important point to be considered in surgical interference is the making of *incisions* in a direction most calculated to give free access, and at the same time to avoid unnecessary injury, to adjacent structures. We must learn to avoid not only the vessels, but also the large and small nerve branches; in other words, we must choose for our incisions the frontier between neighbouring nerve distributions.

From this point of view, therefore, we regard certain incisions as typical for special regions of the body; that is to say, they are the only incisions permissible when a free choice is open to us. It is in the laying down of simple rules for the performance of more accurate and more sparing procedures that we ourselves look for the value of our contributions.

Excisions or *resections* constitute a second group of operations. Here we have to deal, not merely with incisions made for the purpose of reaching a deep structure by the most direct route, but with the removal from the body of a portion of tissue or an entire organ; the deeper parts must therefore be so exposed as to render the diseased area sufficiently visible and palpable.

Resections of bones and joints furnish the type of excisions, and along with them may be grouped the extirpation of internal organs and tumours.

The third group deals with the removal *in toto* of a terminal portion of the body, be it to a greater or lesser extent. These operations are spoken of as *amputations*. A new indication is here added, namely, the provision of a definite form and skin-covering to the region from which the part has been removed. In consequence of the complete absence of the parts from one side of the wound, the steps to be taken in order to secure rapid union of the divided tissues are more complicated.

In the case of incisions, however deep, it is enough—antiseptic treatment taken for granted—to bring the divided tissues into apposition again, so that they occupy the same position as before the operation.

In excisions, and still more in amputations, tissues are brought into apposition which were not previously in contact.

In incisions, all that is required in order to bring the parts into accurate apposition, is the introduction of simple sutures throughout the entire depth and length of the wound surfaces. This is best done

by using a continuous suture and making alternately deep and superficial penetrations of the needle.

In excisions and amputations, it is not possible by means of sutures to bring the surfaces of the wound in contact in such a way that parts which belong to one another are brought into apposition.

We have omitted all directions concerning the choice and form of instruments, the holding of knives, the handling of forceps, scissors, saws, etc., and the different methods of suturing. It is our conviction, that no written instructions, however exact, are sufficient to educate a surgeon. These numerous details can be learnt only by looking on and by practising under skilful guidance in hospitals. The statements also, when and why vessels are to be tied, nerves to be stretched, joint-cavities to be exposed, joints to be resected and limbs to be amputated—in a word, the discussion of the indications for operations—must all be learnt clinically.

As we have written our text-book especially with the view of its being employed in operating on the living subject, we must say a word regarding the two chief conditions of every operative interference, namely, anæsthesia and antisepsis. It is no more justifiable to give a person pain during an operation than to endanger his life by the introduction of infective agents into the wound.

B. ANÆSTHESIA

The manner in which anæsthesia is carried out depends upon the nature of the operation. We shall deal only with those means of whose efficiency and mode of employment we are able to speak from personal observation and experience.

An ideal anæsthesia would be attained if we were able to render insensitive only those parts of the body which underlie the field of operation. We do possess means which fulfil this indication to a certain extent, but their action is only superficial and too temporary.

Local Anæsthetics

The two most important means of producing local anæsthesia are by the ether spray, and by the injection of cocaine. Both methods possess a different value, inasmuch as the former acts purely physically, the latter as a chemical poison, not only upon the sensory paths, but also, after absorption, upon other parts of the nervous system, whereby dangerous concomitant actions may arise.

In the case of *ether*, conduction along the sensory paths is abolished by means of cold. This method of anæsthesia is suitable for minor operations, which can be rapidly performed. Anæsthesia with ether can be maintained only for a comparatively short period, as it is liable to

produce necrosis of the skin if its action be prolonged, especially in the case of small growths, over which the skin is stretched (chondroma of the finger). Local anæsthesia with the ether spray is indicated when the most painful part of the operation consists in injury to the cutaneous structures, as in making a simple incision or tearing out a nail. In such cases it is one of the best means we possess. Its only drawback is the burning sensation produced during the thawing of the tissues. This after-pain is best combated by immersing the part in warm water.

Ethylchloride is now employed instead of ether, as it acts with much greater rapidity and certainty. It is evaporated simply by the warmth of the hand.

Cocaine, which is introduced into the tissues in the form of hydrochlorate, arrests conduction along the sensory nerves, and indeed also along the larger nerve trunks. Further, in the case of mucous membranes, it not only acts when injected into the tissues, but also when merely painted on the surface. Cocaine, however, has the disadvantage, compared with ether, that it is absorbed and can produce paralysis of distant nerve structures. It is employed, therefore, only under certain conditions. For injection, a 1 per cent solution is used; for painting on, a 10 per cent solution. The anæsthesia lasts only a few minutes. Experience has shown that a dose of $1\frac{1}{2}$ grains may give rise to unpleasant accidents. The minimum lethal dose is $7\frac{1}{2}$ grains. Several injections of a 1 per cent solution may be made without danger. Antiseptic precautions must be taken, 5 per cent of carbolic acid being added to the solution. The solution must be injected either into or immediately under the cutis at the place where the tissues are to be divided. In the intracutaneous administration the anæsthetic zone may be recognised by the small elevation which forms in the area of injection. Small operations, such as incisions, and the excision of small growths, can be performed without the slightest pain when cocaine is used.

General Anæsthesia

We have only possessed the knowledge of this boon since the middle of the fourth decade. It was by means of ether that general anæsthesia was first produced. A few years later, it was supplanted by chloroform. At the present moment it is not decided which of these two substances deserves the chief employment. We consider it desirable, therefore, to state our own views regarding what appears from our personal experience to be the method to be recommended in employing these two substances. The fact that competent surgeons are still to be found supporting quite opposite views proves that both means possess their claims according to the conditions present. The difference in the method of employing the two drugs is considerable. Both substances are

poisonous in large doses, but the poisonous dose of ether is much larger than that of chloroform. In both, just as with any other poison, the maximum dose must not be exceeded. The maximum dose of ether as compared with chloroform is about the same as that of quinine as compared with strychnine; and just as we employ quinine in much greater doses than morphine and strychnine, so also we can administer much larger quantities of ether than of chloroform. Herein lies the great advantage of ether.

In the case of morphine, as is well known, much more than the maximum dose may be given, provided it be distributed over a considerable time. In the same way, in an operation lasting five hours, a much larger quantity of chloroform or ether is given than dare be administered in a shorter time. But the danger of exceeding the maximum dose administered at a given time is considerably greater in the case of chloroform than in that of ether. Why not, therefore, put chloroform completely aside?

Ether has certain contra-indications. On account of its local irritation on the mucous membrane of the respiratory tract, it produces congestion, swelling, and increased secretion of mucus. Ether is contra-indicated, therefore, in all cases in which hyperæmia and catarrh of the respiratory tract are present, especially when associated with difficulty of breathing. We have, for example, seen acute bronchitis and very serious results follow prolonged ether anæsthesia in operations upon goître. The second argument against the universal employment of ether is that large quantities are required, and, therefore, if it be administered like chloroform in gradually increased doses, a much longer and more intense stage of excitement is produced. In order to avoid such an evil, ether must be administered in a large dose to start with. Anæsthesia is then very quickly produced, just as rapidly as by chloroform, or even more so. For this rapid method a mask large enough to cover the entire face is necessary, because the ether vapour should be inhaled rapidly and in a concentrated form.

A towel is generally thrown over the mask; and a ring of copper is adapted to the face of the patient in order to ensure the necessary exclusion of air. By this means it is possible to induce anæsthesia in from two to three minutes and thereby greatly to shorten the period of irritation. This rapid method, however, has the disadvantage of producing a certain degree of asphyxia, due to the exclusion of air; hence the feelings of anxiety, the cyanosis, and the difficult breathing which are experienced in many cases.

In the case of *chloroform*, it is not necessary to take precautions in order to introduce the drug rapidly and in a concentrated form; on the contrary, we must take care to provide for a sufficient supply of air. For years we have employed a mask, so constructed that a free space is left between its covering and the rim which rests upon the face (Fig. 1).

Anæsthesia may in this way be produced within at most ten minutes, without any disturbance of breathing or feeling of suffocation. This is one advantage of chloroform. Further, chloroform does not produce such an irritating action upon the mucous membranes as ether. Anæsthesia with chloroform, therefore, is quieter and more agreeable to the patient than ether. It is evident that when a drug is employed which is intended to destroy sensibility, and in many cases is required also to produce a paresis of the motor apparatus amounting to muscular flaccidity, special care must be taken that the motor parts of the organs of respiration and circulation are not also paralysed. The main point, from the moment that muscular relaxation begins to set in, is to *attend to the breathing* and to see that air is entering the larynx. This is done by pushing forwards the jaw, and along with it the root of the tongue. As soon as paralysis sets in, the tongue and jaw, when the patient is lying on the back in the usual way, fall

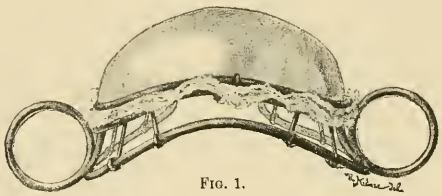

Fig. 1.

backward, and the epiglottis falls down like a valve upon the entrance to the larynx. We may readily satisfy ourselves of this while excising the jaw or tongue. The tongue, or the epiglottis itself, must be firmly drawn forward in order that the upper part of the epiglottis may be kept forward and upward during inspiration. The tongue is best carried forward by pushing forward the angles of the jaw with the head thrown back, so that the neck is stretched and the tongue thereby pushed upward at the same time. In this way the epiglottis is fixed by stretching the glosso-epiglottidean ligaments, and suffocation is prevented. The patient is to be carefully prepared for the anæsthesia in order to avoid any impediment to the breathing from other causes, as, for example, a full stomach and intestine, tight clothing, or an attitude which interferes with the expansion of the chest. The stomach must be empty at the beginning of the anæsthesia, or it may be emptied artificially, so that, should retching occur, food will not enter the larynx.

If care is taken to avoid any interference with the breathing, and if a mask be used which, by allowing a constant access of fresh air, prevents the inhalation of concentrated chloroform, and if the drug be gradually and uninterruptedly dropped on to the mask in just

sufficient quantity to produce anæsthesia, then no danger exists.[1] It does exist, however, when such a powerful action on the nervous system is required as to produce complete muscular flaccidity, and when the administration has to be prolonged. We are thus compelled to approach nearer and nearer the justifiable maximum dose, the signs of which we must be able to discern. They are as follows: falling back of the jaw and tongue with consequent obstructed breathing, indicating the beginning of the more powerful action. Thereafter this action is evinced principally by muscular flaccidity and by the slowing of the pulse. When the breathing becomes difficult, and the pulse irregular and of low tension, then the maximum dose is almost reached. These signs indicate a fall of the blood pressure, upon which may follow at any moment insufficient heart's action with consequent cardiac anæmia and collapse. In view of such possibilities, it is necessary to consider what position of the patient will favour the cerebral circulation. *The patient should not be chloroformed except with the upper part of the body horizontal and the lower extremities more elevated.* We arrange our operating table so that the limbs rest higher than the pelvis. It is obvious that the administration of the anæsthetic is to be at once discontinued as soon as the above dangerous symptoms make their appearance.

In all operations of long duration we advise that after complete anæsthesia has been produced by chloroform, *ether* should be substituted for it, provided there be no disease of the respiratory tract to contraindicate its use. The maximum dose of ether is so much greater than that of chloroform that the danger of *suddenly* reaching it is incomparably less. It is not difficult to maintain anæsthesia for hours with ether after it has once been thoroughly established by chloroform, and this *combined method* has the great advantage that it is not necessary to use the ether in a suffocating dose, but in small doses with the ordinary mask. It is well, however, for the sake of economy, to cover the mask with an impermeable substance, which will prevent too rapid evaporation of the ether.

We consider that ether is always indicated in the following conditions:—

1. Where extensive hæmorrhage is unavoidable.
2. Where anæmia and marked diminution in the blood pressure already exist.
3. In diseases of the heart muscle and impaired cardiac activity.
4. In all anæsthesias which have to be induced in emergency cases and without proper preparation; for example, in all out-patient departments, and by all dentists.

[1] We have not been able to make up our minds to employ the well-known apparatus of JUNKER and of KAPPELER, not only because the anæsthesia is more complicated, but because we find that by proper attention to the administration by the drop method the dose can be much better adapted to individual needs than by the use of a special inhaler.

On the other hand, we consider that the advocates of ether are not justified in the excess of zeal which would lead them to reproach those medical men, or even to accuse those of crime, who adhere to the use of chloroform. Chloroform is not only incomparably more agreeable to the patient, but is far less dangerous than ether where disturbances of the respiratory activity exist or are to be anticipated.

No general rule can be laid down as to when morphine is to be injected before the administration of the anæsthetic. With excitable patients, and with alcoholics, the previous injection of morphine helps to overcome the stage of excitement in a very comfortable manner. It has the advantage, at the same time, of prolonging the anæsthesia, and of producing a period of diminished sensibility to pain after the operation. But it must be borne in mind that certain individuals become rapidly faint, even with relatively small doses of morphine. We would advise, therefore, that not more than $\frac{1}{6}$ grain be injected, and this at least a quarter, or better, half an hour before the anæsthesia; and, moreover, that the subsequent anæsthesia, if produced by chloroform, should be more carefully watched than when ether is employed. After an injection of morphine a smaller dose of chloroform or ether serves to produce insensibility.

For producing anæsthesia of very short duration, *bromide of ethyl* is an excellent substance. Four or five drachms of this is poured on to an impermeable mask, which, as in the case of ether, is pressed over the mouth and nose, to exclude the air. Anæsthesia is produced in from thirty to sixty seconds, lasts from one to a few minutes, and does not produce the intense feeling of suffocation which accompanies the early stage of anæsthesia with ether. A further action must, however, not be attempted by means of this substance, either in the shape of a longer duration of anæsthesia, or of muscular relaxation; a second quantity must not be poured upon the mask, as its rapid action may produce a fall in the blood pressure, followed by sudden collapse. According to recent experiences, it is said that anæsthesia can be produced by such small doses as one to two drachms, if the drop method be employed, and that anæsthesia may be maintained as long as from fifteen to twenty minutes without fear. We are in the habit of substituting ether for bromide of ethyl the moment anæsthesia has been produced by the latter. No time must be lost, however, in changing the mask; otherwise the patient will come out, and the advantage of the initial bromide anæsthesia will be lost.

Bi-chloride of methylene is considered far less dangerous than either chloroform or ether by no less an authority than Sir SPENCER WELLS. But, as this drug has been used both by SPENCER WELLS and by JUNKER of Langegg only with JUNKER'S own apparatus, it is possible that the excellent results following its use may have been quite as much due to their large experience in administration as to the chemical con-

stitution of the drug. Indeed, our experience of it has been unfavourable, by reason of its inconstant chemical composition. It is expedient to give every patient a cup of tea with cognac, or a glass of Marsala, half an hour before the anæsthetic, in order to strengthen the heart's contractions and to raise the blood pressure. We have adopted this plan for nearly twenty years, and with the best results. By taking the curve of the blood pressure during the anæsthesia, we can demonstrate the influence which this stimulant exercises upon the condition of the pulse.

C. TREATMENT OF WOUNDS

The second indication which we must fulfil in every operation is *asepsis*. The patient must be protected against the harm and dangers of infection of the wound during and after the operation. All skill goes for nothing if this indispensable condition is not rigidly carried out.

It is not to be expected that this question can be exhaustively considered in a few pages. We shall here deal more especially with the principles of wound treatment, and how, by exclusion of infection from every operation wound, a rapid and undisturbed healing may be attained in a simple manner. If rapid healing of a wound be desired, it must be protected from infection, that is to say, from the deposit and development of substances which excite fermentation. We may look upon it as proved that primary union may occur in every wound which is placed under favourable mechanical conditions and excluded from the entrance of micro-organisms and their chemical products. Micro-organisms, however, are found in all fluids, and also upon solid objects which come in contact with the wound, and must therefore be destroyed.

LISTER, at the end of the sixth decade, enunciated the doctrine of the importance of the dust particles in the air, and of all objects in contact with it, and established the principle of antiseptic wound treatment, based upon the observations of PASTEUR on the origin and nature of the causes of putrefaction. LISTER first proved that putrefaction only occurred in wounds when dust-like particles were conveyed into them. If these harmful particles be excluded, no putrefaction occurs. It is by taking into account these simple facts that surgery has achieved such brilliant results at the hands, first of LISTER, and later of German surgeons (VOLKMANN, SCHEDE, THIERSCH, SOCIN); and hence the extraordinary importance of LISTER'S investigations and observations.

The second step made by LISTER was to prove that these dust particles are of an organic nature, as they are destroyed by such means as destroy organic substances generally. Lastly, LISTER proved that these substances are capable of development, and are therefore organisms.

Pasteur had already gone a step farther by showing that special forms of germs gave rise to special fermentations outside the human body. Billroth gave, in an excellent work, the results of his investigations concerning the causes of specific wound-infections. Koch, at the end of the seventh decade, by means of essential improvements in the methods of investigation, first proved that in wounds also, just as in the fluids in a flask, definite fermentations take place only under the influence of specific micro-organisms. A way was thus cleared for building up in a thoroughly accurate manner the doctrine of wound-infective diseases. Along this path further advances are being constantly made in the treatment of surgical and medical diseases.

In the meantime, however, we have reached the definite standpoint, that in treating wounds we must endeavour to exclude *all* micro-organisms, and we fortunately possess the means of fulfilling this obligation in a way which is practically sufficient.

Lister believed this indication to be in the main fulfilled by preventing *air-infection*, and the *spray* which he introduced for this purpose remained for a long time the sheet anchor of antiseptic wound treatment. Operator and patient were enveloped in a thick cloud of carbolic spray, which was intended to moisten the dust particles and render them harmless. The doctrine of air-infection was founded on the experiment of placing a putrescible fluid (urine) in a flask the neck of which was drawn out and bent downwards. Putrefaction of the fluid could in this way be prevented for years, but it at once occurred when the neck of the flask was broken off. More recently it has been shown that the spray is not only unnecessary, but is even harmful, as it stirs up the dust particles and causes them to travel with it to the wound without their having been destroyed or having their development arrested by contact with the carbolic acid.

It has been demonstrated that wound-infection may be avoided by the following precautions:— Operations should be undertaken in special rooms with smooth clean walls, from which the dust is to be removed by ventilation, by washing down the walls and furniture, and lastly, by allowing what remains to fall to the ground.

By aid of the beautiful experiments of Tyndall, Lister has shown that the air is completely freed from dust by the deposit of the heavier particles. When a sunbeam is allowed to traverse an empty closed flask it is seen as a bright ray, which disappears after the flask has stood for a while, in consequence of the light-reflecting particles having sunk to the bottom.

The doctrine of the relative harmlessness of *air-infection* must not be carried to the extent of declaring that it is just as safe to operate in a water-closet as in an operating theatre, provided only the instru-

ments and dressings be properly disinfected. It must, on the contrary, always be regarded as a great safeguard to operate in a room with clean smooth walls, so that neither from furniture, floor, nor especially from the ceiling, nor from any hanging lamp, can dust reach the wound.

Of far greater importance than air-infection is that form which is spoken of nowadays under the head of *contact infection*. It is this form upon which LISTER himself now lays special stress, and it is only since its thorough recognition that we have actually possessed a proper antisepsis. We refer to the infection of the wound by contact with fine and coarse particles of all kinds, with instruments, sponges, and swabs, with the surgeon's hands, and with irrigating fluids.

It is obvious that infectious materials thus brought into the wound adhere much more than in the case of air-infection. When the tissues of the wound are gripped with the hands or with instruments, the infective material is pressed into it in the same way as in vaccination.

The term *vaccination*—or *inoculation*—would be more appropriate here, because air-infection is after all merely by contact.

It is of even greater importance to distinguish yet another form of infection, namely, that which we propose to designate *implantation infection*.

Under this head should be placed, in the first instance, infection by materials used for ligatures and sutures, as well as by other porous foreign bodies or substances capable of imbibition. When micro-organisms are conveyed into the wound with a ligature, the wound is not only infected at the moment of contact or inoculation, but a permanent nidus of growth, in whose interior the germs find an appropriate place for development from the very first, is planted in the wound. The micro-organisms in the interior of such a foreign body (pieces of infected necrosed tissue act in the same way) are protected from the action of the adjacent living cells and juices, and derive their nourishment by imbibing the wound secretions; and the most favourable conditions are thereby established for a continuous and progressive infection,—conditions which do not altogether apply to the majority of vaccination infections. Implantation infection is thus the gravest form of all. The greatest attention must therefore be directed to the prevention of this mode of infection.

Do we, at the present time, possess the means of disinfecting, that is to say of sterilising, with certainty all those objects which come in contact with the wound, or which remain in it? This question is to be answered absolutely in the affirmative as far as swabs, dressings, ligatures and instruments are concerned. Our means of attaining this end have been so greatly simplified that it is no longer permissible for any medical man to transgress the law of absolute sterilisation of these

objects, nor to excuse neglect of aseptic precautions by reference to faulty external conditions.

How is complete asepsis to be attained? Quite a number of substances act as disinfectants. In the first rank stand carbolic acid, and the more reliable corrosive sublimate. Neither of those substances has an immediate action. Each requires some time to act, so that the dressings, etc., must be exposed for a considerable time to its influence. If the dressings are to be really sterilised, that is to say, if all the germs and spores which they contain are to be killed, we must estimate the period during which the antiseptic is allowed to act by the time it takes to destroy the most resistant spores. There are micro-organisms which withstand the action of sublimate for some hours, indeed for a whole day.[1] We must, therefore, allow our dressings, etc., to lie for several days in the lotion. This, however, injures many of the materials employed. Instruments cannot be placed in sublimate, neither can they be placed for days and weeks in the slowly-acting carbolic acid. Chemical disinfectants can be employed only for special substances, such as silk, which may remain a long time in sublimate without harm. It is a disadvantage of the chemical method that the dressings which come in contact with the patient's body can produce harmful effects by their local action as well as by absorption. The chemical method of disinfection is therefore a makeshift, and is only to be employed for certain materials and in certain conditions.[2]

The employment of dressings which have been dried after having been sterilised with solutions of carbolic and sublimate is to be completely rejected. The sterilisation by these means lasts only as long as the disinfectant is present in an active form, which has been definitely proved not to be the case when the dressings have dried. *Corpora non agunt nisi liquida.* Dry dressings which come ready prepared from the manufactory are not to be regarded as sterilised. We have no guarantee that infective germs do not attach themselves to such materials before or during their employment. Chemical sterilisation, therefore, is only certain when the dressings are taken directly from the disinfecting fluid and applied to the wound. The dressings, after having been taken out of the solutions, are put through a wringing machine and placed at once upon the wound.

As far as silk is concerned, this method of action has long been in use. It is exposed to chemical sterilisation by being wound on a reel, placed in the antiseptic fluid, and brought directly from this to the wound. This is permissible, as we are dealing with a small body, and the slight amount of carbolic or corrosive contained in it is of no im-

[1] Compare, among others, the experiments of VICQUERAT and ZIMMERMANN (under TAVEL'S directions), Dissertation, Berne, 1889.

[2] One may, with TAVEL, distinguish between disinfection and sterilisation, the former being understood to mean the destruction merely of the pathogenic germs. In the treatment of wounds, disinfection is sufficient.

portance as regards the local or general poisonous action. Using silk taken directly out of corrosive has the advantage that accidental infection is avoided at the time of its employment. In the case of dressings, however, the above-mentioned disadvantages of using them directly from the disinfecting fluid hold good.

Our best means of sterilising is by heat. A dry heat of 150°-180° C. will sterilise, with certainty, all our bandages, dressings, sutures and instruments. Moist heat is still more active. According to recent experiments, the most certain method of employing it as a sterilising agent is in the form of *compressed circulating steam.* By this method, a temperature of 130° C. destroys in a few minutes all micro-organisms and spores which are present in permeable objects. In our own clinique we employ a boiler with the steam at a pressure of three atmospheres and a temperature of 145° C.

Such methods of sterilisation, although thoroughly reliable, have no object unless the materials are conveyed directly from the steriliser to the wound. This method, however, is not always practicable, as instruments withstand steam worse than dry heat.

The best and simplest substitute for steam is to *boil the instruments and dressings,* a plan which has been adopted for years. The boiling must be continued for a longer time; but if the instruments have been boiled in water for half an hour, or better still, in 1 per cent soda solution, which prevents their rusting (SCHIMMELBUSCH), we may be quite certain that they are disinfected. This method has the great advantage that the apparatus required is always at hand, and that, moreover, it can be so placed that the instruments and dressings can be taken directly from the vessel by the surgeon's own hands. Dr. TAVEL has recently conducted experiments with salt and salt-soda solutions, which we first employed a long time ago for wounds, instead of water. He has found that they may be boiled a much shorter time in order to become completely sterilised. Dr. TAVEL has kindly informed us that a solution containing ·75 per cent of common salt and ·25 per cent of exsiccated carbonate of soda, and contaminated with the spores of anthrax and hay bacilli, is rendered completely sterile after a quarter of an hour's boiling, and remains so for a long time, fungi developing in it only after weeks.

Gauze, swabs and silk are completely sterilised after being boiled for half an hour in this solution. The salt-soda solution was made the subject of special investigation by TAVEL for the purpose of employing a fluid containing the same proportion of salt and alkali as the blood. We had long ago satisfied ourselves that the salt solution was absolutely non-irritating to the wound. According to TAVEL, the salt-soda solution is well borne in large doses as an intravenous injection, and does not irritate the peritoneum. A boiled salt-soda solution affords a completely sterile and non-irritating fluid for irrigating and cleansing

wounds. The objections which the advocates of the dry method put forward against the flushing system of treating wounds therefore fall to the ground. Gauze which has been boiled in salt-soda solution is the best material to place directly upon the wound.

For dressings and swabs we always employ gauze; for sutures and ligatures, invariably silk; and always glass drainage-tubes.

By comparatively simple precautions (steaming and boiling) we have reached an absolute certainty of disinfection in the preparation of all the non-living objects which come into contact with the wound. This is not, however, the case with our *hands*, or with the *skin and tissues of the patient*, and yet the purification of the hands and the skin is a *sine quâ non* in aseptic wound treatment. We can neither boil nor steam our hands. We must therefore employ chemical disinfectants, which, to be efficient, ought, as we have seen, to act for hours. As this is impossible, we must avail ourselves of a thorough preliminary mechanical cleansing. The day before the operation the skin of the patient is shaved over a large area, scrubbed with soap and very warm water, washed down with a 1 per cent solution of lysol, and protected from further coarser contamination by a dressing; before the operation the part is again washed down with a 1 : 1000 sublimate solution. The nails must first be scraped out, after which our hands, fingers, and especially our nails, are washed with soap and a brush under a stream of warm water for several minutes. It is obvious that sterilisation is not thus attained, because the ordinary water itself contains germs; but we render sterilisation possible by subsequently scrubbing with a brush for one to two minutes in a 1 : 1000, or still better, a 2 : 1000 acid sublimate solution. Bacteriological investigation (conducted by Dr. Tavel and Dr. Vicquerat) proves that in this way it is possible, as a rule, to sterilise our hands. For if, after this process of purification, we put our hands into nutrient gelatine, or inoculate it with scrapings from the nails, no bacteria develop. It is not indifferent, however, what the hands have been previously occupied with. This I have proved in a case of osteomyelitis in which I incised a large abscess and intentionally strongly infected myself. In spite of the above procedures for disinfection, a few colonies of staphylococci developed in the gelatine. For the removal of unclean fatty substances, washing with alcohol, according to Furbringer, is highly recommendable. For those surgeons who, on account of eczema or symptoms of poisoning, cannot use sublimate, thorough scrubbing in a 1 per cent warm solution of lysol is in our experience the best.

Dr. Zimmermann (under Dr. Tavel's directions) has made a series of investigations regarding the momentary infection of small pieces of flesh by definite micro-organisms, and has found that after immersion for five minutes in a 1 : 1000 acid sublimate solution, sterilisation does not take place with certainty; while it does occur if strips of

blotting-paper be substituted for the flesh. On no account should we make *post-mortems,* or dress infected wounds—although it has been declared permissible by competent surgeons—previous to performing an operation. We cannot lay too great stress on the fact that our hands, and those of all who take part in any way in the operation, must not have been contaminated with infectious substances.

It has been shown, by bacteriological investigation and by observations upon wound healing, that the hands can be disinfected if they have been previously kept clean and then cleansed immediately before the operation, by first very thoroughly scrubbing the nails and hands with soap and warm water aided by the use of a brush, and then again thoroughly bathing and scrubbing them with a disinfected brush in a warm sterilised salt or soda solution several times renewed. Dr. ZIMMERMANN has on several occasions demonstrated the complete absence of germs from our hands, especially from the epidermic scales taken from the side of and from under the nails. It is true that time must be spent over the washing, and all visible dirt must be thoroughly removed by prolonged scrubbing under a stream of warm water. The subsequent brushing and bathing in a 1 or 2 : 1000 sublimate solution increases the certainty of sterilisation, and is doubly necessary in all those cases where an abundance of warm and sterilised water is not at hand, and especially if the hands have been previously directly contaminated by pus or excretions. If all the micro-organisms are not thus killed, they are at any rate considerably weakened.

The fact remains, however, that disinfection of the hands and of the skin of the patient cannot be done with such absolute certainty as the sterilisation of instruments, dressings, etc. When we add to this the fact that accidental infection by inattention at the operation can never be excluded with certainty, then we shall do well to regard every operation wound, however carefully made, as possibly superficially and slightly infected. The more unfavourable the conditions, the more certainly will pathogenic germs reach the wound. The question therefore arises: *Can the infected tissues of the wound be sterilised?* and, if not, how are we to rectify the evil of slight or superficial infection, and how that of severer infection? As regards sterilisation of the wound, it may be shortly stated that if, as Dr. ZIMMERMANN has proved, it is not possible to sterilise with certainty pieces of flesh which have been momentarily contaminated with micro-organisms, by contact for five minutes with a 1 : 1000 sublimate solution, then there is no hope of doing it in the case of wounds. Nevertheless ZIMMERMANN obtained by such disinfection a very distinct difference in degree, inasmuch as far fewer colonies developed, and these took longer to appear, in consequence of having been weakened by the antiseptic. There is no need to be astonished, therefore, when we see that LISTER[1] himself takes up this standpoint in

[1] Address at the Berlin International Medical Congress, August 1890.

his antiseptic treatment of wounds, and washes out with a 1 : 500 solution of sublimate at the end of the operation. We have proved[1] that most excellent results may be obtained by aseptic procedures along with a single application of a 1 : 1000 solution of sublimate to the wound.

In using sublimate, too much absorption and too great a chemical injury to the tissues is guarded against by subsequently washing out the wound thoroughly with a ·75 per cent sterilised salt solution. This washing out with salt water has only one disadvantage, namely, that the antiseptic solution is washed out of the silk ligatures, where its presence is especially useful in preventing the subsequent growth of any organisms which may adhere to them, because we are not yet able to attain absolute asepsis. Blood coagula, etc., are thoroughly washed out of the wound with the salt solution, sublimate being employed only for purification when that is necessary, as soon as the vessels have been ligatured.

It has been proved that the large body cavities may be opened with most excellent results without washing out with an antiseptic, but the behaviour of the serous surfaces and cavities is not comparable to that of other injured tissues, such as connective tissue and muscle. For laparotomies we have limited ourselves for many years to antiseptic preparations preliminary to the operation, in other words, to what we are now accustomed to speak of as *aseptic wound treatment*. The wound is washed out merely with sterilised salt solution. But numerous investigations prove that the serous surfaces are very tolerant of infectious substances, which are comparatively easily digested by them, and thus rendered harmless, possibly aided by the action of the serous exudation, as long as the endothelium is intact (researches of Tavel and Walthard). The injured tissues in a wound, however, are not so favourably placed. Observations by Lanz go to show that in wounds which run a favourable course, micro-organisms develop much more frequently in the clots inside drainage-tubes than in the blood-stained exudation from the bottom of the wound.

We may hope also that a *limited number* of weakened micro-organisms meet with influences in the wound itself which exert an inhibitory or lethal action upon their development. We may look upon this disinfecting action of the exuding blood serum and living tissues as completing our aseptic wound treatment, which at present does not reach absolute certainty, and which in individual cases will probably never do so.

To render impossible an injurious development of the *few* organisms which, in spite of every care, may reach the wound, is our last but by no means our least important aid in attaining aseptic wound healing. To this end we have to take into account the fact that human tissue

[1] *Correspondenzblatt f. Schweizer Aerzte*, 1st Jan. 1888.

through which circulating blood and lymph are flowing is a bad soil for bacteria; blood[1] and serum stagnating in wounds form, on the other hand, an excellent soil. From this we arrive at an indication of the highest importance, namely, *the avoidance of any accumulation of fluids between the wound surfaces.* This is attained in two ways.

(1) *By the accurate apposition of the entire breadth of well-nourished wound surfaces.* Injurious chemical disinfectants and unnecessary mechanical action (tearing, squeezing, pressure) are to be avoided; good circulation is secured by means of properly selected incisions and by placing the part in a suitable position; and the wound surfaces are brought into accurate apposition throughout their whole extent by means of deep sutures and careful compression.

(2) *By conveying away the discharges* when complete closure of the wound is impossible. The best and surest means of doing this is by the *open wound treatment.*

The open wound treatment, combined with the use of antiseptics, is at the present moment *the only absolutely certain means of preventing all dangerous wound complications.*

As, however, healing by the open wound treatment is much slower, and as the wound requires to be continually attended to by the surgeon, it is suitable only in cases in which a wound is already infected, or is bound to become so in consequence of its communicating with the mouth, pharynx, intestine, etc. In these cases we consider it best to press into every corner of the wound a single or double layer of freshly prepared 10 per cent iodoform gauze, and then to stuff the remainder with 5 per cent carbolic or 1 per cent thymol gauze. The iodoform gauze is left in position as long as it adheres to the wound, but the carbolic gauze is changed daily or as soon as it is soaked with discharge, in certain cases as often as every half-hour.

The advantages of the open wound treatment without its attendant disadvantages may be gained by employing the method of *secondary suture,* which consists in closing the wound after having kept it completely open and antiseptically stuffed for twenty-four to forty-eight hours. We have made frequent use of this method. BERGMANN has strongly advocated it in a modified form: he uses a few primary stitches, and combines with these stuffing with iodoform gauze. SPRENGEL in Dresden, NUSSBAUM, HELFERICH, and STARCKE have also modified it.

We fully recognise that BERGMANN'S modification of our secondary suture is a great advantage in military surgery, where disinfection can only be imperfectly accomplished. We employ it regularly at the present time in the case of wounds which we cannot be certain of

[1] Proof of the importance of blood extravasations as a soil for the development of micro-organisms has been afforded in the clearest manner under Dr. TAVEL'S directions in his laboratory at our suggestion.

having disinfected; the wound is stuffed with iodoform gauze which is brought out at both ends, the main part being closed by deep sutures. In this way time is saved, and later, under more favourable circumstances, the wound can be made aseptic, or the danger of incomplete disinfection can be reduced to a minimum by producing granulations. Accurate secondary suturing with drainage can quite well be carried out after a week or a fortnight, as the skin cannot become everted or retracted. Wounded soldiers can thus be treated in hospitals at some distance from the field of battle. Simple open treatment produces, however, slow healing.

Complete primary suturing along with *drainage* is more convenient, but less certain. Drainage is always to be provided for by means of a glass tube, which is perforated at intervals with large holes and kept in a 1 : 1000 sublimate solution. The tube should never be brought out at the wound, but must be introduced through a separate small opening, thus allowing the main wound to be accurately closed by a continuous suture. The tube is, as a rule, kept in for twenty-four hours, seldom for forty-eight hours, and exceptionally for several days, as it has by that time removed any exudation resulting from the injury. The tube is left in still longer only when the wound shows signs of severe infection. In this case one would certainly prefer to have recourse to open wound treatment, after the employment of repeated disinfection.

The treatment of wounds by means of suturing and drainage is still that which is most frequently employed. Frequent endeavours have been made, however, to dispense entirely with drainage by using Landerer's dry wound treatment, Kuster's treatment under a dry scab, or Neuber's method of stuffing the wound with strips of gauze, and then applying uniform compression by means of the dressing, openings being left for drainage without the introduction of a tube. But in cases where the surfaces and edges of the wound cannot be brought together by sutures without leaving the so-called dead spaces (Mikulicz), even those who favour the above methods will be forced to admit that —serous cavities excepted—such wounds when drained heal most readily and uniformly. In all cases where one cannot ensure perfect asepsis, the introduction of a drainage-tube is an additional guarantee towards an uninterrupted healing even when the wound is not severely infected.

Intermediate, as it were, between the open treatment and drainage is Schede's *treatment under the moist blood clot.* Here the effused blood is employed to fill up the cavity in cases where it is not possible to bring the edges of the wound into immediate contact. The cavity is allowed to fill with blood, and its edges are only partly sutured, the remainder being covered with an impermeable material. Where neither primary nor secondary suture is possible, this method has a great

advantage over the simple open wound treatment, as it hastens the healing by favouring the cicatricial processes.

When we have the proper equipment at our disposal for carrying out the principles of true asepsis, that is to say, when we can prevent all intense and lasting infection of the wound, then the above-mentioned precautions suffice. When, however, we must operate under unfavourable surroundings, that is, when one is not able to prevent the introduction of a considerable number of micro-organisms, or when a wound is subsequently exposed to infection, as in operations on the mouth, pharynx, larynx, rectum, etc., or when the operation is within the reach of infectious foci, in fistulæ, or when ulcers must be removed, then a single sterilisation of the fresh wound does not suffice; we require an antiseptic method which will have a lasting action, namely, the *continuous antisepsis*. This can be accomplished in two ways:—

(1) *By the repeated application of the antiseptic substances enumerated above.* This procedure presupposes an open wound. Asepsis can be brought about after a short time, if the wound be left entirely open, and if carbolic or sublimate gauze dressings be kept applied, and renewed at first every two hours, and afterwards less frequently.

With this treatment we must expect some absorption and poisonous action of the antiseptic, which must therefore be carefully watched. As, however, we are not dealing with a single application of a *strong* disinfectant, but essentially only with an interference with the development of the micro-organisms, our object can be attained by the application and frequent renewal of warm antiseptic poultices made with *weak* solutions of carbolic ($\frac{1}{2}$ to 1 per cent), or sublimate (1 : 10,000), or with weaker antiseptics, as thymol (1 : 1000), salicylic acid (1 : 1000). To commence with, we employ as a rule freshly prepared gauze, soaked in 5 per cent carbolic and changed every three hours; later, warm moist poultices soaked in a 1·5 : 1000 salicylic solution. Far less certain than antiseptic poultices is the method of syringing out through a drainage-tube.

(2) The other way of attaining a continuous action consists in impregnating the wound surfaces with substances which render the tissues resistant against the penetrating action of the micro-organisms—*continuous antisepsis* in a narrower sense. To this category belong the *caustic substances* and *iodoform*. In mercurial, silver, zinc and bismuth salts, we possess substances which form albuminates with the albumen of the tissues, and these withstand the decomposing action of bacteria, because metal albuminates have a direct antiseptic action on micro-organisms. We employ for this purpose a 1 per cent emulsion of subnitrate of bismuth, as well as a 1 per cent emulsion of oxide of zinc. Our bismuth treatment gave results which were among the best obtained before the introduction of the perfected asepsis. But the above substances, especially bismuth, are decomposed by the

fermentation processes in the wound, and a sulphide of the metal is produced. The full action of these substances, therefore, can only be obtained by applying them to fresh wounds, that is to say, before the organisms have had time to produce a decomposition in the tissues. If decomposition has already given rise to necrosis of the tissue, then such powerful antiseptics as tincture of iodine, salicylic acid powder, or the thermo-cautery are necessary.

In contrast to the caustic substances stands *iodoform*. Mosetig-Moorhof has, by the introduction of this substance, opened up the way to a new form of wound treatment. Iodoform displays its action only when processes of fermentation have set in. The latter decompose the iodoform, the products of which combine with the ptomaines and tox albumens, and so hinder the further development of the micro-organisms (de Ruyter). On this account iodoform finds no place in the *aseptic* wound treatment. There is no justification for applying it to wounds which ought to heal aseptically; on the contrary, the wound may be actually infected by dusting it with iodoform powder. *It is, however, the most active of all drugs in combating decomposition which has just begun, or which is already advanced.* It is to be applied, therefore, to wounds which cannot be kept aseptic, that is to say, to wounds in which decomposition may be anticipated with certainty. De Ruyter comes to the conclusion that the plan of pouring into the wound Bergmann's ether-alcoholic solution (iodoform 10, ether 20, alcohol 80) is preferable to other modes of employing it. Iodoform has the disadvantage, however, of producing intense poisoning in certain individuals, acting especially on the nervous system; it must, therefore, be employed with great caution and in carefully measured doses.

In recapitulating the different methods of wound treatment, we must, in the first place, point out that it is the surgeon's duty in all cases to sterilise all instruments and dressings which come in contact with the wound, and to disinfect his hands and the skin of the patient. Instruments should be sterilised by boiling in a 1 per cent soda solution; dressings by boiling in a salt and soda solution (7·5 per cent and 2·5 per cent respectively). The skin is disinfected by scrubbing with a 1 per cent lysol solution, followed by scrubbing with a 1 : 1000 sublimate solution and the application of a gauze compress soaked in the same. Wounds may be brought under four categories as regards the treatment applicable to them:—

(1) Wounds which are severely infected, widely gaping wounds, wounds communicating with the alimentary canal, and old wounds: *open treatment with continuous antisepsis*, that is, antiseptic tampons and compresses frequently changed.

(2) Slightly infected wounds, and the majority of accidental wounds which are not placed at once under treatment: *iodoform stuffing with secondary suture.*

(3) Aseptic wounds made by the surgeon, in which the accumulation of blood and blood serum cannot be avoided with certainty: *primary suture with careful drainage.*

(4) Wounds made aseptically by surgeons, which can be brought together in their entire length and depth: *primary suture.*

D. DIRECTION OF SKIN-INCISIONS

In the days when patients could not be anæsthetised, and when the wound could not be protected from infection, it was a good principle to arrange the incisions so that they might be made as quickly and as limited as possible, and at the same time ensure a good outflow of the discharges by the action of gravity.

The latter indication at the present day can be completely fulfilled by making a small special incision through which the drainage-tube may be inserted. Still, one finds in certain text-books that the student is directed to make the smallest possible skin incision in cutting down to find an artery. Such a procedure is no longer legitimate. The true surgeon makes a free skin incision, but proceeds as carefully and sparingly as possible in making the deeper dissection. A large skin incision produces no additional injury worth mentioning as compared with a small one, because, when carefully sutured, it heals with equal rapidity and certainty; and further, the larger size of the resulting scar is of no significance, provided it runs in the proper direction. This brings us to that point which we have for years regarded as decisive in the arrangement of incisions.

According to the investigations of LANGER upon the planes of cleavage of the skin, the tension of the skin is very different in different directions, and two incisions at right angles to one another display a very different amount of retraction of the edges of the wound: the one gaping, whilst the edges of the other remain in contact without artificial aid. These facts are to be borne in mind in determining the direction of incisions, even although in individual cases other considerations come into play. For of still greater importance as regards the direction of the incision is the course of the vessels, and particularly of the large and small nerve branches. In making incisions in the face, for example, the direction of the branches of the facial nerve is to be taken into account. Fortunately, many of the nerves and vessels ramify in a direction corresponding to that in which the skin displays a greater tension, so that the line of incision adapted to the plane of cleavage also corresponds to the course of the important nerves and blood-vessels.

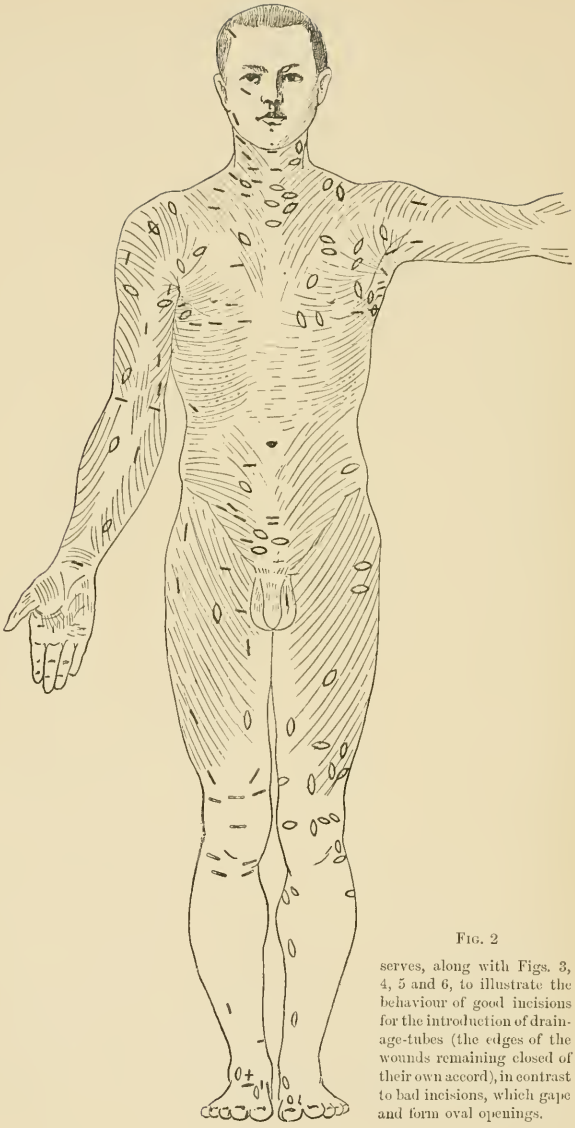

Fig. 2

serves, along with Figs. 3, 4, 5 and 6, to illustrate the behaviour of good incisions for the introduction of drainage-tubes (the edges of the wounds remaining closed of their own accord), in contrast to bad incisions, which gape and form oval openings.

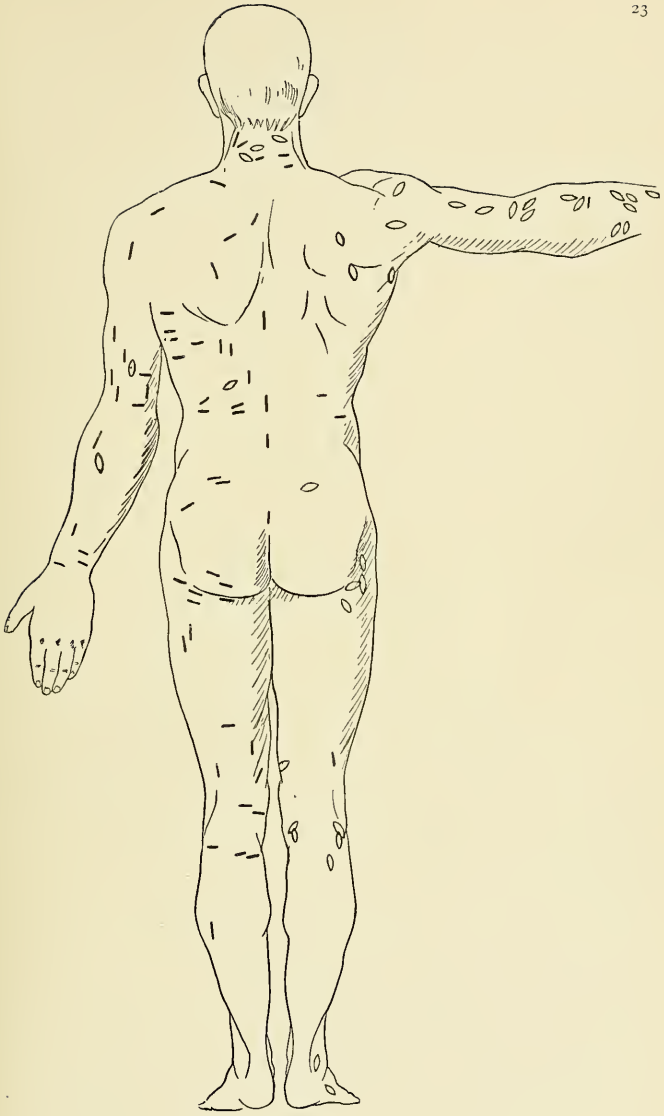

Fig. 3.

For years we have recorded upon a diagram our incisions which have not been sutured,[1] and have represented them according to whether they were gaping or closed at the second dressing, and for this purpose we have used the drainage openings which were made in addition to the sutured skin wounds. If the drainage-tube is removed after twenty-four hours and the sutures after forty-eight hours, an opportunity is afforded of observing clearly the behaviour of small unsutured skin wounds after every operation. We reproduce in the following diagrams the result of those records, and introduce at the same time LANGER'S lines for the direction of cleavage of the human skin. In Figs. 2, 3, 4, 5 and 6 those drainage openings which come together spontaneously after removing the tube are indicated by a simple line, whilst those which remain gaping are represented by a spindle-shaped figure. It will be seen from Fig. 2 how close the agreement is between good

FIG. 4.

FIG. 5.

FIG. 6.

lines of incision and LANGER'S lines of cleavage, as was indeed *a priori* to be expected.

Having once established this, we have preferred to make the longer incisions also more and more in the direction of the cleavage lines of the skin, and have convinced ourselves that the difference in the scar formation in incisions along or opposed to the cleavage lines is so important that it appears necessary to give the *normal incisions* for every region of the body. They indicate the cleavage lines of the skin for the corresponding region of the body, and are at the same time so placed that the course of important superficial nerves and vessels is taken into account. We have convinced ourselves that the scars resulting from the operations for goitre, which are here so frequent, become in the course of time after such normal incisions so fine that one has actually difficulty in recognising them, whilst scars resulting from incisions otherwise arranged often severely deform the neck by contraction and puckering.

[1] The accompanying figures and the great majority of the lines indicated thereon have been made by Dr. E. LARDY, now Chief Surgeon to the French Hospital in Constantinople.

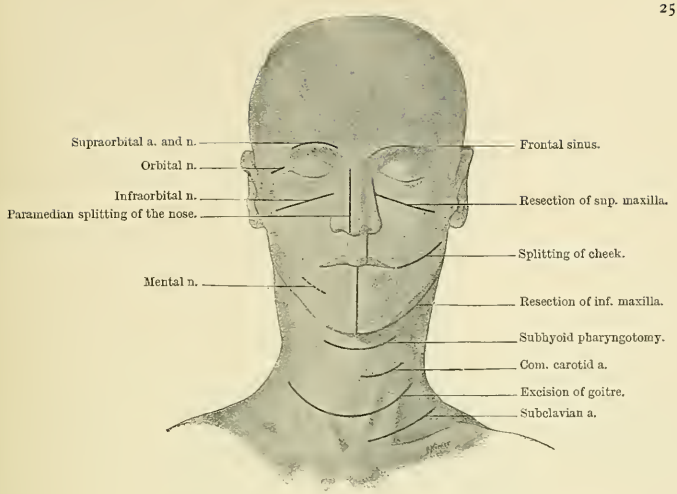
Supraorbital a. and n.
Orbital n.
Infraorbital n.
Paramedian splitting of the nose.
Mental n.
Frontal sinus.
Resection of sup. maxilla.
Splitting of cheek.
Resection of inf. maxilla.
Subhyoid pharyngotomy.
Com. carotid a.
Excision of goitre.
Subclavian a.

FIG. 7.

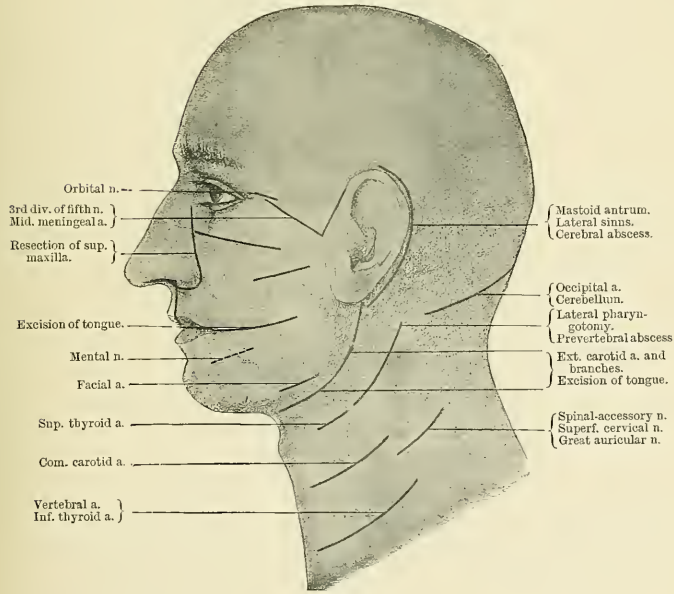
Orbital n.
3rd div. of fifth n.
Mid. meningeal a.
Resection of sup. maxilla.
Excision of tongue.
Mental n.
Facial a.
Sup. thyroid a.
Com. carotid a.
Vertebral a.
Inf. thyroid a.
Mastoid antrum.
Lateral sinus.
Cerebral abscess.
Occipital a.
Cerebellum.
Lateral pharyngotomy.
Prevertebral abscess.
Ext. carotid a. and branches.
Excision of tongue.
Spinal-accessory n.
Superf. cervical n.
Great auricular n.

FIG. 8.

We have, therefore, added schemes indicating our normal incisions (compare Figs. 7 to 15). The large incisions have been especially mapped out, such as those on the head, neck, trunk and articular

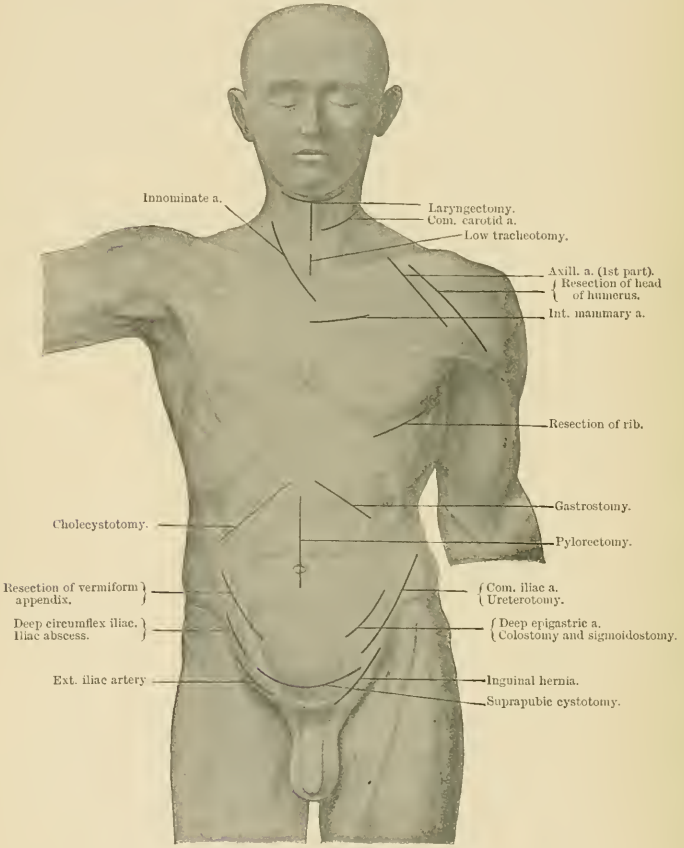

FIG. 9.

regions. For the remainder, especially the inter-articular portion of the extremities, we have, for the sake of simplicity, when dealing with smaller incisions (for ligaturing arteries and exposing nerves) retained the straight incisions in the longitudinal direction. A glance at

the figures shows that some of those longitudinal incisions likewise correspond with the lines of cleavage of the skin.

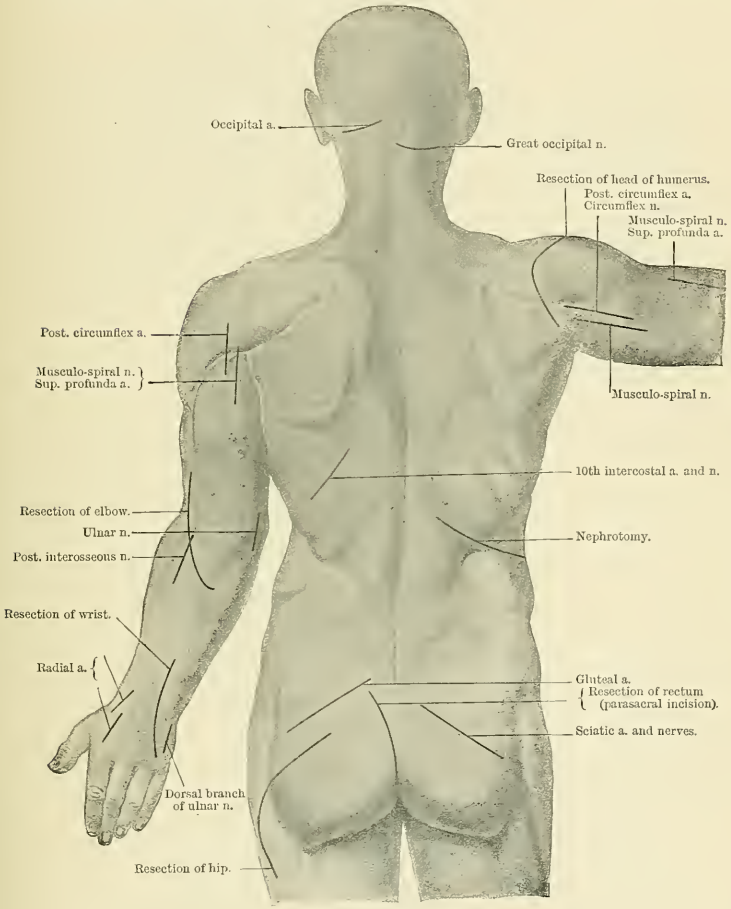

FIG. 10.

It need scarcely be mentioned that all longitudinal incisions placed in the middle line of the body, *i.e.* all incisions which correspond to a

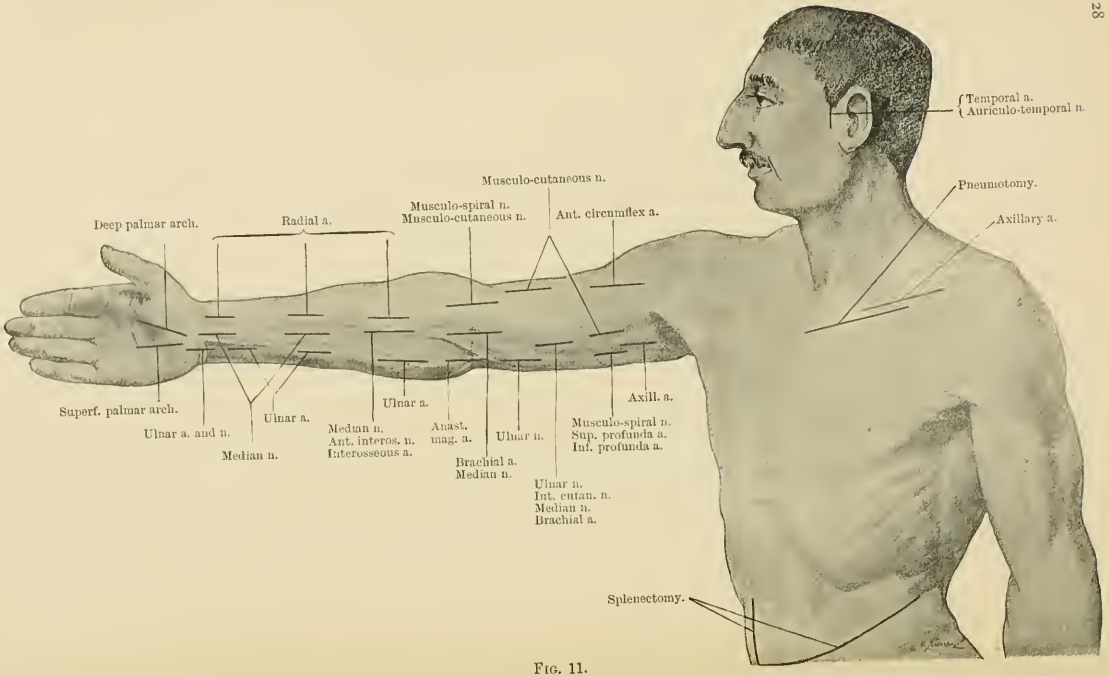
Temporal a.
Auriculo-temporal n.
Pneumotomy.
Axillary a.
Musculo-cutaneous n.
Musculo-spiral n.
Musculo-cutaneous n.
Ant. circumflex a.
Deep palmar arch.
Radial a.
Superf. palmar arch.
Ulnar a. and n.
Ulnar a.
Median n.
Median n.
Ant. interos. n.
Interosseous a.
Ulnar a.
Anast. mag. a.
Brachial a.
Median n.
Ulnar n.
Ulnar n.
Int. cutan. n.
Median n.
Brachial a.
Axill. a.
Musculo-spiral n.
Sup. profunda a.
Inf. profunda a.
Splenectomy.

FIG. 11.

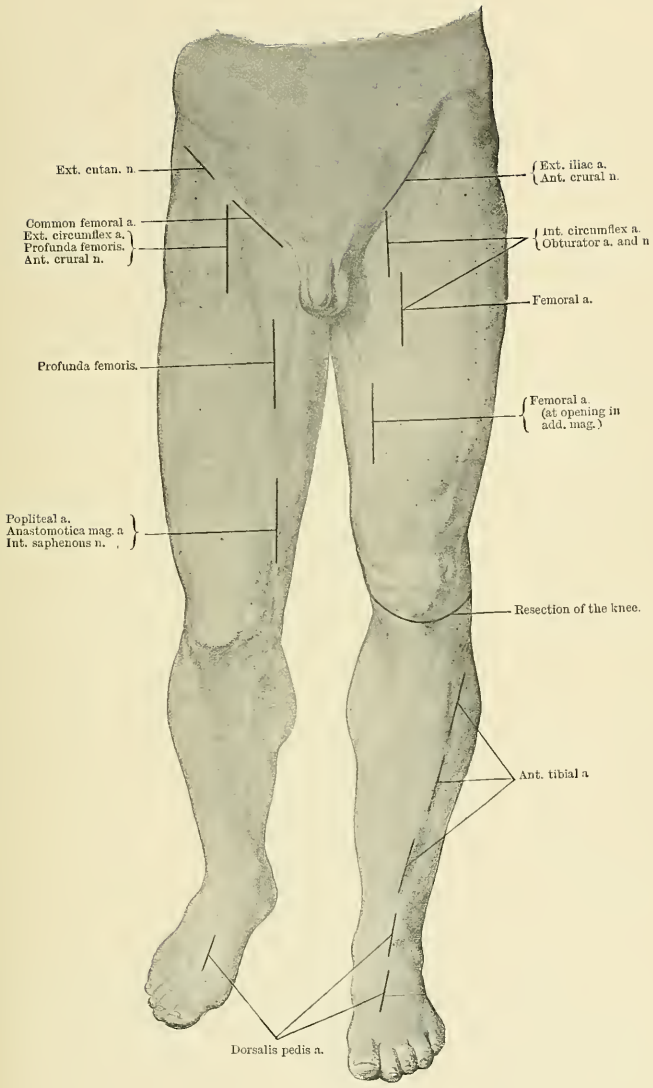
Ext. cutan. n.
Common femoral a.
Ext. circumflex a.
Profunda femoris.
Ant. crural n.
Profunda femoris.
Popliteal a.
Anastomotica mag. a
Int. saphenous n.
Ext. iliac a.
Ant. crural n.
Int. circumflex a.
Obturator a. and n
Femoral a.
Femoral a.
(at opening in
add. mag.)
Resection of the knee.
Ant. tibial a
Dorsalis pedis a.

FIG. 12.

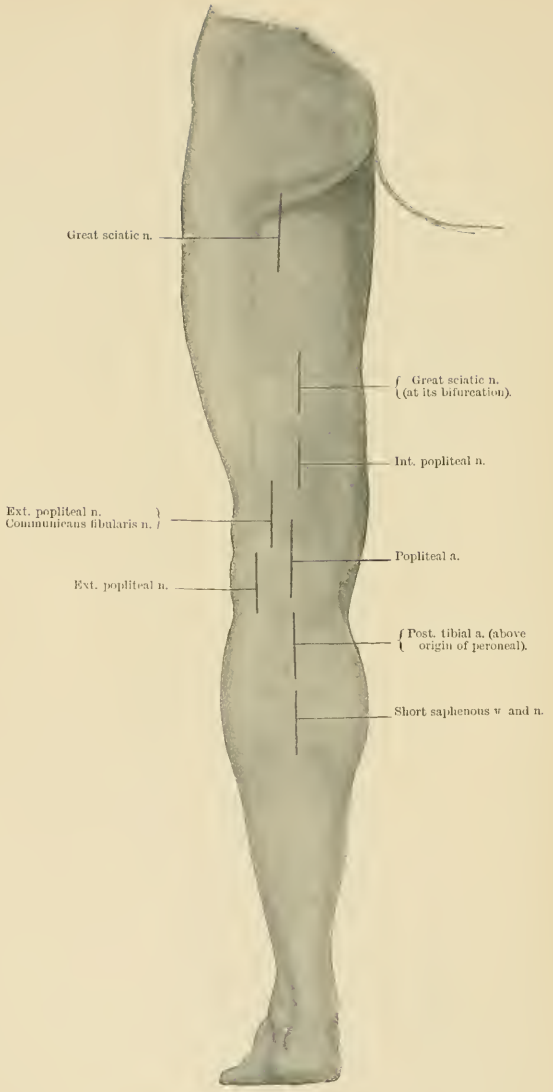
Great sciatic n.
Great sciatic n. (at its bifurcation).
Int. popliteal n.
Ext. popliteal n.
Communicans fibularis n.
Popliteal a.
Ext. popliteal n.
Post. tibial a. (above origin of peroneal).
Short saphenous v and n.

FIG. 13.

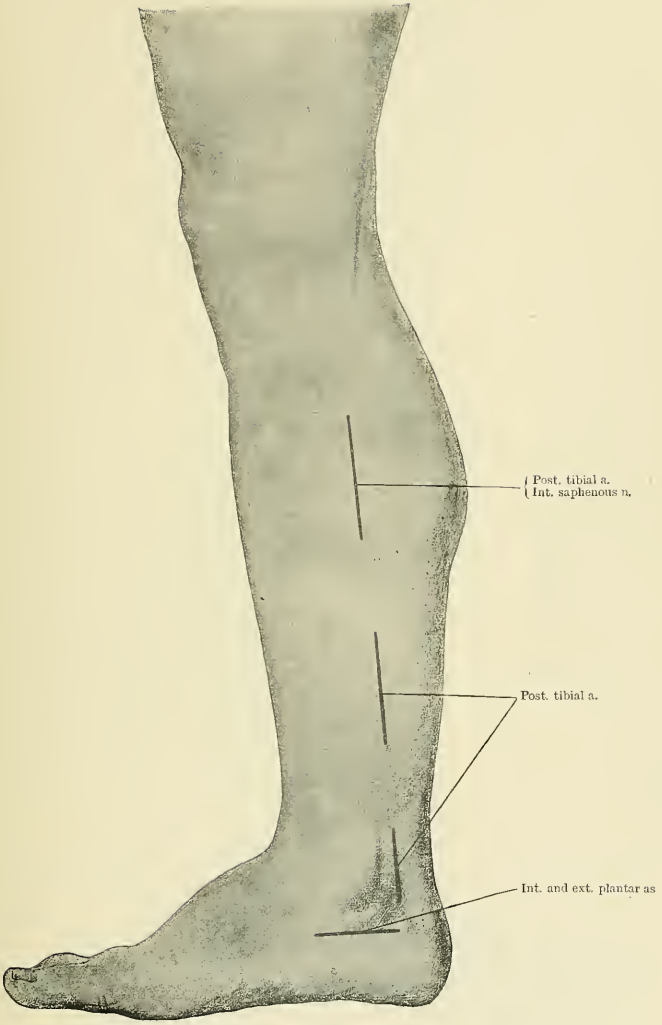
Post. tibial a.
Int. saphenous n.
Post. tibial a.
Int. and ext. plantar as

FIG. 14.

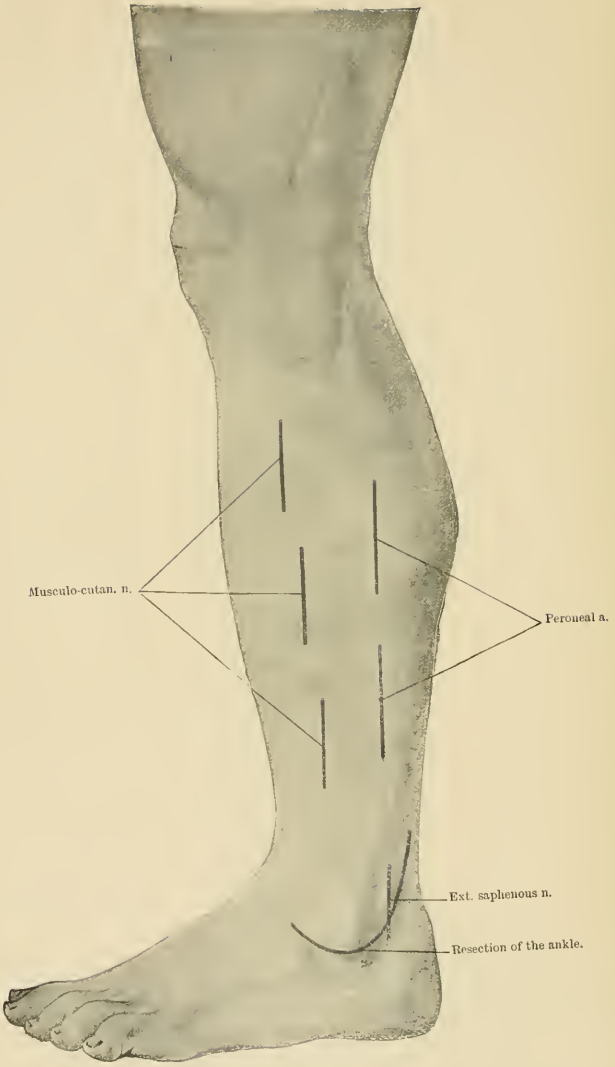
Musculo-cutan. n.
Peroneal a.
Ext. saphenous n.
Resection of the ankle.

Fig. 15.

vertical line from the scalp to the symphysis, along the perineum to the anus, and posteriorly upwards again to the scalp, are to be regarded as normal incisions.

In amputations a reunion of portions of the skin which correspond to one another is of course out of the question. Nevertheless, it is here also an advantage to adhere to some extent to the lines of cleavage of the skin in order to secure less retraction of the flaps.

It will be seen from the illustrations how well this indication is carried out by employing our oblique circular method of amputation.

PART II

SPECIAL OPERATIONS

E. CRANIUM

(a) Soft Parts

The scalp is characterised by its rich vascular supply, the vessels, however, being easily accessible to ligature, because they run in the skin and subcutaneous tissue, which is firmly united to the occipito-frontalis. The arteries lie loose in the scalp, the veins not to the same extent; therefore, the latter do not retract like the arteries. In hæmorrhage from the arteries, press upon the skin close to the edge of the wound and seize the vessels with artery forceps; if our toothed artery forceps do not succeed, then a ligature must be passed around the vessel by means of a curved needle.

The vessels which supply the scalp come from the frontal, temporal, and occipital regions. If, therefore, it is desirable in severe hæmorrhage from the scalp to apply a proximal ligature to the main vessels, we must turn to these three regions.

1. **Temporal Artery and Vein: Auriculo-Temporal Nerve** (Fig. 16). The pulsation of the temporal artery is felt at the upper border of the zygomatic arch $\frac{1}{2}$ cm. in front of the auricle; in hæmorrhage from its branches it may be either compressed or ligatured in this situation. A vertical incision is made 1 cm. in front of the helix. After dividing the skin the superficial layer of the temporal fascia appears. The artery crosses the zygoma, and is seen lying under the fascia at its upper border.

The position of the *temporal vein* is not constant; it is generally parallel to and behind the artery.

Of greater importance is the *auriculo-temporal*, a branch of the third division of the fifth nerve (Fig. 16); it is the sensory nerve for the ear and the temporal region. It winds round the temporal artery from below upwards and backwards, and then ascends parallel to its posterior

aspect. In exposing and stretching the nerve for neuralgia the artery is first identified, and the nerve then sought for nearer the auricle. Higher up the branches of the artery and nerve enter the substance of the scalp.

2. Supraorbital Artery : Supraorbital, Supratrochlear and Nasal

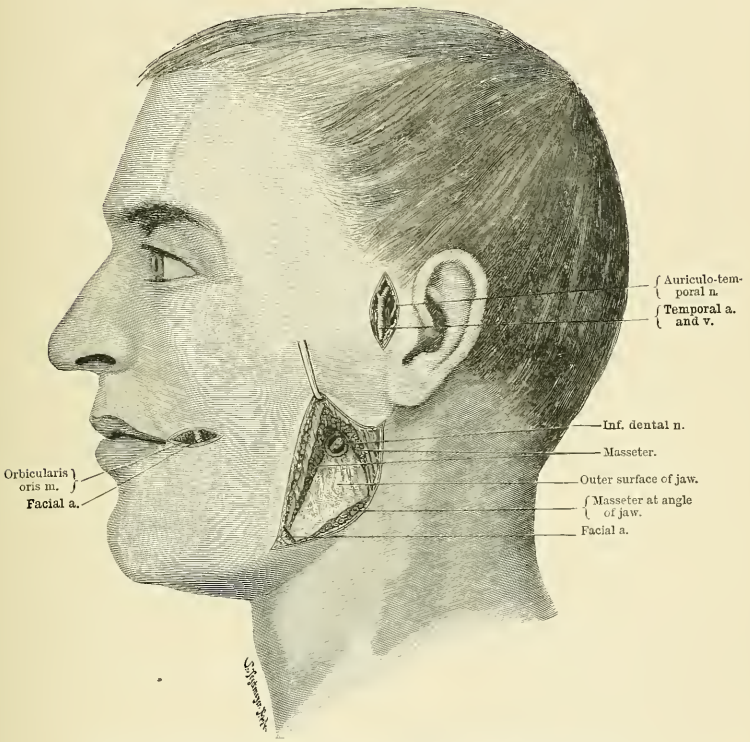

FIG. 16.—Ligature of the facial artery. Ligature of the temporal artery. Trephining the ascending ramus of the jaw to expose the inferior dental nerve.

Nerves (Fig. 17). The supraorbital is the principal artery of the forehead. It is smaller than the temporal artery, and leaves the orbit at the supraorbital notch, which serves as the guide in ligaturing the vessel. The course of the artery is vertically upwards through the fibres of the orbicularis and under the aponeurosis. After shaving off the eyebrow, a transverse incision is made over the supraorbital margin.

The same dissection is made to secure the *supraorbital nerve*, the supraorbital notch again serving as the guide. The nerve lies deeper than the artery, directly upon the periosteum; it is not an easy matter to divide the nerve without at the same time injuring the artery. The

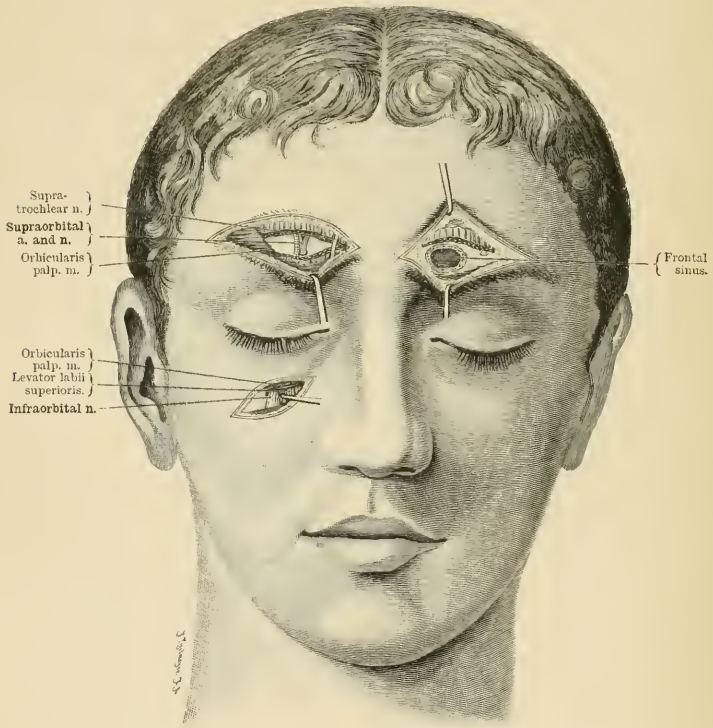

FIG. 17.—Ligature of the supraorbital artery. Exposure of the supraorbital nerve. Infraorbital nerve. Opening of the frontal sinus.

incision along the eyebrow has the advantage of avoiding the branches of the facial nerve. The frontal muscles and the orbicularis palpebrarum are supplied by the facial nerve, the branches of which enter from the external aspect and are not therefore injured by the transverse incision.

3. The Supratrochlear Nerve lies $1\frac{1}{2}$ to 2 cm. ($\frac{3}{4}$ in.) further inwards than the supraorbital, and runs vertically upwards from the inner angle

of the orbit; it is a much smaller nerve and lies more superficially in the orbicularis muscle. To expose it an incision is made along the inner half of the eyebrow.

4. The Nasal Nerve enters the cranial cavity at the upper and inner angle of the orbit, and leaves it again through the ethmoid bone, to be distributed upon the nasal septum and to aid in supplying the tip of the nose. It is quite easily seen about 2 cm. behind the inner extremity of the supraorbital margin, and here the aneurism needle may be passed round it.

The eyebrow incision is prolonged somewhat downwards over the root of the nose (branches of the angular artery and vein ligatured), and the periosteum divided and gradually separated backwards at the upper and inner part of the orbital cavity until the nerve, which runs transversely towards the anterior ethmoidal foramen, is seen to be detached from the orbital roof. The ethmoidal branch of the ophthalmic artery is torn in the process; the bleeding is arrested by plugging.

5. Occipital Artery: Great and Small Occipital Nerves (Fig. 18). The occipital is the largest artery of the scalp; it appears at the inner border of the splenius muscle midway between the external occipital protuberance and the highest point of the mastoid process; here it pierces the strong fascia and ascends over the occiput under the aponeurosis. The artery is ligatured where it pierces the fascia. A transverse incision is made from the posterior part of the tip of the mastoid process towards the occipital protuberance as far as the insertion of the trapezius muscle. The skin is here very thick. After dividing the fascia the posterior edge of the sterno-mastoid muscle is exposed, the small occipital nerve which accompanies it being avoided (Fig. 18). The fibres of the splenius muscle passing obliquely forwards and upwards appear under the sterno-mastoid. On dividing the splenius, in the same direction as the skin incision, the artery is exposed, lying at first upon the occipital attachment of the superior oblique muscle and afterwards upon the complexus.

The artery may be ligatured at the *inner border of the splenius* as it ascends to the skin of the occiput, under the fascia, in the angle between the posterior border of the sterno-mastoid and the anterior edge of the trapezius. Here the artery is joined by the great occipital nerve, which passes upwards and outwards.

The artery may also be ligatured at its *origin* by an incision the same as that for ligature of the external carotid. The occipital vein is not always found lying close to the artery.

6. The Great Occipital Nerve (posterior division of second cervical) becomes superficial at the outer border of the trapezius after piercing the complexus muscle. The nerve is found internal to the occipital artery, both structures converging towards one another.

If, for neuralgia, one wishes to find and stretch the nerve *nearer its origin*, the incision must be made deeper (Fig. 18). A transverse incision is carried outwards from the middle line opposite the projecting bifid spine of the axis. At the outer angle of the incision the posterior edge of the sterno-mastoid muscle and the small occipital nerve appear. The comparatively thin trapezius is divided, as also are the fibres of the strong splenius capitis, which ascend obliquely upwards and outwards

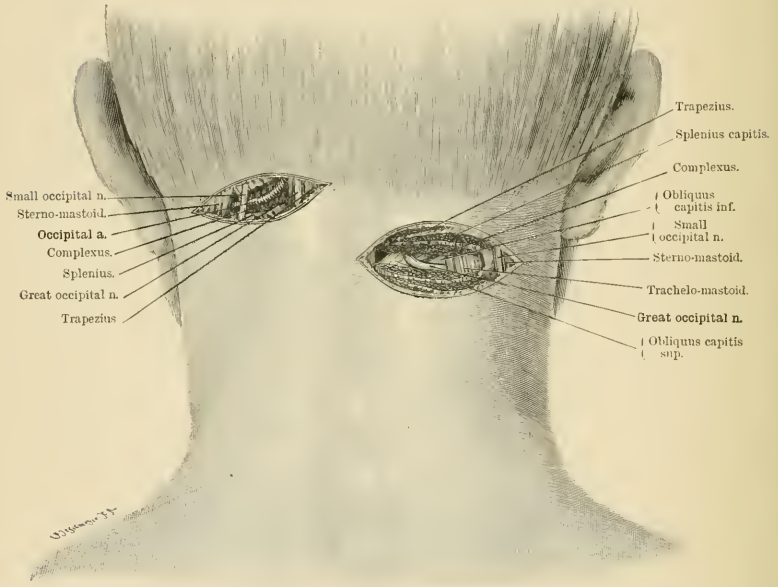

FIG. 18.—Ligature of the occipital artery and exposure of the small occipital nerve. Great occipital nerve.

underneath it; and, lastly, the vertical fibres of the powerful complexus muscle having been divided, the deeply placed fibres of the superior and inferior oblique muscles are exposed. The large nerve curves round the lower border of the latter muscle and passes upwards and inwards across its surface. Here the nerve gives off motor branches to the muscles at the nape of the neck, and is thereafter purely sensory. The trachelo-mastoid muscle extending obliquely downwards at the outer border of the complexus can be spared.

The *small occipital nerve* (anterior division of the third cervical) appears at the posterior border of the sterno-mastoid muscle, along which it extends under the fascia to the occiput. It ramifies external to the great occipital. For its exposure see occipital artery.

(b) Relations of the Cerebral Convolutions to the Skull

Physiological experiments supplemented by the experience of surgeons have definitely established that certain cortical areas of the brain represent foci for definite functions of a motor, sensory, and intellectual nature, and the result is that surgeons are now called upon to expose accurately definite circumscribed areas of the cerebral cortex in various paralytic and irritative lesions.

Various methods have been employed for furnishing guides to the relation of the brain surface to the skull, that is to say, to points upon it which are accessible to palpation and inspection. Only methods, however, which can be employed rapidly, and upon heads of different shapes and sizes, are of practical value.

The method by percentage measurements, introduced by Dr. MÜLLER, is one of the most accurate for always reaching the same point. It consists in drawing from two main lines others, which are subdivided in a special manner. The relations of the points thus obtained to the subjacent areas of the brain have been established from a large number of observations. Ours is an analogous method; for which we employ an instrument constructed for us by Dr. SCHENK, instrument maker, Bern. It consists of two flexible strips of steel (Fig. 19), which can be fitted on to any head by means of an elastic band carried round its horizontal circumference. The strips are divided into centimetres and millimetres, so that the different lines may be divided into percentage subdivisions. The instrument is so placed that the elastic band, which passes round the equatorial line, corresponds, anteriorly at its upper edge (point *A*) to the crista glabellæ, which connects the superciliary eminences a thumb's breadth above the root of the nose; posteriorly, it passes over the lowest point of the external occipital protuberance (point *B*). Laterally, the band passes above the upper attachment of the auricle. One of the steel strips passes along the mesial line from the glabella to the occipital protuberance (sagittal meridian). Connected with this sagittal strip is a second one, which is so arranged that it can cross it at any point and at any angle. It is graduated away from the point of crossing.

Two oblique meridians (Figs. 19 and 21), an anterior *CGHJ*, and a posterior *CSTV*, have been drawn forwards and backwards at an angle of 60° to the sagittal meridian from its mid-point *C*. A third line is drawn which is somewhat more complicated; for its construction *AB* is divided into thirds at the points *D* and *E*, and then *CB* is halved at

the point *F*. The movable steel strip is now slid upon the sagittal strip to a point *X* (midway between *EF*), and being kept in contact with

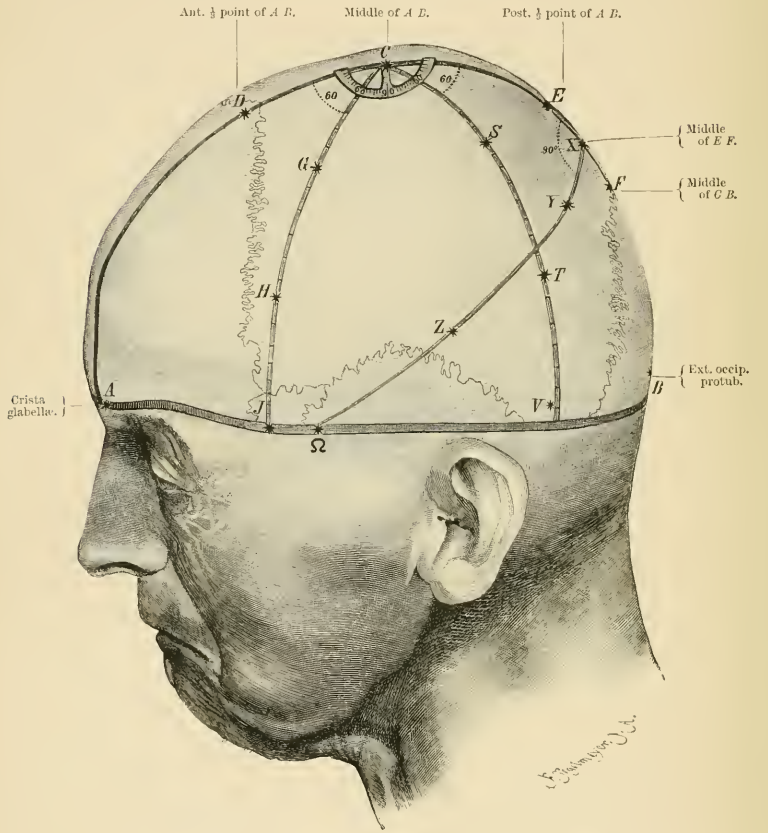

FIG. 19 shows how the fixed points are determined upon the shaved head.

$AC = CB = \frac{1}{2}\ AB.$
$AD = DE = EB = \frac{1}{3}\ AB.$
$CF = FB = \frac{1}{2}\ CB.$

$EX = XF.$
$CG = GH = HJ = \frac{1}{3}\ CJ.$
$CS = ST = TV = \frac{1}{3}\ CV.$

the surface of the head, the oblique line in question ($XYZ\Omega$) is drawn downwards and forwards along it to the equatorial line, which it

meets about 1 cm. behind the anterior oblique meridian. Lastly, the two oblique meridians and the oblique line are each trisected, and thus a sufficient number of fixed points are obtained for localisation upon the surface of the brain.

We have, on a large number of brains, established what parts on the

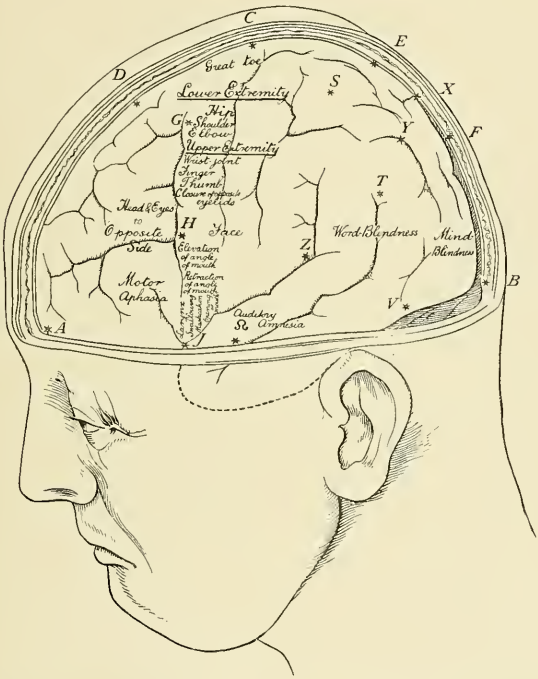

FIG. 20.—Relation of the fixed points to the cerebral convolutions. The centres have been mapped in according to HORSLEY.

surface of the brain correspond to the above points on the surface of the head, and we have satisfied ourselves that those foci which may require to be exposed in the living subject can be located with precision. To save a tedious description, we have indicated in the drawings of the exposed brain (Figs. 20 and 22) the points corresponding to the surface landmarks, which have been perforated to allow of the injection of a drop of an aniline solution into the subjacent brain.

We append the following description to the illustrations (Figs. 19 to 22):—The equatorial line corresponds to the greatest horizontal circumference of the brain; the point *A* coincides with the anterior poles of the frontal lobes, whilst *B* is slightly (nearly 1 cm.) below the posterior poles of the occipital lobes. Laterally the equatorial line crosses the temporo-sphenoidal lobe. The point *J*, where the anterior oblique meridian meets the equatorial line, corresponds to the pterion (junction of frontal sphenoid, temporal and parietal bones) and to the bifurcation of the fissure of Sylvius, and likewise therefore to the notch between the frontal and temporo-sphenoidal lobes.

The point *V*, where the posterior oblique meridian meets the equatorial line, strikes the boundary between the temporo-sphenoidal and occipital lobes, and lies 1 cm. below the edge separating the outer from the under surface of the hemisphere. The upper pole (mid-point *C*) of the sagittal meridian lies over the precentral convolution in front of the sulcus of Rolando.

The upper third point (*G*) and the lower third point (*H*) of the anterior oblique meridian correspond respectively to the origins of the superior and inferior frontal sulci from the precentral sulcus.

The upper third point (*S*) of the posterior oblique meridian lies over the superior parietal lobule, just above the intraparietal sulcus and the supramarginal convolution. The lower third point (*T*) of this meridian corresponds to the posterior extremity of the parallel sulcus, and lies, therefore, below the angular gyrus.

The oblique line, where it springs from the sagittal meridian at *N*, corresponds to about the apex of the lambdoid suture, and to the parieto-occipital fissure. The upper third point (*Y*) of the oblique line lies over the angular gyrus, whilst the lower third point (*Z*) is over the hinder end of the horizontal limb of the Sylvian fissure. The point Ω, where the oblique line meets the horizontal meridian, corresponds to the anterior end of the parallel sulcus.

The anterior third point (*D*) of the sagittal meridian corresponds to the bregma (junction of coronal and sagittal sutures), and lies over the posterior portion of the first frontal convolution. The above points are manifestly sufficient to locate all the motor and sensory centres at present known.

(c) Cortical Centres of the Brain

We shall now give a short account—based on the classical researches of Horsley upon the cerebral centres in apes—of the known centres in the human brain, and of the places where the skull is to be opened when they are the seat of lesions. Professor Horsley, on our applying

to him, kindly sent us a drawing made by himself, which we have here used. In Figs. 20 and 22 we have indicated upon the surface of the brain the points determined by our method after removing the skull-cap and dura. A comparison of the figures shows that the known centres of the cerebral cortex may readily be grouped around the fixed points obtained by our method.

For the lower extremity the trephine is to be placed directly external to *C*, near the middle line for its distal part (great toe), and farther away, or behind *G*, for its proximal part (hip). According to what has been ascertained in certain apes, the hip centre lies half a trephine circle farther forwards, while the centre for the toes, especially that for the great toe, is farther back.

The centres for the upper extremity lie under a trephine circle placed immediately behind *G* to *H*, the shoulder and elbow being at the upper part, and the wrist, fingers, and thumb at the lower part. According to other experiments, we should pass in half a trephine circle farther backwards for the fingers and thumb. A trephine opening made still farther downwards, behind the line *GH*, and somewhat above the latter point, hits upon the focus for the ocular region of the face, that is, for closing the lids on the opposite side. Behind the upper third of the line *HJ* is the centre for elevation of the angle of the mouth; on the opposite side, behind the middle third, that for retraction of the angle of the mouth; and lastly, behind the lower third, above and behind *J*, is the centre for the larynx and pharynx, for the movements of swallowing and mastication, and of opening the month obliquely backwards and upwards, the last-named centre lying a good finger-breadth above Ω.

Extending upwards and downwards in front of *H* is the centre for the movement of the head (and, according to my own clinical observation, the eyes also) towards the opposite side. In front of the middle of the line *HJ* is the centre, a lesion of which produces motor aphasia (this area was not drawn in by Horsley). Below the posterior half of the line *ZΩ* is the area for auditory amnesia (word-deafness), below the point *T* that for visual aphasia (word-blindness), and above *BV* the seat of the visual intellection (mind-blindness), a lesion of which produces psychical blindness. Were it in future possible to expose, and it may be to excise, the centres lying on the median surface of the hemispheres, their position would be found to be as follows:—

Those for the muscles of the trunk behind the point *D*, in the anterior half of the line *CD*; the primary visual centre (a lesion of which produces hemianopsia) in front of the upper half of the line *XB* (Fig. 23).

Lastly, we must mention the place where, in our opinion, the *lateral ventricle* may be punctured with the greatest certainty and with least injury. It may be tapped from above, from the front, or from the side.

If the puncture be made from the bottom of the posterior half of the parallel sulcus, the posterior horn will be reached after penetrating only 1 cm. of brain tissue. In a case of tubercular meningitis, we placed the trephine behind and above the ear, in front of the posterior extremity of the temporal crest (Figs. 24 and 25), and exposed the area

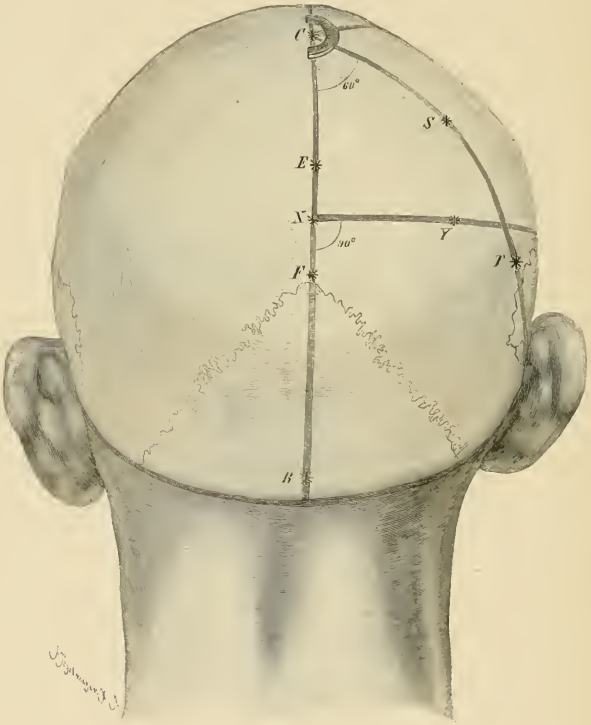

Fig. 21.—(For references see Fig. 19.)

below *Z*, from which the lateral ventricle was tapped exactly at its floor, and just behind the posterior extremity of the caudate nucleus. But the drainage, after the ventricle was once completely emptied, did not continue to act, in consequence, we think, of the coming together of the walls of the ventricle from the weight of brain substance above.

In another analogous case drainage from above answered quite well, and had a very beneficial effect. We consider, therefore, that it is better to get at the ventricle from above than from below, although this involves traversing the brain substance for a depth of 4 to 5 cm. As, however, a puncture directly from above injures the centres for the lower

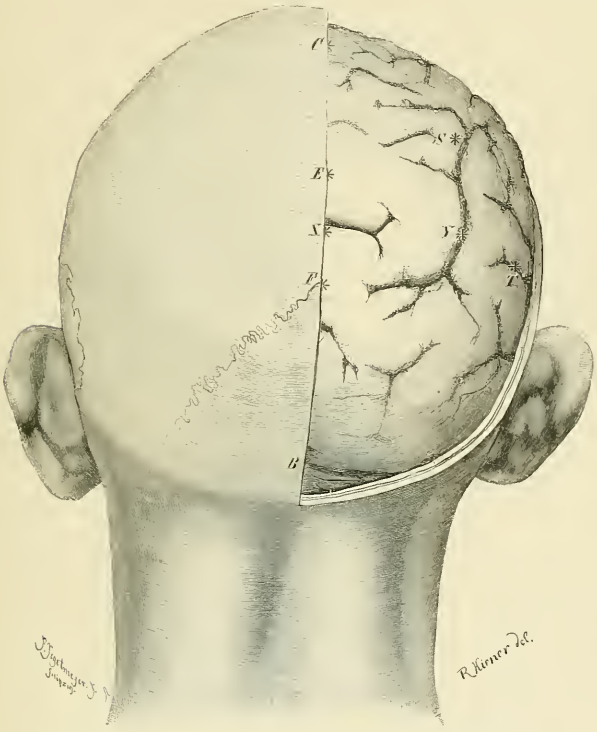

FIG. 22 shows the relation of the fixed points to the convolutions.

extremity, it is advisable to make the puncture beyond reach of the motor areas at a point farther forward, external to the point *D*, and in front of the point *G*. The puncture is about $2\frac{1}{2}$ to 3 cms. (1 to $1\frac{1}{4}$ in.) from the middle line, and 3 cms. ($1\frac{1}{4}$ in.) in front of the precentral sulcus, and is best made through the sulcus between the superior and middle frontal convolutions. The instrument is directed downwards and backwards.

In this way serious injury to the cerebral cortex is avoided. We have at present a case of cerebral tumour under treatment in which a drainage-tube introduced in this way drew off abundant cerebro-spinal fluid. A trephine having a diameter of at least 4 cms. ($1\frac{1}{2}$ in.) is employed, as, according to HORSLEY, a good-sized opening should be made.

After removing the bone, a preliminary puncture is made with a PRAVAZ'S syringe having a canula at least 6 cms. ($2\frac{1}{2}$ in.) long. The dura is divided only to a very limited extent, in order that the drainage-tube may be somewhat firmly held by the edges of the opening. One of our artery forceps is introduced into the brain in the direction previously ascertained by the canula, and the canal sufficiently enlarged

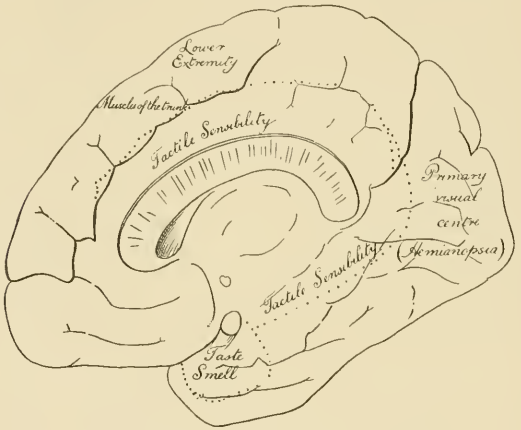

FIG. 23.—Centres upon the inner surface of the hemisphere, according to HORSLEY.

to admit of the introduction of the drain, which should as usual be a glass one, and 6 cms. long. It is introduced through a small opening in the scalp, so that the main wound may be completely closed; moreover, the small opening in the scalp assists in retaining the tube in a definite direction. At first blood flows, soon, however, to be replaced by clear cerebro-spinal fluid, often in considerable quantity, necessitating a frequent change of dressing.

(d) Trephining

After ascertaining how and where the centres in the brain are to be found, how and where special nerves and vessels are to be avoided, or the latter ligatured, as a rule it will be found that in

trephining it is best to make the incision upwards from the horizontal circumference towards the centre of the vertex, because the vessels and nerves take this course. If a vertical incision does not suffice, then a flap is made having its base below and its rounded apex above. The crucial incision formerly so much employed produces greater injury. The incision is made firmly with a resection knife down to the bone, and the flap, together with the periosteum, is readily turned back by the aid of a periosteum detacher; it is only along the sutures that the periosteum adheres so firmly as to necessitate the use of the knife. The bone is removed by means of the ordinary hand trephine, by the trepan, or, more recently, by means of small circular saws. Instead of the trephine, the hammer and chisel may be employed, provided there is no reason to fear that its use will be attended with concussion. The area to be removed is first outlined with the chisel, and as soon as the piece of bone becomes movable it is wrenched out with the elevator, the edges which are left being smoothed off with a LUER'S gouge forceps. The chief point to attend to is to avoid injuring the meningeal vessels.

The temporary resection of the skull (WAGNER) by means of an Ω incision, and the chiselling out of the bone while preserving at the same time its attachment to the soft parts, in order that it may unite on being replaced, appears to be indicated when large openings are required, or when the skull is opened for diagnostic purposes. One does not always succeed, however, in lifting out the bone entire and connected throughout with the loosely adhering pericranium.

7. Trephining the Longitudinal and Lateral Sinuses. Trephining over the sinuses of the dura is only done when it is the intention of the surgeon to open or expose them.

The superior longitudinal sinus lies to the right of the mesial plane.

8. Trephining to expose the Lateral Sinus (Figs. 24 and 25) is a much more important operation. Thrombosis and suppuration of the sinus occur most frequently as the result of the spread of inflammation from the middle ear. The place for trephining is determined by finding the most prominent part of the base of the mastoid process which projects backwards from the attachment of the auricle. A finger-breadth higher, and passing obliquely upwards and backwards, is the crest-like termination of the temporal line. The lateral sinus lies upon the inner side of the mastoid, between the temple crest and the above-mentioned projection, and is continued a little farther downwards along the mastoid process. An incision is carried down to the bone opposite the posterior edge of the auricle (auricular incision, Fig. 24), some fibres of the temporal muscle being divided at its upper part. The periosteum is separated forwards, and the sterno-mastoid muscle which appears below is detached with the knife. The posterior edge of the wound is drawn backwards.

After chiselling away the bone, the wall of the sinus is exposed. In opening the mastoid cells—a much more frequent operation (page 52) the lateral sinus is to be avoided.

9. Trephining for Ligature of the Middle Meningeal Artery. The

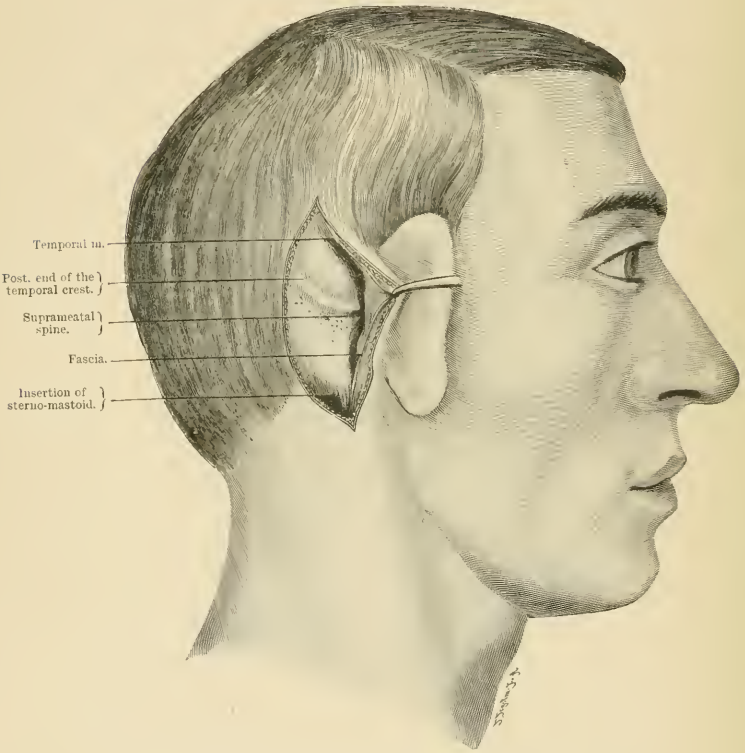

FIG. 24.—Post-auricular incision for opening the mastoid antrum, the lateral sinus, and the descending cornu of the lateral ventricle.

middle meningeal artery supplies the cerebral membranes. The point which is usually selected for ligaturing it is situated two finger-breadths above the zygomatic arch, and a thumb's breadth behind the external angular process of the frontal bone (VOGT); but this point strikes only the anterior branch of the artery.[1] In order to expose the posterior

[1] MERKEL'S *Anatomy*, p. 65.

branch at the same time, the trephine must be applied immediately above the middle of the zygomatic arch (below our points J and Ω). In addition to the integuments, and the periosteum, some vertical fibres of the temporal muscle are divided. A vertical incision extending

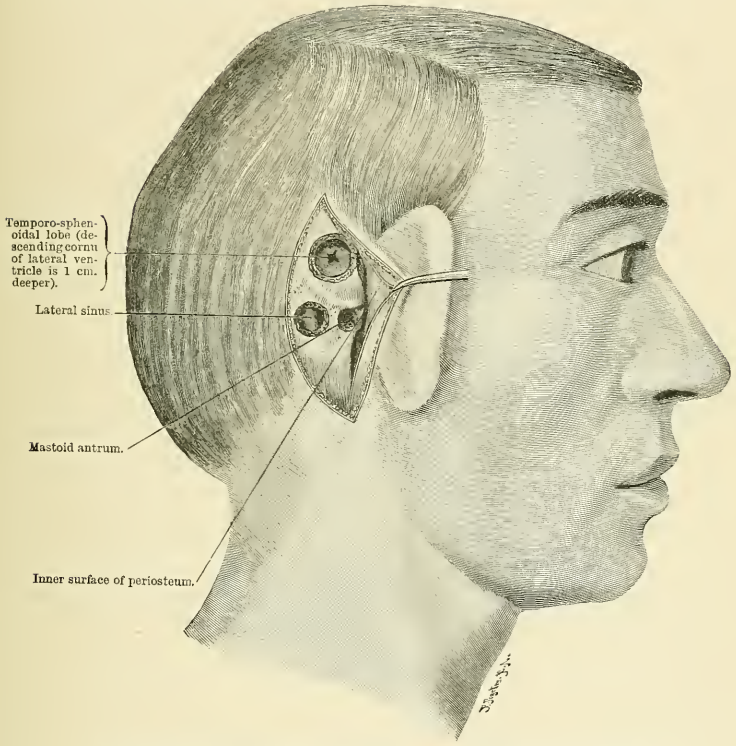

FIG. 25.—Opening the mastoid antrum and the lateral sinus. Exposure of the temporo-sphenoidal lobe and puncture of the descending horn of the lateral ventricle.

below the zygomatic arch cannot be made, on account of the branches of the facial nerve. We employ an incision (Fig. 26) extending obliquely from the external angular process of the frontal bone downwards and backwards to the posterior extremity of the zygomatic arch, and from thence upwards and backwards to above the auricle. After having divided the skin and the strong temporal fascia, and ligatured the superficial

temporal artery, the incision is carried down to the bone at the posterior border of the temporal muscle, and this muscle along with the periosteum is detached forwards. In this way hæmorrhage from the deep temporal arteries is avoided, and the anterior part of the squamous temporal, under which the meningeal arteries lie, is exposed. The bone is here very thin.

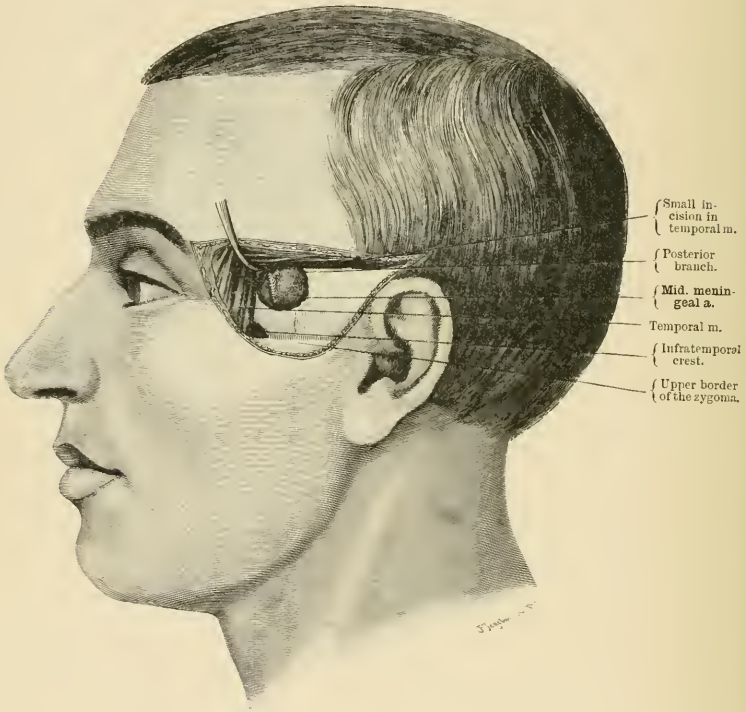

Fig. 26.—Ligature of the middle meningeal artery.

There are still two areas of the skull which as a rule are to be avoided in trephining, but which may nevertheless require to be exposed intentionally. We refer to the situation of the frontal sinus, and of the mastoid antrum and its cells. Collections of pus in these cavities furnish the most important indication for opening them.

10. Trephining the Frontal Sinus (Fig. 27). After shaving off

the eyebrow, an arched incision is carried down to the bone along the supraorbital margin as far as the middle line. The upper edge of the wound along with the separated periosteum is drawn well upwards. The supratrochlear and supraorbital nerves and the accompanying arteries are

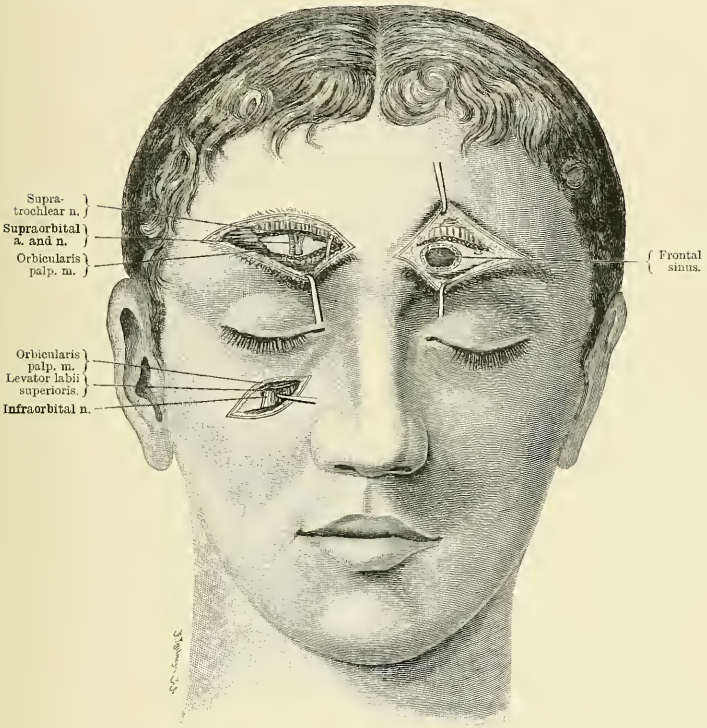

FIG. 27.—Ligature of the supraorbital artery. Exposure of the supraorbital nerve. Infraorbital nerve. Opening of the frontal sinus.

divided, but the branches of the facial nerve to the occipito-frontalis, corrugator, and orbicularis muscles, which are of greater importance, are avoided. It is seldom necessary to make a second incision passing obliquely upwards towards the middle line. The sinus is opened with a chisel at the inner end of the supraciliary eminence. The anterior wall contains diploe, and is richly supplied with blood, so that one must be

prepared for bleeding. The posterior wall consists only of the vitrea. Beneath the anterior wall is the mucous membrane, thin when healthy, but often markedly thickened by suppuration. After dividing the mucous membrane, a probe may be passed downwards and backwards from the sinus into the nose under the anterior end of the middle turbinal, and, after forcibly dilating the canal, drainage is established by the introduction of a tube.

11. Trephining the Mastoid Process (Figs. 24 and 25). The surgeon is often called upon to open the bony cavities of the mastoid process. The communication of the tympanic cavity with the mastoid antrum and cells enables infective material readily to reach them, to become stagnant, and subsequently, by invading the thin bony walls, to reach the pericranium and the dura. In connection with the former an acute inflammatory swelling may develop behind the auricle, while a pachymeningitis may be associated with the latter. As a result, temporo-sphenoidal abscess, cerebellar abscess, basal meningitis, or phlebitis of the lateral sinus may be produced, according to the seat of extension of the otitis into the mastoid ostitis. In opening the mastoid process attention is first directed to the mastoid antrum, as being the cavity in direct communication with the tympanum, and therefore first invaded from it. Drainage of pus from the tympanum can be provided for merely by incising the tympanic membrane. In the case of the mastoid antrum, however, the opening into which lies higher than its floor, an artificial channel of exit must be established from the outside, and this is even more necessary as regards the mastoid cells, which lie still deeper.

In opening the mastoid cavities we must avoid unnecessarily opening the cranial cavity or the lateral sinus, or injuring the aqueduct of Fallopius and the facial nerve.

In order to reach the mastoid antrum by the most direct route and without injuring adjacent structures, it is best to make a free incision exposing the entire process. The incision is made parallel to the posterior edge of the auricle, and the periosteum is separated and turned well forwards so as to lay bare the mastoid. The *suprameatal spine*, situated at the upper and back part of the bony meatus, serves as the guide for the application of the gouge, which should be directed inwards vertically to the surface. The cavity of the antrum lies about 1·5 cm. ($\frac{5}{8}$ in.) from the surface. The mastoid cells lie below and behind the antrum; they are reached by gouging away the overlying bony layers down to the apex of the process. By passing too far forwards, or by working too deeply within the bony meatus, the canal for the facial nerve (*aqueduct of Fallopius*) is reached; by deviating backwards, the *lateral sinus* is struck; and by going too far upwards the *cranial cavity* is opened and the posterior part of the temporo-sphenoidal lobe of the brain exposed above the base of the petrous temporal—a situation from which we have already seen the lowest part of the lateral

ventricle may be opened. When suppuration has spread in either of these three directions, then one makes one's way there intentionally.

12. Trephining the Cerebellum. A transverse incision is carried down to the bone along the superior curved line of the occipital bone. The trephine is placed below the curved line and behind the mastoid process. The insertions of the splenius capitis and the posterior part of the sterno-mastoid are detached downwards along with the periosteum. The small occipital nerve is divided, but the great occipital nerve and the occipital artery are freed, and drawn down with the soft parts.

F. THE FACE

The skin of the face is less dense than that of the scalp, but, like it, is extremely vascular. We must be prepared, therefore, for spurting vessels even in skin incisions. Most of the vessels lie under the cutis. As regards the *direction of incisions*, the general rules which have been laid down are to be applied. Above all, the facial nerve has to be avoided in operating upon the face, and incisions must be chosen which run parallel to its branches, as any injury to the nerve results in disfigurement. It is much less serious to cut through a branch of an artery than to injure a nerve, no matter how small. Accordingly the incisions should radiate from a centre which corresponds to the entrance of the nerve into the parotid. By this means lesions which interfere with expression are guarded against. Some of the vessels, however, will be divided transversely, but STENSON'S duct, which runs parallel to the normal incisions, is avoided. The muscles must be partly divided. Muscular incisions are, as a rule, avoided; one keeps rather to the septa between them, because infected muscular wounds heal badly. Since the introduction of asepsis, however, the latter consideration no longer comes into question. Rapid union of muscle along with complete restoration of its function can now be obtained, provided the nerves of supply have not been injured. We have constantly to refer to this point in our text-book: rather cut through a powerful muscle (as, for example, the rectus abdominis) and bring about a tendinous intersection, than cause its paralysis and atrophy by injuring the nerve which supplies it.

13. Ligature of the Facial Artery (Fig. 28). This is the chief artery of the face. The place for ligaturing it can be very definitely determined, as it ascends over the lower border of the jaw just at the anterior border of the masseter muscle; it is accompanied by the facial vein, which, however, is not so constant in its course. An incision is made parallel to the margin of the jaw opposite the anterior border of the masseter. After dividing the skin, platysma, and fascia, the artery is exposed, and is then to be freed from its surroundings. The

supramaxillary branch of the facial nerve, which courses along the margin of the jaw, is to be carefully avoided.

14. Operations on the Nose and Nasal Cavities. Access to the nasal cavities through the anterior nares is not made use of in attacking nasal affections of a more serious nature, such, for example, as deeply invading inflammations and malignant growths. In such affections the

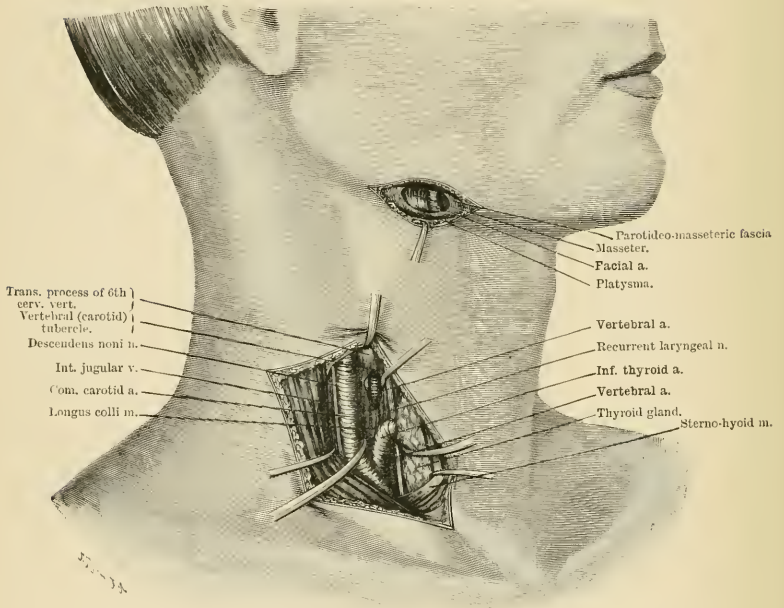

FIG. 28.—Ligature of the facial artery. Ligature of the inferior thyroid and vertebral arteries.

interior of the nose must be made thoroughly accessible both to palpation and to inspection.

The simplest way of doing this is by *splitting the nasal septum*, a method recommended by us. The blades of a strong pair of scissors are introduced, one into each nostril, as far back as possible, and the cartilaginous septum is divided. Blood spurts from the small arteries of the septum. The finger can then be introduced into the nose, the walls of which can be manipulated. In ozæna this procedure

suffices to clear up the cause, and especially to discover and remove circumscribed areas of diseased bone. The introduction of a couple of sutures enables us to bring about union so exact that practically no visible result of the interference is left.

If a good view of the interior of the nose is desired, freer access must be got. This is attained by *splitting the nose close to the middle line* (Fig. 7). The incision is not made exactly in the middle line, on account of the furrow which runs along the anterior edge of the septal cartilage of the nose; a cicatrix along this furrow would, by contraction, render it visible, and so produce distinct disfigurement. By dividing the lateral nasal cartilage and the nasal bone a little to one side of the middle line, a cicatrix is obtained which is scarcely visible. If, in addition to splitting the nasal bone, the nasal process of the superior maxilla be divided from below upwards, just in front of the lachrymal sac, and if the root of the nasal bone be chiselled across, then the corresponding side of the nose may be thrown upwards, and a good view of the entire vertical extent of the corresponding cavity is obtained.

If the disease is situated upon the outer wall of the nose and extends to the upper jaw, then it is better to *split the nose laterally.* An incision is made along the groove around the ala nasi and extending upwards, either as far only as the summit of the osseous anterior nares, the detached side of the nose being thrown upwards and inwards, or the division may be extended upwards along the nasal process of the upper jaw, and transversely through the root of the nasal bone. In this way very good access is got to the anterior part of the nose, so that tubercular ulcerations can be readily exposed to thorough local treatment. The method, however, has the disadvantage of throwing out of action some of the muscular fibres, namely, the pyramidalis nasi and the levator alæ nasi. As, however, the muscular incisions generally heal by first intention, and the nerve supply remains partly intact, no noteworthy interference with the play of the features results. The nasal branches of the facial artery are divided, but its angular termination is avoided at the upper part of the wound. By careful suturing the scar becomes almost invisible.

If it is necessary to see farther back into the nose than is possible by the above methods, then a partial osteoplastic resection of the upper jaw may be made (see page 71), whereby the inner, the anterior, and a portion of the upper wall of the antrum are turned outwards, and a view far back into the posterior nares is obtained.

Exposure of the Base of the Skull or the Roof of the Nose

Another method of gaining free access to the back part of the nasal cavity is by *splitting the hard and the soft palate.* After making

a mesial incision down to the bone, the muco-periosteal soft parts are separated and turned aside, and the hard palate, together with a portion of the vomer, is chiselled out (GUSSENBAUER). The posterior part of the nasal cavities and the nasopharynx are thus exposed, so that tumours (fibromata and fibro-sarcomata) springing from the base of the skull can be removed under exact control. In a case we recently operated on for recurrent sarcoma of the base of the skull and back part of the roof of the nose, complete healing was obtained with a minimum of subsequent disfigurement by the following method—namely, splitting of the upper lip up to the nostril, division of the mucous membrane on both sides along its line of reflection from the gums to the cheeks, and then chiselling across both upper jaws transversely outwards and backwards from the anterior nares. The wound having been plugged, the hard palate is next chiselled through along the middle line, and the soft palate split mesially. Both upper jaws (without the pterygoid processes) are now drawn well apart with sharp hooks, the mucous membrane of the floor of the nose divided, the vomer drawn aside, and the projecting turbinals excised. The tumour was thus completely exposed.

In such an extensive operation, in addition to prophylactic arrest of hæmorrhage by ligaturing both external carotids, we advise that the anæsthetic be not given with the head dependent, otherwise the venous hæmorrhage will be too free. A small dose (not more than $\frac{1}{6}$ grain) of morphia should be injected half an hour before the operation, and a light degree of anæsthesia is to be maintained with a minimum amount of chloroform administered through a tracheotomy wound.

For *opening the sphenoidal sinuses*, the above-mentioned plan of GUSSENBAUER appears to be the most suitable. These sinuses open into the nose opposite the posterior extremities of the superior turbinals. They can be opened by perforating the roof of the nose with a sharp spoon at the upper border of the posterior nares, between the posterior edge of the middle turbinal and the ala of the vomer.

After opening the nasal cavity, access is got to the *nasal duct* under the anterior end of the inferior turbinated bone $1\frac{1}{2}$ cm. ($\frac{5}{8}$ in.) behind the edge of the osseous anterior nares. The *antrum of Highmore* is reached by passing outwards under the middle turbinal $2\frac{1}{2}$ cm. (1 in.) behind the above bony edge; higher up, under the same turbinated bone, a probe may be passed into the duct of the *frontal sinus*. The direction of the canal, as well as that of the nasal duct, is about parallel to the lateral wall of the osseous anterior nares.

Lastly, the nasal cavities may be exposed without injury to the facial nerve *by an incision from the sublabial mucous aspect*. Without injuring the face, the mucous membrane is divided along its line of reflection from the gums to the upper lip, and the cartilaginous part of the nose is separated from its attachment to the osseous anterior

nares so that the soft parts (nose and cheeks) can be turned upwards as far as the eyes (Rouge); if the septum be now divided, then the entire nasal cavities become accessible from the front. This operation has the advantage of leaving no disfigurement, but it is attended with considerable hæmorrhage.

To freely open the antrum of Highmore.

One method of gaining access to the antrum has already been referred to in opening the nasal cavity. Even when a large opening is necessary, one endeavours to avoid an external incision by entering from the mucous membrane either of the mouth or of the nose. The antrum is frequently the seat of suppuration following long-continued inflammation, so that we are often called upon to make a permanent opening into it. The *canine fossa* is the place from which it is most readily reached in order to allow of its being freely opened and thoroughly investigated. Having everted the upper lip, the mucous membrane and periosteum are divided along its line of reflection above the roots of the bicuspid and first molar teeth, and the periosteum is detached with an elevator upwards and outwards till just below the infraorbital foramen; the thin bony wall is then chiselled through with a gouge. The strong buttress on either side of the canine fossa, formed by the nasal process and the ridge of the malar bone, is left undisturbed.

A second method is to bore upwards with a perforator *through the alveolus* of an absent or extracted tooth, preferably the first or second molar.

A third method of opening into the antrum without making a skin incision is to break through its inner wall below the middle of the inferior turbinated bone, using a bent sharp-pointed perforator (Mikulicz). The advantage of this method is that the pus flows, not into the mouth, but into the nose; its disadvantage, however, is, that it does not, like the operation from the mouth, open the lowest part of the antrum. Neither of the two latter methods allows of direct inspection of the antrum, or of the introduction of the finger into it as is the case when opened through the canine fossa.

Operations on the Nerves of the Face

15. Facial Nerve (Fig. 29). In operations in the fossa behind the ramus of the jaw, such, for example, as the excision of lymphatic glands and parotid tumours, it may be necessary to expose the facial nerve with the object of preserving it. Again, the nerve is occasionally exposed and stretched, for the purpose of arresting spasms of the facial muscles. The anterior border of the mastoid process and the posterior border of the jaw are the guides to the incision (Huter, Lökber, Kaufmann). The lobule of the ear is first separated along its pos-

terior attachment up to the cartilaginous part of the auricle, and the incision is then prolonged downwards to just behind the angle of the jaw. The nerve passes forwards at a point about midway between the angle of the jaw and the zygomatic arch. After dividing the skin and the parotid fascia, the posterior edge of the gland itself is

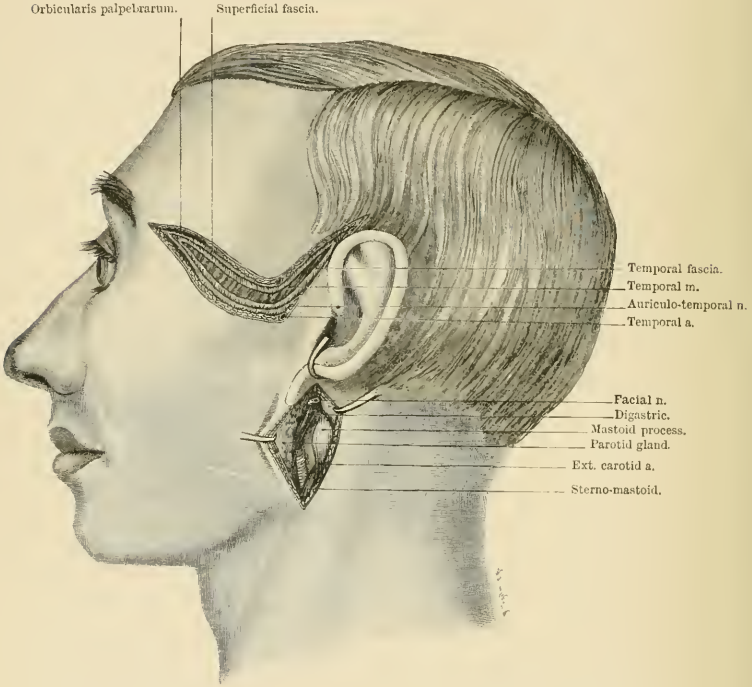

FIG. 29.—Incision for resecting the third (inferior maxillary) division of the trigeminal nerve at the foramen ovale. Exposure of the facial nerve.

exposed and drawn forward. The posterior auricular artery lies posteriorly. The tendinous fibres of insertion of the sterno-mastoid now appear, and the dissection is carried deeper along these at the anterior border of the mastoid process. The facial nerve is seen 1 cm. deeper, coming from the stylo-mastoid foramen towards the surface. Close to it is the origin of the digastric muscle, beneath which the external carotid artery passes upwards.

Trigeminal Nerve

Trigeminal neuralgias afford the chief indications for exposing the fifth cranial nerve. For the branches of the first division see page 36.

16. Second Division of the Trigeminal Nerve (Figs. 30 and 31). The infraorbital nerve is the branch which is most frequently the seat of neuralgia. This nerve may be stretched through an incision from the mouth which divides the mucous membrane and periosteum along the line of reflection from the upper lip to the canine fossa. The soft parts, including the periosteum, are separated upwards as far as the infraorbital foramen, through which the nerve makes its exit half an inch below the middle of the infraorbital margin. The nerve may be stretched either with an aneurism needle or by drawing it forcibly forwards with the finger.

A very good method, but one requiring an external incision, is the following:—An incision is made in the line of our normal incision for the upper jaw, beginning ½ cm. below the inner end of the infraorbital margin and passing somewhat obliquely downwards and outwards as far as the lower angle of the malar bone. The origin of the zygomaticus major muscle is exposed and separated. The branches of the facial nerve to the muscles below are avoided, as well as those to the orbicularis palpebrarum. The incision is then carried down to the bone dividing the origin of the levator labii superioris. The periosteum is now separated downwards as far as the exit of the nerve from the infraorbital canal, where, after being isolated from the infraorbital artery, an aneurism needle is passed under it. The periosteum is next separated backwards over the infraorbital margin and along the floor of the orbit until the entrance to the infraorbital canal is felt or seen (WAGNER). The thick anterior part of the roof of the canal is then removed with the hammer and chisel. In this way a considerable extent of the nerve is exposed and can be either stretched or removed. If the antrum has not been opened, the wound heals by first intention without leaving any deformity; indeed this is the rule even when the antrum has been opened.

In order to obtain permanent benefit after operations for this neuralgia, it is necessary to resect the second division of the trigeminal at the foramen rotundum, because the infraorbital nerve gives off its orbital and posterior superior dental branches before it enters the orbit, and because the superior maxillary trunk, as it traverses the spheno-maxillary fossa, gives off not only the infraorbital nerve but also the spheno-palatine branches to MECKEL'S ganglion, branches which cannot be isolated as is the case with the branches of the infraorbital.

17. Resection of the Orbital Nerve. An incision 1 cm. long is

carried down to the bone, beginning close to the outer commissure of the eyelids and passing obliquely outwards and somewhat downwards. The periosteum is detached from the outer wall of the orbit, and the nerve is torn across at its entrance into the foramen at the orbital surface of the malar bone.

The *superior dental nerves* may be divided alone (v. LANGENBECK),

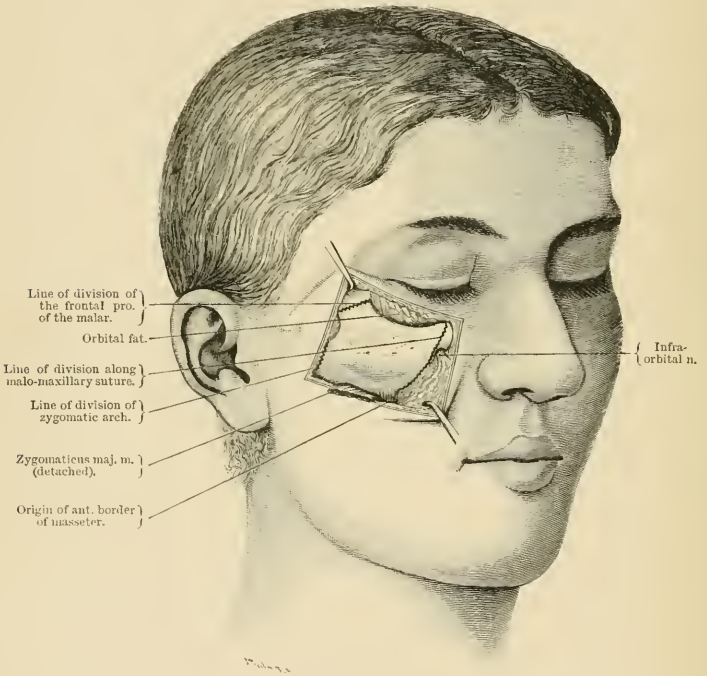

FIG. 30.—Resection of the second (superior maxillary) division of the trigeminal nerve.

by everting the upper lip and making a large incision down to the bone, above the level of the teeth, and then sawing or chiselling through the outer wall of the antrum (and its mucous membrane) from the osseous anterior nares as far back as the pterygoid process.

18. The more operations for neuralgia are limited to division of the peripheral branches, the smaller is the prospect of a permanent cure. By

exposing the **superior maxillary nerve at the foramen rotundum** (Figs. 30 and 31), the only branch which escapes is the recurrent branch to the dura mater. This proximal operation, however, has the disadvantage of paralysing the vidian, and therefore also the motor branches from the facial which accompany the palatine nerves to the muscles of the palate.

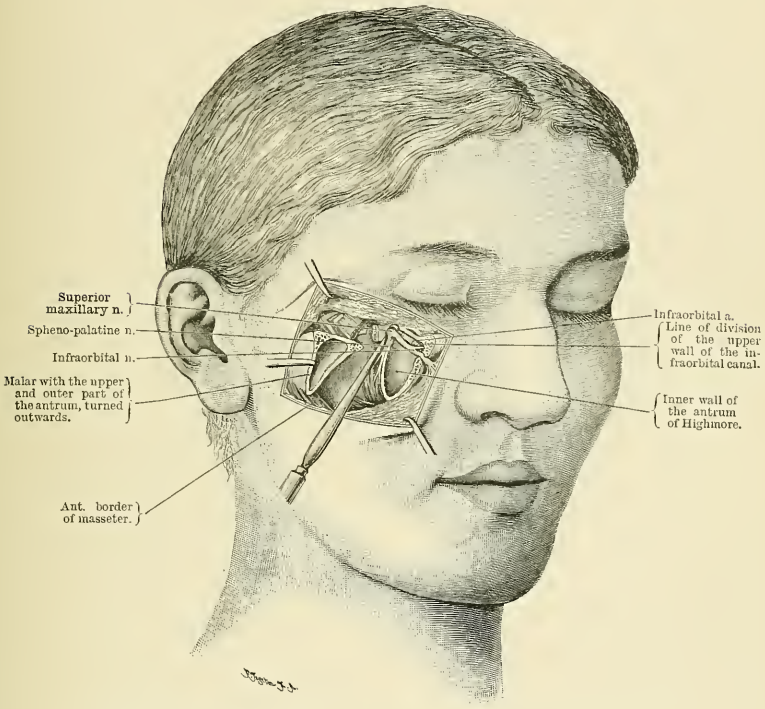

FIG. 31.—Exposure of the second (superior maxillary) division of the trigeminal nerve at the foramen ovale.

The dissection to reach the foramen rotundum is difficult. LANGENBECK introduced a tenotomy knife at the outer margin of the orbit below the external tarsal ligament. This puncture method is now given up, as one can never be sure of avoiding injury to neighbouring structures. The infraorbital artery is injured.

A preliminary resection of the malar bone is now generally adopted (Lücke, Lossen, Braun). Maintaining as we do that all incisions at right angles to the branches of the facial nerve are on principle unjustifiable, we proceed as follows. The incision is the same as for exposure of the infraorbital nerve (Fig. 27), except that it is longer. It begins 1 cm. internal to the infraorbital foramen, and $\frac{1}{2}$ cm. below the inner extremity of the infraorbital margin, and is carried outwards and slightly downwards over the lower part of the body of the malar bone as far as the zygomatic arch. The angular artery is either drawn aside or ligatured at the inner angle of the wound. The parotid duct lies below the incision. The inner end of the incision passes down to the bone between the lowest fibres of the orbicularis palpebrarum and the origin of the levator labii superioris; the former muscle is separated along with the periosteum to within the orbit, while the latter is detached, also subperiosteally, until the infraorbital nerve is exposed and secured at its exit. The outer part of the incision passes above the origins of the zygomatic muscles, which are separated downwards, and the anterior fibres of the masseter are detached from the lower and inner part of the malar bone. The outer and inner surfaces of the malar are laid bare by means of a periosteum detacher (Fig. 30), previous to chiselling it through. The malar process of the upper jaw is bared, upon its anterior surface up to the infraorbital foramen, and upon its upper surface as far back as the spheno-maxillary fissure, and is then detached with the chisel in such a way that the roof of the infraorbital canal is carried with it. Anteriorly, the process is chiselled through from above the infraorbital nerve, downwards and outwards, to just below the anterior end of the origin of the masseter, and then upwards through the outer wall of the antrum until it meets posteriorly the section through the orbital plate. In this way the outer part of the orbital plate and the superior-external wall of the antrum, together with its hinder angle, remain in connection with the malar bone, and are levered out along with it. Before this can be done, however, the upper edge of the wound must be drawn upwards to expose the fronto-malar suture, which is so chiselled through towards the posterior part of the spheno-maxillary fissure that its upper border, along with a portion of the zygomatic crest and of the orbital plate of the sphenoid, is removed along with it. The malar bone is dislocated upwards and outwards from the large wound with a strong sharp hook, and the orbital fat is carefully raised by a blunt retractor. The infraorbital nerve, which is kept drawn upon, can now readily be followed above the opened-up antral cavity as far as the foramen rotundum. A small hook is now passed behind the descending spheno-palatine nerves around the main trunk, which is either cut across or wrenched out (Thiersch). The infraorbital artery, which accompanies the infraorbital nerve, is either avoided or ligatured. The operation is completed by putting the malar bone back into position (fixation sutures being unnecessary)

and closing the wound with sutures. The resulting scar is not disfiguring.

The third division of the trigeminal nerve consists, at the foramen ovale, of motor (posteriorly and externally) and sensory portions so intimately united that they cannot be separated. Central division of the nerve, therefore, has the evil effect of producing a severe concomitant injury which is not intended, namely, unilateral paralysis and atrophy of the muscles of mastication. Happily experience shows (also in our own patients) that this unilateral paralysis of the muscles of mastication does not interfere greatly *per se* with the function of the jaw; it merely diminishes the firmness of closure of the jaw and the range of its lateral movements. These undesirable results of division of the trunk of the nerve at the foramen ovale make it justifiable to attempt a cure by stretching or dividing individual peripheral branches, in spite of the uncertainty of the result.

The lingual and inferior dental nerves are frequently the seat of neuralgias, especially the latter during its course through the inferior dental canal. Neuralgias occasionally occur also in the auriculo-temporal and long buccal nerves, the latter supplying the region of the angle of the mouth.

The inferior dental nerve may be exposed in various situations.

19. Its terminal portion, namely the **Mental Nerve,** is exposed by drawing the lower lip well down from the jaw and dividing vertically the mucous membrane at its line of reflection opposite the interval between the first and second bicuspid teeth; the periosteum is then divided, when the nerve will be found emerging from the mental foramen. Generally, however, the seat of neuralgia is more proximal—in connection with the teeth—so that the nerve must be exposed before it enters the inferior dental canal.

20. Inferior Dental Nerve (Fig. 32). The methods which have been employed for exposing this nerve are mainly two.

(*a*) *By trephining the ascending ramus* by means of an incision along the angle of the jaw. It is just here, however, that we meet with the branches of the facial which go to supply the muscles of the chin and lower lip. After making a curved incision along the angle of the jaw, the dissection must be continued carefully, the supramaxillary branch of the facial nerve being drawn downwards (compare the posterior part of our normal incision for the digastric triangle). The tendinous fibres of the masseter are then separated from the jaw with the periosteum-detacher and knife, after which a piece of bone is chiselled out from exactly the centre of the ascending ramus (Velpeau, Linhardt), whereby its inner surface is reached just at the entrance to the inferior dental canal. The method is very exact, and one is sure to strike the nerve. If primary healing occurs, there is no interference with the function of the jaw.

(*b*) PARAVICINI'S *method*. The mouth having been widely opened by means of a WHITE'S gag, the sharp inner edge of the anterior border of the ascending ramus is felt for, and an incision made along it through mucous membrane and periosteum down to the bone. The inner edge of

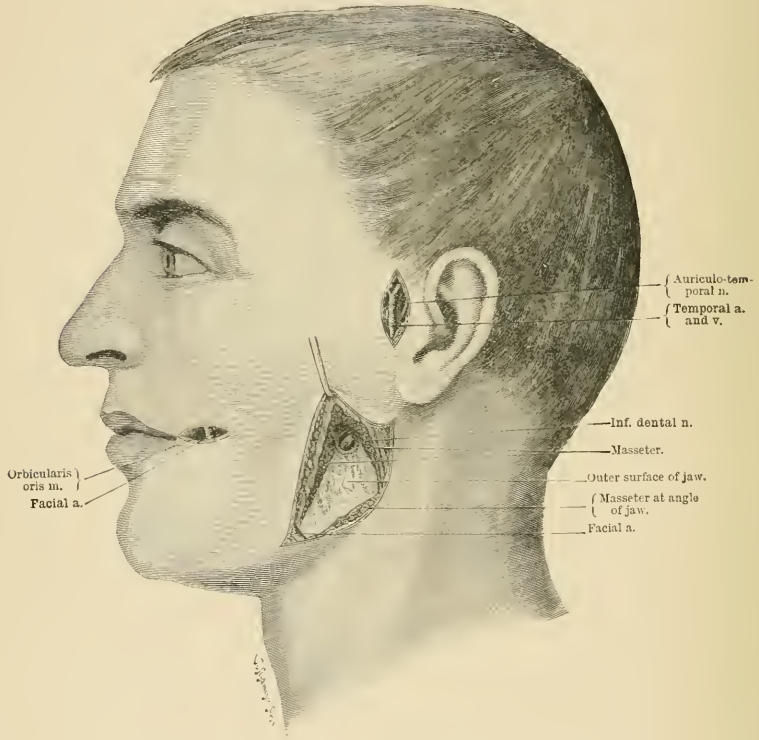

FIG. 32.—Ligature of the facial artery. Ligature of the temporal artery. Trephining the ascending ramus of the jaw to expose the inferior dental nerve.

the wound is now separated subperiosteally from the inner surface of the ramus by a blunt instrument until the spine is felt at the inner edge of the opening into the inferior dental canal. The nerve is found with certainty behind the spine. The operation is exceedingly simple, and does much less injury than those from the outside, but has the disadvantage of producing a wound in the mouth from which infection may proceed.

Moreover, the slower healing of an infected wound, combined with the fact that the internal lateral ligament is attached to the spine, entails a longer hindrance to the opening of the mouth.

21. The Lingual Nerve may also be exposed by PARAVICINI'S intra-buccal method. The following method, however, is simpler, because the nerve as it passes forwards between the anterior pillar of the fauces and the root of the tongue lies very superficially, indeed just under the mucous membrane. All that is required to expose the nerve is to make a small longitudinal incision through the mucous membrane, but not too near the tongue. The transverse splitting of the cheek by ROSER'S method is not a necessary preliminary. The disadvantage of the operation is that the wound is inside the mouth.

To avoid this drawback we have sought to expose the nerve from the outside and from below, namely, where it passes above the submaxillary gland. The incision is a part of our normal incision for the superior triangle of the neck (see footnote, p. 77); it exposes the lower border of the submaxillary gland, which is turned upwards, and the nerve is then secured where it is connected through the submaxillary ganglion with the submaxillary gland. The operation is considerably more difficult than that previously mentioned, but it possesses the advantage that primary healing is obtained with certainty.

A third method is to secure the nerve by trephining the ramus of the lower jaw in the same way as for the inferior dental nerve.

22. The Auriculo-Temporal Nerve (Fig. 16) is exposed by an incision extending vertically upwards from the root of the zygoma through the skin and fascia. This exposes the temporal artery, behind and under cover of which is the nerve.

23. The Buccinator Nerve is the sensory nerve for the region of the angle of the mouth. It lies to the inner side of the coronoid process of the lower jaw, and is to be secured at the anterior border of the process, whether the operation be performed from without or from within.

The operation from within (HOLL) is the simpler. After opening the mouth widely, and feeling for the ridge at the anterior border of the ramus of the jaw, an incision is made down upon it through the mucous membrane and the fibres of the buccinator muscle. The nerve will be exposed passing transversely forwards upon the process.

The operation from without (ZUCKERKANDL) is by an incision below the zygoma and the malar bone, beginning at the anterior border of the masseter and extending horizontally forwards above STENSON'S duct, avoiding the transverse facial artery. The fatty cushion of the cheek, which is met with anterior to the masseter, is pushed aside or removed in order to expose the anterior edge of the coronoid process, upon the inner aspect of which the nerve is found passing forwards upon the muscular fibres of the buccinator. This method from without has the disadvantage that the branches of the facial nerve are liable to be injured.

24. Inferior Maxillary Nerve. Operations on the *branches* of the third division of the fifth nerve are so often followed by recurrence of the neuralgia that nothing remains but to expose the trunk of the nerve at the foramen ovale (Figs. 29 and 33). The most certain method

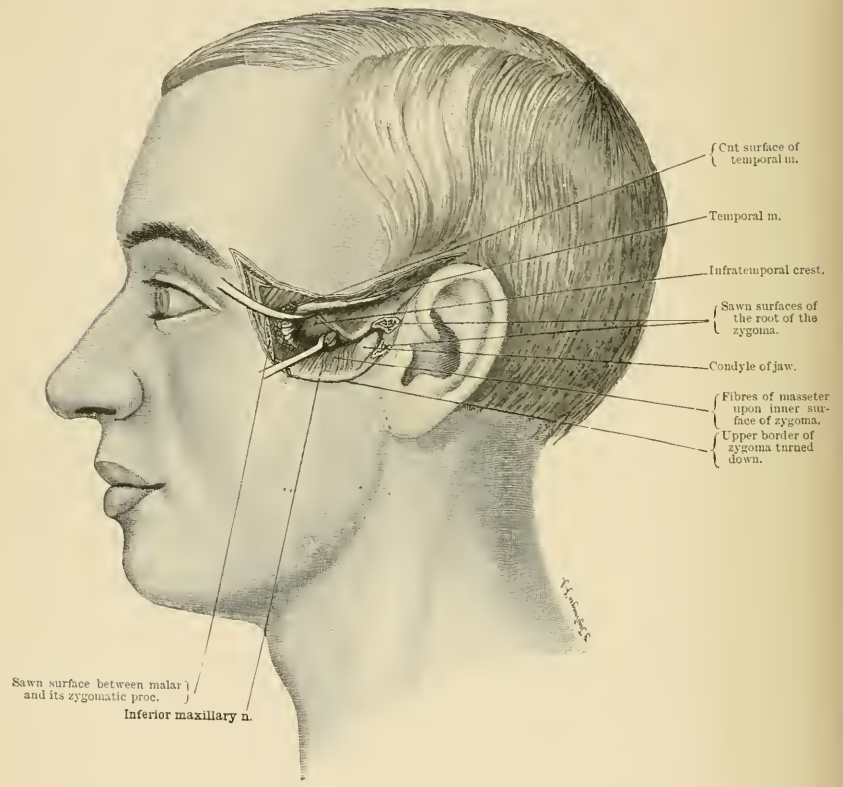

FIG. 33.—Exposure of the third (inferior maxillary) division of the trigeminal nerve at the foramen ovale.

of performing this operation is by resecting the zygomatic arch (LÜCKE, BRAUN, LOSSEN, KRÖNLEIN).

We are firmly of the opinion that here also only those incisions are to be employed which avoid injuring the branches of the facial nerve.

The incision (Fig. 29) begins just behind the frontal process of the malar, and is carried obliquely downwards and backwards to the posterior extremity of the zygomatic arch, and from thence upwards and backwards in front of the ear at right angles to the first part of the incision. This second part of the incision is carried down to the bone, the temporal vessels being ligatured. The incision divides the skin, some fibres of the orbicularis, the superficial fascia, and the strong temporal fascia, all of which are drawn downwards along with the branches of the facial nerve which go to the orbicularis and to the frontal muscles. The malar is now exposed immediately behind its frontal process, and is chiselled through vertically. The zygoma is divided posteriorly close to its root, and the whole zygomatic arch is then drawn down with a strong hook.

The outer surface of the temporal muscle is now exposed covered with fat, and its posterior and lower border is separated from the skull and drawn well forwards with a blunt hook. Only in the event of insufficient access is the insertion of the muscle into the coronoid divided, or the extremity of the process itself nipped off with bone pliers (Krönlein). There is no special reason for sparing the muscle; but its separation does less injury than its division, and gives a cleaner field for operating.

Next, the periosteum is divided from the anterior edge of the root of the zygoma forwards along the inferior temporal crest (upon the greater wing of the sphenoid), and the entire soft parts are detached along with it from the under surface of the great wing of the sphenoid. Thus the outer surface of the base of the pterygoid process is reached without further injury. The foramen ovale may now be felt close behind its sharp posterior border, about 3 cm. ($1\frac{1}{4}$ in.) deeper than (internal to) the anterior root of the zygoma. Occasionally there are two openings for the exit of the nerve. The large arteries (branches of the internal maxillary) remain in the soft parts which have been drawn downwards. The middle meningeal is an exception: it lies posteriorly. The inferior maxillary trunk is now exposed and dealt with. The operation is completed by wiring the zygomatic arch into position and closing the wound. The resulting scar is scarcely visible. To resect also the orbital plate of the malar, or to resect it as far forwards as its connection with the superior maxilla, is useless, as no further space is got for the isolation of the nerve.

Krönlein (*Arch. f. kl. Chir.* Bd. xliii.) has recently introduced a retrobuccal method with transverse splitting of the cheek (including two-thirds of the masseter) and extensive removal of the coronoid process, the branches of the nerve being then secured and followed up to the base of the skull. A somewhat similar method had previously been employed by Mikulicz, though in a different way, namely, as an extrabuccal method with division of the lower jaw. Recently in cases of persistent recurrence of trigeminal neuralgia the three divisions of the nerve have

been divided within the skull, and the *Gasserian ganglion* itself has been resected. KRAUSE has performed the operation osteoplastically by turning down a flap from the temporal region; and ROSE by simply trephining the base of the skull (also by DOYEN and LANPHEAR with various modifications).

ROSE proceeds in a way quite analogous to that which we have proposed for the third division of the trigeminus. We maintain that the incision we have described (Figs. 29 and 33) is a more certain one for avoiding the branches of the facial nerve than the modifications of it. ROSE, after drilling the holes for subsequent suturing, also saws through the zygomatic arch in front and behind, and throws it down along with the masseter. The coronoid process is then resected—a step which we consider thoroughly indicated, as it gives much better access. The interual maxillary artery is ligatured (so that one has not, like LANPHEAR, to deal with bleeding from the middle meningeal, the division of which at the foramen spinosum is unavoidable). The external pterygoid muscle is detached from the base of the skull, and the foramen ovale then sought for. The skull is trephined in front and external to the foramen, and the Gasserian ganglion is sought by following upwards the inferior maxillary trunk, which is divided, and the ganglion then scooped out with a sharp spoon; the second and first divisions of the trigeminus are likewise divided. A reflector must be used to get sufficient light.

It is obvious that such a "scooping out" of the ganglion is not an exact method, although according to ROSE and LANPHEAR it would appear to suffice, as ROSE has had five successful cases. DOYEN has "cut across the trunk of the nerve on the proximal side of the ganglion, by seeking a way between the internal carotid and the superior petrosal and cavernous sinuses at the upper border of the petrous temporal and between the two layers of the dura mater." That this procedure is also exceedingly dangerous is evident. After operating for the eighth time, in a case of intense and recurrent trigeminal neuralgia, we had to plug and eventually to tie the common carotid on account of intense hæmorrhage. The patient died six days later from pneumonia. HORSLEY has lost a patient seven hours after the operation. If we take into account the fact that the eye becomes anæsthetic, and can only be saved from other injuries with great care (DOYEN), (from ulceration and atrophy—the former occurring in one and the latter in another case of ROSE's), then we must admit that at present the operation seems scarcely justifiable.

It is really the intracranial section of the first division of the nerve which is attended with the danger of hæmorrhage and with harm to the eye. Section of the third and second divisions, on the other hand, can be quite well carried out after proper trephining. This is best done according to ROSE's method, by defining the seat at which the skull is to be opened by following up the inferior maxillary nerve to

the foramen ovale, after prophylactic ligature of the external carotid or the internal maxillary. By separating the dura mater and using a reflector, the exits of the second and third divisions are well seen, and may be divided without danger if the middle meningeal artery be avoided. The ophthalmic division must be exposed from the front by following it back along the roof of the orbit, and then rolling it up on the forceps and twisting it out (THIERSCH). This usually suffices for neuralgias of



FIG. 34 shows the result after complete excision of the upper jaw (for a malignant tumour) by the angular incision.

the ophthalmic division, possibly because it is not enclosed in a narrow bony canal.

25. Resection of the Upper Jaw (Figs. 7, 8, and 34). In order to have the courage to carry out a partial or total resection of the upper jaw with the necessary thoroughness during the early stage of a malignant tumour, that is, to expose the diseased parts so thoroughly that all suspicious tissues may be removed with certainty — it is necessary to be acquainted with methods of operation which do not result in too serious disfigurement. The play of the features, more especially, must not be unnecessarily interfered with. It is not there-

fore a question of obtaining fine scars, but of preserving intact the branches of the facial nerve. To this end the following incision is recommended (Figs. 7 and 8), viz. through the upper lip along the naso-labial ridge into the nasal orifice, from thence close around the ala of the nose, and obliquely upwards and inwards along the osseous anterior nares to the junction of the nasal bone with the upper jaw, and finally upwards as far as the inner angle of the orbit. In this way the levator alæ nasi muscle alone is divided, which is of no importance as regards the expression of the features. Fig. 34 shows how slight the deformity is. It is limited, in fact, to a slight falling in of the cheek and sinking down of the lower eyelid.

If one is satisfied that the above incision will not give sufficient access, a second incision is added to it, extending from near its upper extremity outwards and slightly downwards between the upper and lower facial regions, at the lower edge of the orbicularis palpebrarum and above the origins of the levator labii superioris and zygomatic muscles—our normal upper jaw incision below the infraorbital margin (Figs. 7 and 8). The flap, including the whole of the healthy soft parts and nerve branches, is reflected outwards, and the bone, or it may be the tumour, exposed. Hæmorrhage is temporarily arrested by grasping firmly the base of the flap, which allows of the vessels (angular, labial, infraorbital and transverse facial) being secured and ligatured. Immediate and thorough arrest of hæmorrhage is a very important step in the operation. For this reason, and on account of the loss of blood to the system generally, a *preliminary ligature of the external carotid* is very desirable, and makes the operation much cleaner and easier.

Next comes the separation of the upper jaw from its connections. When the disease is extensive, the nasal process of the upper jaw, together with the nasal bone, is divided with the chisel and bone pliers from the highest part of the osseous anterior nares, and the division continued backwards through the lachrymal and ethmoid bones as far as the hinder end of the spheno-maxillary fissure, no injuries of importance being inflicted. As regards the connection of the upper jaw with the malar bone, the line of division will depend upon the extent of the disease, being made either at the maxillo-malar junction, or in such a way as to remove the malar bone as well, by dividing its zygomatic and frontal processes with a chisel. For this a small separate incision must be made, the edges of which must be drawn firmly apart with sharp hooks.

There remains now the third connection, namely, with the upper jaw of the opposite side. The mucous membrane and periosteum of the palate having been divided down to the bone beyond the disease, and the soft palate having been separated from the hard palate with the knife, or better with the thermo-cautery, a chisel is placed between the median incisors and the hard palate cut through in its entire length.

Lastly, the connection with the pterygoid process is to be dealt with.

By drawing the flap forcibly backwards, the soft parts (mucous membrane, buccinator, and the two pterygoid muscles) can be separated from without as far back as the pterygoid process, and the hæmorrhage having been properly arrested, the process is chiselled through from without. When the pterygoid is not to be removed, the upper jaw is separated from it by forcibly wrenching it downwards; this should be done rapidly, in order that the arrest of hæmorrhage may at once be proceeded with, as the large terminal branches of the internal maxillary artery (spheno-palatine, descending palatine, and infraorbital) are torn through.

For the after-treatment, either of the following plans may be adopted. If the bleeding has been completely arrested, the cavity is irrigated very frequently (every two hours) with weak carbolic (0·5 per cent) or lysol (0·2 per cent). When, however, this is not practicable, or when there is still bleeding to be arrested, the cavity should be plugged with iodoform gauze, which is changed as soon as it becomes loose, or with carbolic gauze changed more frequently.

26. A less extensive operation is the **Osteoplastic Total Resection of the Upper Jaw,** whereby the jaw is turned aside and afterwards brought back into position again. This procedure is indicated in tumours of the base of the skull (basi-occiput and its neighbourhood); and when sufficient space is not obtained by GUSSENBAUER'S method of dividing the soft palate and chiselling out the hard palate, especially in retromaxillary tumours. The difference between this and the previous operation is, that after making the skin incision the soft parts are not separated from the bones, but the bony connections of the upper jaw having been severed, the latter is turned aside with the soft parts still connected with it. Division of the frontal process of the malar bone must be made through a small oblique incision in the same way as has been described in resecting the superior maxillary nerve at the foramen rotundum.

To expose the spheno-maxillary fossa the malar bone is resected in the same way as has already been described in dividing the second division of the trigeminal nerve.

If it be desired *to expose the nasal cavities either alone or together with the antrum of Highmore,* it is sufficient to perform a *partial osteoplastic resection of the upper jaw* in the following manner.

The skin incisions are the same as for resection of the upper jaw except that the upper lip is not divided (Figs. 7 and 8), that is to say, the incision begins at the nasal orifice, and after passing round the ala nasi extends upwards to near the inner angle of the orbit and from thence transversely outwards below the infraorbital margin to the malar bone.

From the upper end of the osseous anterior nares the structures are divided in the following manner and order: first along the junction of the two nasal bones, then outwards, separating the connections of the nasal bone, the nasal process of the superior maxilla, and the lachrymal

bone from the frontal; and lastly, the bone pliers or a small chisel are carried obliquely downwards and backwards through the orbital plate of the ethmoid as far as the spheno-maxillary fissure. From the lowest part of the osseous anterior nares the inner and anterior walls of the antrum are divided with a chisel as far as the infraorbital canal, and the orbital plate of the upper jaw is then divided backwards along this canal from the horizontal skin incision. The bones together with the soft parts can now be drawn outwards, and the nasal cavity and antrum of Highmore, which have been transformed into a single cavity, are exposed.

In describing the operations on the nose it has already been pointed out how both halves of the upper jaw can be separated from each other, and the base of the skull made accessible, merely by dividing the upper lip and splitting the hard and the soft palate mesially.

27. Resection of the Lower Jaw. This is a simple operation, but here again we must not produce unnecessary deformity about the mouth by injuring the supramaxillary branches of the facial nerve.

The simplest incision (Fig. 7) is a mesial one dividing the lower lip, and extending downwards if necessary to the middle of the hyoid bone. This gives abundant room when the disease involves the middle and even a considerable portion of the body of the jaw. The vessels are at once seized with artery forceps. When the disease involves the region of the angle and ascending ramus, and when it is necessary to expose and clear out the submaxillary fossa for a malignant tumour, a lateral incision is added. On account of the facial nerve it must be placed below and not over the margin of the jaw; indeed it should pass upwards and backwards from the hyoid bone along the submaxillo-cervical crease to a finger-breadth behind and below the angle of the jaw, and from thence up to the apex of the mastoid process (compare our *normal incision* for the superior triangle of the neck).[1] The flap thus made is dissected up and fixed by a stitch or two to the skin of the face. In doing this, keep as near as possible to the bone by including the muscular structures (anteriorly, the levator menti, depressor labii inferioris, and depressor anguli oris; posteriorly, the buccinator and masseter) in the flap. From the inner surface of the jaw are detached, anteriorly the digastric, mylo-hyoid, genio-hyoid, and genio-hyo-glossus; posteriorly the internal pterygoid. When the glands below the body of the jaw are diseased, the anterior and posterior bellies of the digastric are first exposed, and the entire bunch of lymphatic glands, including the salivary glands, is then dissected up over the edge of the jaw.

It is advantageous to saw through the jaw before detaching the muscles, in order that by drawing it well forwards the soft parts may be put on the stretch. After dividing the muscles and the mucous membrane, the jaw is drawn downwards so as to expose the coronoid

[1] See footnote, page 77.

process, which, along with the insertion of the temporal muscle, is snipped off with bone pliers. In disarticulating the condyle, sharp instruments are avoided so as not to wound the internal maxillary artery. The capsule of the joint and the insertion of the external pterygoid are torn through by torsion after all the other structures have been divided. The facial artery has already been divided and ligatured in dissecting up the soft parts. When the horizontal portion of the jaw is sawn across, the inferior dental artery is divided as it lies in the inferior dental canal, which is plugged with a pellet of wax; when the entire half of the jaw is removed, this artery is ligatured in the posterior and upper angle of the wound, either before or after the jaw is drawn downwards, or in dissecting up the internal pterygoid muscle, when the inferior dental nerve will be either cut or torn across. Just as in some cases of resection of the upper jaw, so here also it may be necessary, in order to avoid loss of blood, to ligature the external carotid above the superior thyroid, or, it may be, above the origin of the lingual.

When the entire half or the whole of the jaw has been removed, especially if the operation has been done subperiosteally, and the periosteum preserved, a mould (CLAUDE-MARTIN) is to be made, over which the periosteum is stitched so that the newly-forming jaw may be properly shaped.

28. Osteoplastic Resection of the Lower Jaw is an important preliminary operation for exposing the floor of the mouth, the root of the tongue, the fauces, and the deep pharyngeal structures. For the structures in front of the fauces, *mesial division of the lip and lower jaw* gives excellent access. It has the great advantage that after introducing a wire suture the movements of the lower jaw suffer no noteworthy temporary impairment, and union in good position is readily obtained.

For cases in which the disease affects the fauces and the pharyngeal structures posterior to them, division of the lower jaw becomes necessary, and, normally, this should be done *in front of the ascending ramus*. The incision is the same as for resection of the lower jaw, namely, in a line from the mastoid process towards the hyoid bone, in greater or less extent according to circumstances. After ligaturing the facial artery, the jaw is exposed at the anterior border of the masseter, the periosteum is separated forwards and backwards, and then after the mucous membrane has been perforated with a periosteum detacher, the jaw is divided with a keyhole saw behind the molar teeth.

Before using the saw it is desirable to drill one or two holes for the passage of the steel wires which are afterwards used for accurately suturing the jaw. The sawing is to be done obliquely, in such a way that the line of section is farther forwards upon the outer and lower aspect than upon the inner and upper, because the sawn extremity of

the posterior fragment of the jaw has a tendency to pass inwards and upwards. The ascending ramus is now pulled upwards with a sharp hook, whilst the body of the jaw is drawn forward.

Resection of the condyle of the lower jaw for bony anchylosis, or for tubercle, is a simple operation. The incision is placed so as to avoid injuring the facial nerve, and is the same as the lowest part of the one employed in resecting the inferior maxillary nerve (Fig. 33). The skin and fascia are drawn downwards, and, after a portion of the masseter has been detached from the zygomatic arch, the joint is opened. Extending upwards behind the condyle is the auriculo-temporal nerve, whilst below it is the internal maxillary artery. The resection of the joint gives very good functional results.

29. *The structures in the mouth and pharynx* can also be rendered accessible without osteoplastic resection of the lower jaw. An excellent method is by a *transverse incision through the cheek* (Fig. 8), as recommended by ROSER for exposing the lingual nerve: it extends from the angle of the mouth transversely backwards parallel to the branches of the facial nerve as far as the masseter, dividing skin, orbicularis oris, buccinator, and mucous membrane. The incision results in a scar which tends to become drawn in by contraction. Still, however, the resulting deformity is inconsiderable (Fig. 35), because the play of the features is in no way diminished, as the branches of the facial nerve have been preserved. *Stenson's* duct and the transverse facial artery lie above the incision, but the facial artery is divided and requires two ligatures. KRÖNLEIN has employed this incision in his retrobuccal method for resection of the trigeminal nerve.

30. Incisions into the Tongue and at the Floor of the Mouth. These are only to be made after thoroughly opening the mouth by the introduction of a suitable gag (WHITE'S), and after drawing forward the tongue by means of a silk loop carried deeply through it in the mesial sagittal plane. A considerable degree of anæsthesia is necessary before the mouth can be satisfactorily opened, especially in closure of the jaws caused by inflammation or by other painful infiltration of the soft parts between the upper and lower jaws, or in connection with the latter. Incisions may be made upon the dorsum of the tongue without fear of injuring the larger branches of the vessels and nerves. Whenever practicable, the middle line should be selected, as causing least injury.

The larger vessels lie laterally and at the floor of the mouth, namely, the lingual and sublingual arteries and veins; also the hypoglossal, lingual, and posteriorly, the glosso-pharyngeal nerves along with *Wharton's* duct and the ducts of *Rivini*. The nearer the incision is kept to the jaw, the more certain are all those structures to be avoided. The lingual vessels and nerve may be exposed close to the edge of the tongue, under the inferior lingualis and upon the outer aspect of the genio-hyo-glossus. Farther back the artery is covered by the hyo-glossus.

Near the tip the vessels wind towards the under surface of the tongue. Prophylactic ligature of the lingual artery is to be recommended when there is danger of severe hæmorrhage following incisions into the tongue.

31. Excision of the Tongue. In the case of well-circumscribed new growths of the tongue, the operation is performed from the mouth after introducing a WHITE'S gag; or, if necessary, after splitting the cheek

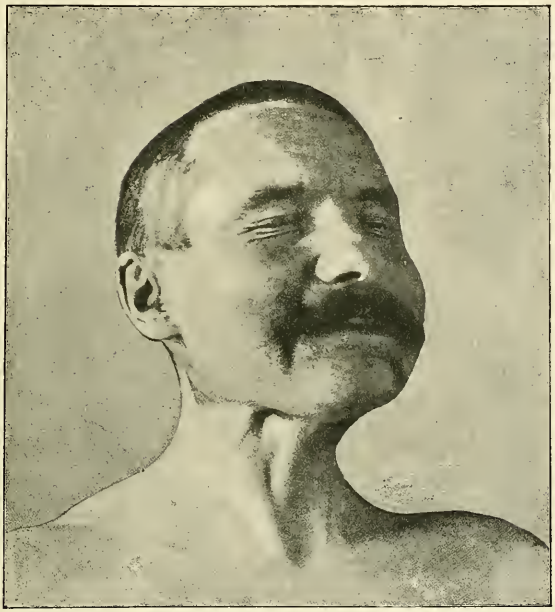

FIG. 35 shows the action of the facial muscles after the wound for splitting the cheek transversely has healed.

transversely in the manner already described; this latter gives excellent access to the lateral parts of the tongue. In dealing with malignant new growths, however, especially with cancer, the submaxillary fossa also must always be cleared out.

If, on the other hand, the carcinoma has already extended beyond the limits of the tongue and has invaded the floor of the mouth and the jaw, then the nature of the interference will be influenced by the seat of the disease in the latter. If recurrence is to be prevented, any adherent

portion of jaw must always be freely removed. *Resection of the jaw* has been employed by many surgeons as a preliminary to the removal of extensive carcinoma of the tongue, and one would begin with this when the indications for resection are clearly present. When, however, this is not the case, we still maintain that in an extensive carcinoma of the tongue, the method of extirpating the organ from its base as proposed by us is preferable, (1) because it gives very good access, (2) because it permits of the simultaneous removal of the glands as well as all the tissue which intervenes between them and the primary seat of disease, (3) because it admits of preliminary ligature of the lingual or external carotid arteries, (4) because after preliminary tracheotomy the pharynx can be plugged, a step which more certainly than any other prevents the occurrence of septic pneumonia by the disturbed deglutition. (5) V. SIVEL, by comparisons, established the advantage of this method, especially from the point of view of antisepsis.

According to the very exact records of our former assistant, Dr. SACHS, we have only lost one out of twelve cases; and out of five who remained free from recurrence some years after operation, three were operated upon by this method.

The incision begins below the mastoid process and extends along the anterior border of the sterno-mastoid, and then forwards along the crease between the floor of the mouth and the neck to the middle line, and, lastly, upwards to the lower border of the jaw. After ligaturing the subcutaneous veins, the flap thus formed is dissected up and fixed with a suture to the cheek. Next comes the removal of all enlarged glands under the upper end of the sterno-mastoid, and beneath the angle and the body of the jaw. The anterior border of the sterno-mastoid is exposed as far down as the sheath of the large cervical vessels and the greater cornu of the hyoid bone. Anteriorly, the anterior belly of the digastric is laid bare down to the same bone, several veins being ligatured. The bunch of glands is now raised up until the entire length of the posterior belly of the digastric and the stylo-hyoid muscles are exposed in the posterior and lower part of the wound. The submaxillary gland is dissected up as far as the border of the jaw, and removed at the same time as the lymphatic glands. The facial vessels are seized and ligatured while the submaxillary gland is being pulled upwards, and the lingual artery as it disappears beneath the hyo-glossus muscle, together with numerous small veins, is also ligatured. The under surface of the mylo-hyoid muscle is now exposed with the mucous membrane lying above it; after ascertaining the exact limit of the new growth, these are perforated, and from the opening the mucous membrane is further divided beyond the tumour, artery forceps being applied to the more important bleeding vessels of the mucous membrane. Further hæmorrhage is readily arrested by dragging forward the soft parts by means of the finger introduced through the wound in the mouth.

The tongue is detached from the hyoid bone and all infiltrated tissue removed, any hæmorrhage being readily and securely arrested. The tongue can be well drawn out through the floor of the mouth as soon as the mucous membrane has been divided.

If, in order to facilitate the administration of the anæsthetic, a preliminary tracheotomy has been performed, the entrance to the larynx is at once plugged with sterilised gauze introduced from the pharynx.

A morphia injection is here clearly indicated to assist the action of small doses of the chloroform; the morphia should be administered a quarter to half an hour before the anæsthetic, $\frac{1}{5}$ grain for strong and $\frac{1}{6}$ for weak individuals.

If the carcinomatous infiltration has involved the lateral and posterior walls of the pharynx, especially the soft palate, and if an exact division of the soft parts cannot be made from the mouth with the thermo-cautery, it may be necessary to separate the periosteum in front of the masseter and internal pterygoid muscles, to saw through the jaw, and to drag it upwards and outwards with a strong hook. In this way one can reach far up the pharynx along the inner surface of the internal pterygoid muscle. Two holes must be bored in the jaw for subsequent suturing previous to dividing it. In such an extensive excision it is best to perform a prophylactic ligature of the external carotid artery.

The after-treatment is to leave the wound open so that the entrance to the larynx may be plugged with sterilised moist (salt solution) gauze, which is to be frequently changed; a carbolic or sublimate gauze dressing is applied over the wound. The patient is fed with a tube each time the wound is dressed.

32. In **Tonsillotomy** an injury to the internal carotid artery is, according to ZUCKERKANDL, not easily produced, as the artery is separated from the pharyngeal wall by the stylo-glossus and stylo-pharyngeus muscles. The tonsillar artery, on the other hand, which usually springs from the ascending palatine, may bleed severely, because it is adherent to the lower wall of the capsule of the tonsil and cannot retract. In such a case it may be necessary to ligature the external carotid.

G. THE SUPERIOR LATERAL TRIANGLE OF THE NECK[1]

Normal Incision. According to our principle of arranging skin incisions along the natural cleavage lines of the skin, we find that the best incision for exposing the organs in the fossa below and behind the jaw is

[1] For practical reasons we regard it as bounded by the lower border of the jaw above, by the middle line as far down as the upper border of the thyroid cartilage internally, and by the anterior edge of the sterno-mastoid posteriorly.

that which we have already given for resection of the lower jaw. It runs from the anterior part of the apex of the mastoid process to the middle of the hyoid bone, passing a finger-breadth below and behind the angle of the jaw, where it crosses the anterior border of the sterno-mastoid muscle. This incision possesses the great advantage of falling along the

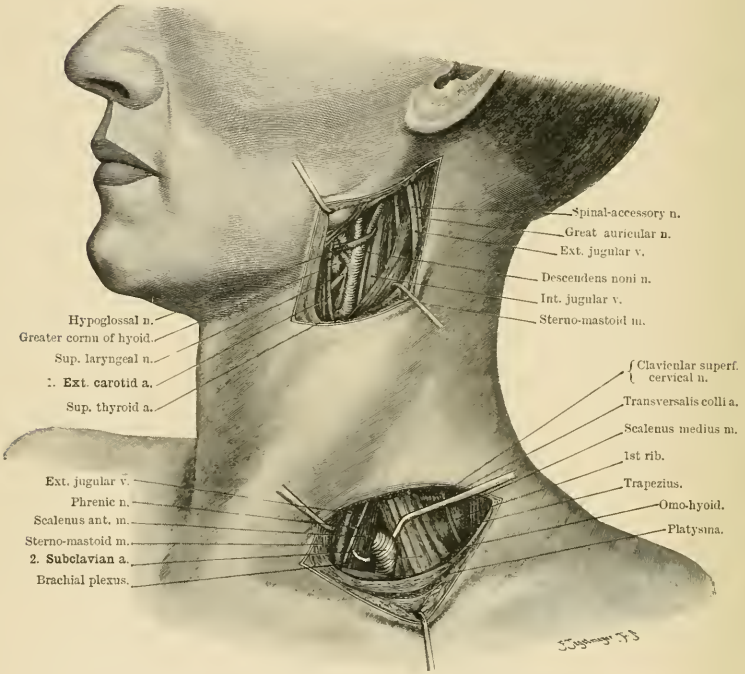

FIG. 36.—Ligature of the external carotid with the origins of the lingual, facial, and occipital arteries. Ligature of the subclavian artery.

boundary line, at which the muscles, running from above downwards, viz. the digastric, stylo-hyoid, genio-hyoid, mylo-hyoid, and hyo-glossus, and those running from below upwards, viz. sterno-hyoid, thyro-hyoid, and omo-hyoid, meet or terminate. The muscles which cross this boundary line are either unimportant, like the platysma, or lie to one side or posteriorly, like the sterno-mastoid and the muscles of the vertebral column.

Moreover, by this incision it is possible to avoid the important nerves, inasmuch as the main trunks lie above or posteriorly, and can be drawn aside, whilst their branches ramify upwards and downwards from the line of incision. Thus the vagus, the sympathetic, the spinal-accessory, and the descendens noni lie posteriorly along with the sterno-mastoid muscle; the lowest branch of the facial, the hypoglossal, the lingual, and the glosso-pharyngeal lie above; the superior laryngeal branch of the vagus is drawn downwards.

In the third place, the incision gives access to the bifurcation of the common carotid artery and to the origin of the branches of the external carotid. The common carotid bifurcates at the level of the upper border of the thyroid cartilage, and above it follow, in close order, the origins of the branches of the external carotid. At the same level the facial and anterior temporo-maxillary veins join to form the common facial vein, which opens into the internal jugular. From this normal incision, therefore, we can expose and ligature not only the trunks of the great vessels of the neck, but also the greater number of their branches.

We have therefore designated this incision *the normal incision for the superior triangle of the neck*, and all other incisions for this triangle, whether longer or shorter, are made along the same line.

33. External and Internal Carotid Arteries (Fig. 36). When ligature of the external carotid is sufficient for the arrest of hæmorrhage, the common carotid must never be ligatured instead, as it is dangerous, giving rise, according to Pilz and Friedländer, to brain disturbances in 19 to 32 per cent, and to a fatal termination in 13 to 18 per cent. Recently, Lipps has demonstrated the same fact from an analysis of 130 cases of ligature of the common carotid. Ligature of the external carotid is not only indicated in hæmorrhage, and when malignant tumours are adherent to it, but also as a prophylactic measure in extensive operations upon the jaws, the nose, and the face.

The point of our normal incision where the artery is felt to pulsate and where it is ligatured, is at the anterior border of the sterno-mastoid muscle. The edge of this muscle is much more vertical than is usually represented, being drawn forwards towards the angle of the jaw by the cervical fascia. The artery is ligatured opposite a point which lies a finger-breadth vertically below the angle of the jaw; to expose the vessel, therefore, we employ that part of our normal incision which courses over this region. The incision divides the skin and the platysma; the fibres of the latter pass upwards and forwards over the margin of the jaw, forming occasionally a well-developed muscular layer. At the posterior part of the wound is the external jugular vein, and behind it the great auricular nerve, both ascending vertically upon the sterno-mastoid. They are not divided, but are drawn backwards. On dividing the cervical fascia the anterior border of the sterno-mastoid is exposed, and the facial vein is seen passing downwards over the digastric muscle to

join the jugular; after drawing downwards the former vein, and ligaturing some of its branches, the external and internal carotid arteries come into view, the latter lying posteriorly. The internal carotid gives off no branches, whilst the external carotid is identified by giving off the superior thyroid close to its origin. The *hypoglossal nerve* winds across the external carotid from behind forwards opposite the origin of the facial artery, whilst bending downwards and backwards over the nerve is the small sterno-mastoid artery. Ligature of the external carotid is not an easy operation, because the only guides are soft parts (especially the sterno-mastoid muscle), which may vary with each operation. The descendens noni nerve, which supplies the depressors of the larynx, must be avoided. It is still more important, however, to avoid the *superior laryngeal nerve*, which passes transversely forwards behind the artery and the thyro-hyoid muscle.

The majority of the branches of the external carotid, viz. the *superior thyroid, lingual, facial, and occipital arteries*, may be ligatured at their origin from the same incision. The course of these four important branches is sufficiently characterised by their direction, namely, downwards, forwards, upwards, and backwards respectively; and for practical purposes they may be regarded as springing from that part of the carotid which is crossed by the hypoglossal nerve. When those arteries are to be ligatured more peripherally, situations are chosen which are more readily accessible and less dangerous.

34. Superior Thyroid Artery (Fig. 36). The superior thyroid artery is ligatured at the apex of the lateral lobe of the thyroid gland. The incision corresponds to that part of our *normal incision* which extends from the anterior border of the sterno-mastoid muscle to the body of the hyoid bone, the lower edge of the wound being well drawn down. In cases in which the gland does not reach so high up, it is better to make the incision 3 cm. ($1\frac{1}{4}$ in.) lower down, so as to correspond to the upper border of the thyroid cartilage. The anterior branch of the artery, in enlargement of the thyroid gland (the only case where the ligature in question is necessary), is always to be felt descending upon the anterior and inner aspect of the upper horn of the gland, close to the larynx. By following this branch upwards over the apex of the upper horn, the trunk of the artery will be found with certainty.

35. Lingual Artery (Fig. 37). Ligature of the lingual artery is important, because it supplies a deeply-situated organ, the direct arrest of hæmorrhage from which is not always easy. It is often desirable, therefore, to perform a prophylactic ligature. The artery has a very definite course, inasmuch as it is directed towards the hyoid bone, and is placed close to the posterior extremity of its greater cornu. It is most conveniently ligatured at this situation, because in most people the extremity of the greater cornu of the hyoid bone can be felt through the skin, and therefore serves as a very distinct guide for the incision, which

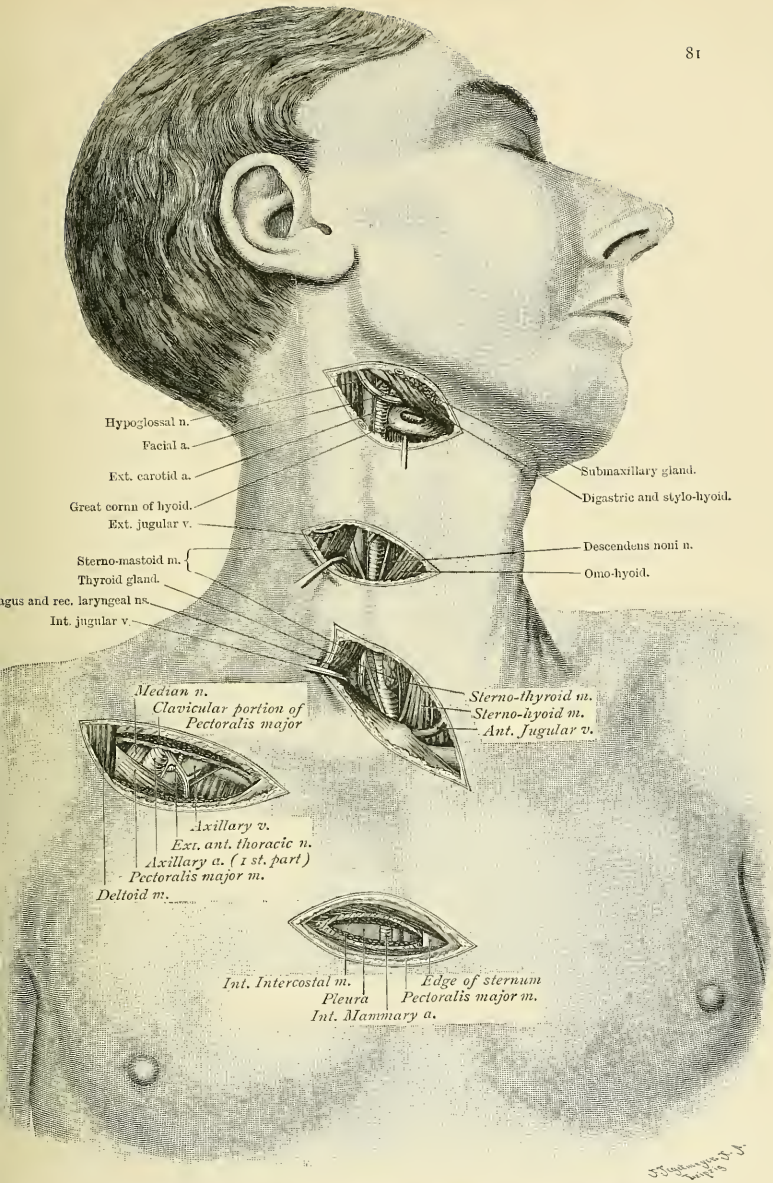

FIG. 37.—Ligature of the lingual artery above the greater cornu of the hyoid. Ligature of the common carotid at the level of the cricoid cartilage. Ligature of the innominate artery. Ligature of the first part of the axillary artery. Ligature of the internal mammary artery.

is made in the direction of our normal incision from the edge of the sterno-cleido-mastoid muscle along the greater cornu of the hyoid bone as far as its body. The incision extends through skin, platysma, and fascia, just as if one wished merely to expose the greater cornu of the hyoid bone. The facial vein often passes vertically downwards, or downwards and backwards across the field of operation. The lower border of the submaxillary gland appears beneath the upper edge of the wound, below which the posterior belly of the digastric and the stylo-hyoid muscles descend towards the body of the hyoid bone.

It is well to press forwards the hyoid bone from the opposite side of the neck. After exposing the greater cornu in this way, it is seized with a hook and the bone is drawn forwards. This has the great advantage of rendering the entire field of operation more superficial. At the thickened posterior extremity of the cornu of the hyoid bone the fibres of the hyo-glossus muscle ascend vertically in a characteristic manner. The hypoglossal nerve passes from behind forwards upon the outer surface of this muscle, and behind the extremity of the hyoid bone it winds round the external carotid artery. One must now be very careful to cut through neither more nor less than the muscular fibres of the hyo-glossus close above the club-like extremity of the greater cornu of the hyoid bone, immediately above which the artery lies. We consider this to be the most reliable method of ligature.

The artery may also be ligatured *above the digastric muscle.* The incision is made parallel to the greater cornu of the hyoid bone through skin, platysma, and fascia, and the lower border of the submaxillary gland is drawn upwards along with the facial vein. The artery lies in the angle formed by the upper border of the digastric (together with the stylo-hyoid muscle) and the posterior border of the mylo-hyoid under the ascending fibres of the hyo-glossus. Upon the outer surface of this latter muscle is the hypoglossal nerve, and often the lingual vein.

All hæmorrhages in connection with the head, with the exception of intracranial and orbital hæmorrhages, can be arrested with certainty and without danger by *ligature of the external carotid.* The common carotid artery must never be tied instead of the external carotid, since it can never be predicted whether or not—especially in older persons—a permanent disturbance of the circulation in the brain will be the result.

36. Ligature of the Internal Carotid. In intracranial hæmorrhages, ligature of the internal (Fig. 36) is preferable to that of the common carotid, as the collateral supply through the angular termination of the facial and the ophthalmic arteries is retained. The operation is the same as that for ligature of the external carotid, except that intervening between the two vessels are the stylo-glossus and stylo-pharyngeus muscles, along with the deep fascia and the stylo-maxillary ligament.

In pharyngeal operations, in which sudden profuse hæmorrhages may occur, occasionally also in tonsillotomies, it is important to be

clear as to whether the bleeding arises from the internal carotid, or from the branches of the external carotid (pharyngeal and tonsillar arteries). As regards tonsillotomy, although the internal carotid can be felt pulsating behind the tonsil, injury of the artery is not usually to be feared, because opposite the tonsil the artery is separated from the pharyngeal wall by the stylo-glossus and stylo-pharyngeus muscles. On the other hand, an injury to the pharyngeal and ascending palatine arteries and to their tonsillar branches is possible (ZUCKERKANDL).

37. Exposure of the Hypoglossal Nerve (Figs. 36 and 37) falls to be considered along with that of the external carotid artery round which it winds, and in the anterior part of its course with that of the lingual artery. The nerve, however, lies upon the outer surface of the hyo-glossus muscle, the artery upon its inner surface.

38. The Lingual Nerve may be exposed by turning aside the sub-maxillary gland and by nicking the posterior fibres of the mylo-hyoid at the outer surface of the hyo-glossus muscle and towards the mucous membrane of the floor of the mouth. The nerve, however, is placed very deeply.

39. Superior Laryngeal Nerve (Fig. 36). This branch of the vagus, which is essentially the sensory nerve for the larynx, is exposed by drawing downward the lower edge of the hyoid portion of our normal incision. At the point of origin of the facial artery it passes deeply behind the external carotid, then forwards parallel to the greater cornu of the hyoid bone across the middle constrictor of the pharynx, and upon the outer surface of the thyro-hyoid membrane, and disappears under the posterior border of the thyro-hyoid muscle. It is of very great importance to bear in mind the course of this nerve, as its injury causes insensibility of the larynx, in consequence of which, in operations upon the larynx and the mouth, the patient is specially liable to die of septic pneumonia (*Schluck pneumonie*).

40. Ligature of the Internal Jugular Vein (Figs. 36 and 37). The method of performing this operation should be considered along with that of ligature of the internal carotid. The vein lies on the outer side of the internal carotid. Ligature of this vein is, apart from hæmorrhages, especially important in infectious thrombosis connected with its tributaries. When, for example, otitis media and mastoidea invade the bones, thrombosis may occur in the lateral sinus; by disintegration of the thrombus embolic pyæmia occurs. The internal jugular vein is ligatured with the object of preventing this.

41. The Spinal-Accessory Nerve (Fig. 36) passes downwards and backwards in front of the internal jugular vein, beneath the upper third of the sterno-cleido-mastoid muscle. It gives branches to the sterno-cleido-mastoid and trapezius muscles. In spasmodic conditions which are limited to these two muscles, the stretching or tearing out of the nerve gives good results. The nerve is to be avoided, however, in

operations in the neighbourhood of the upper end of the sterno-mastoid, especially in excising the lymphatic glands in this region. To expose the nerve we employ the mastoid portion of our normal incision, viz. from the apex of the mastoid process to below the angle of the jaw. After freeing the external jugular vein and the great auricular nerve,

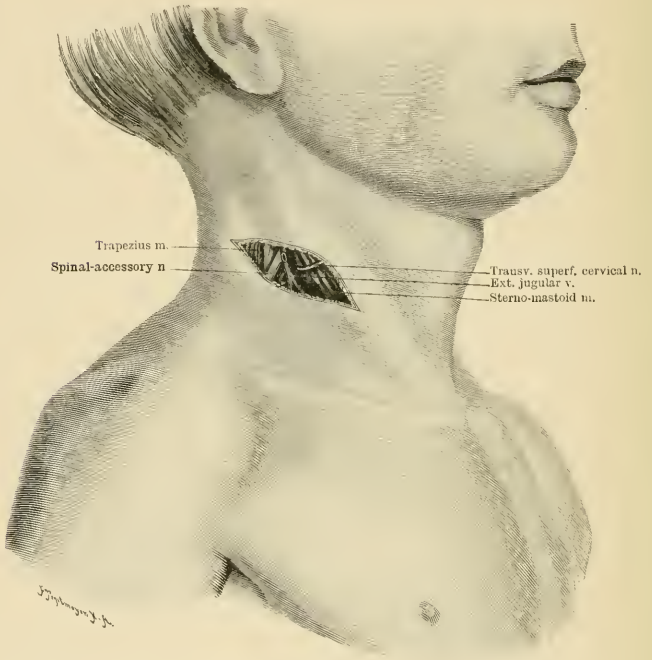

FIG. 38.—Exposure of the spinal-accessory nerve in the middle of the neck.

the sterno-mastoid muscle is drawn forcibly backwards. The spinal-accessory nerve has a definite course downwards and backwards under the sterno-mastoid in front of the prominent transverse process of the atlas. It lies close to the under surface of the muscle. The occipital artery passes backwards over the nerve. The lowest branch of the facial nerve to the muscles of the chin may come into view at the upper edge of the wound, and is to be avoided. Higher up

the nerve is covered by the posterior belly of the digastric muscle. Anteriorly it is accompanied by the artery to the sterno-cleido-mastoid muscle from the external carotid.

For the exposure of the nerve *lower down* (Fig. 38), compare "Ligature of the Common Carotid Artery" (pages 89 and 90).

42. Lateral Pharyngotomy. Lastly, the normal incision for the superior lateral triangle of the neck is used for all operations where we desire to expose from the exterior the lateral aspect of the pharynx along with the tonsil and base of the tongue. If the incision be employed in its full length, the lateral aspect of the tongue as far as the epiglottis and the lateral wall of the pharynx together with the whole of the retro-pharyngeal space may be exposed. As the posterior part of the incision must, in some cases, be taken full advantage of, the great auricular nerve and the external jugular vein must occasionally be divided.

After dividing the skin, platysma, and fascia, the submaxillary region is exposed. The facial vein which lies upon the outer surface of the posterior belly of the digastric, and the facial artery which lies beneath the submaxillary gland, together with the gland itself, must be dealt with before the floor of the mouth and the wall of the pharynx can be reached. The vessels are divided between two ligatures, while the gland is drawn out and thrown upwards, or extirpated. It may be necessary also to ligature close to their origins the lingual, ascending pharyngeal, and ascending palatine arteries, or to tie the external carotid. In this way it is possible to draw backwards the great vessels of the neck, together with the vagus and spinal-accessory, while the arch of the hypoglossal nerve is drawn upwards. The superior laryngeal nerve and the superior thyroid artery remain beneath the lower edge of the wound. Those muscles which lie anteriorly and can be avoided must, in the interest of the swallowing mechanism, be preserved by working upwards along the inner surface of the jaw and of the internal pterygoid towards the mucous membrane. If, on account of adhesion or insufficient access, the muscles must be divided, then this is to be done in such a way that the innervation of the portions of the muscles which are spared is not interfered with. The posterior belly of the digastric and the stylo-hyoid are divided as near as possible to the hyoid bone, because their nerves of supply (from the facial) enter posteriorly; and for the same reason the stylo-glossus is divided near the tongue, the lingual and glosso-pharyngeal nerves which lie on it being avoided. The stylo-pharyngeus is divided in the region of its pharyngeal insertion, and the hyo-glossus and mylo-hyoid muscles, as far as may be necessary, at their insertions into the hyoid bone. The pharyngeal wall is now exposed, the superior constrictor above, the inferior constrictor below. When the lingual and glosso-pharyngeal nerves are involved, they must of course be divided.

The upper part of the pharynx, however, is only thoroughly exposed to view by the *osteoplastic resection of the lower jaw* which we have already mentioned (page 73), or, expressed more exactly, by the oblique division of the jaw (from behind internally and above, obliquely forwards, outwards, and downwards) at the anterior border of the masseter, the ascending ramus being then drawn forcibly upwards and the horizontal portion forwards.

If the new growth, involving the tongue and pharynx, has extended to the *fold between the upper and lower jaw*, it is best, after dividing the lower jaw as above described, and separating from the bone the soft parts (masseter externally, internal pterygoid internally), to *disarticulate and remove the ascending ramus* by twisting off the capsule of the joint and the external pterygoid muscle. In this way subsequent closure of the jaws is most certainly prevented. The inferior dental nerve and artery are divided, the latter requiring a ligature.

If the *lower part of the pharynx* behind the larynx is to be exposed, the muscles of the tongue and pharynx along with their nerves, as well as the branches of the external carotid artery, are all left undisturbed. The pharynx is opened below the superior laryngeal nerve, between it and the superior thyroid artery (which may have to be divided), the incision reaching from the larynx upwards as far as the origin of the descendens noni from the hypoglossal at the anterior aspect of the carotid. In order to expose the lowest part of the pharynx, it is necessary to add to the normal incision (which is then correspondingly shortened posteriorly) a longitudinal incision, extending downwards along the anterior border of the sterno-mastoid muscle. When the lymphatic glands are also extensively diseased, it is better to perform the operation at two sittings; that is to say, first to excise the glands down to the pharynx, and it may be also to the œsophagus, and then to postpone opening the pharynx for a few days until the wound has granulated, in order that the fresh wound may not become infected with pharyngeal contents.

43. Subhyoid Pharyngotomy (Fig. 39). To expose the entrance to the larynx when the disease is confined to this region, the simplest plan is to pass in from the front. An incision is carried transversely through skin and platysma along the body and the greater cornua of the hyoid bone so as to expose the whole length of the bone. When the skin is tense and the fat abundant, a vertical incision descending to the middle of the thyroid cartilage must be added. Some branches of the anterior jugular veins are ligatured. The hyoid arteries and veins which course along the hyoid bone are left uninjured at the upper part of the wound. The muscles attached to the lower border of the hyoid bone (sterno-hyoids, omo-hyoids, and farther out, the thyro-hyoids) are now divided, but some of the fibres of the latter should if possible be left intact.

The thyro-hyoid membrane is now exposed, the middle portion

projecting forwards as a distinct ligamentous band, whilst the lateral portions are thin and membranous. The thyro-hyoid membrane, and the subjacent mucous membrane between the base of the tongue and the upper border of the epiglottis are now divided along the lower border of the hyoid bone. It is not permissible to cut too far away from the hyoid bone on account of the superior laryngeal nerves, which enter the larynx by piercing the lateral portions of the thyro-hyoid membrane. If these nerves are divided, the larynx is rendered insensitive, and an opportunity is given for the entrance into the larynx of food, mucus,

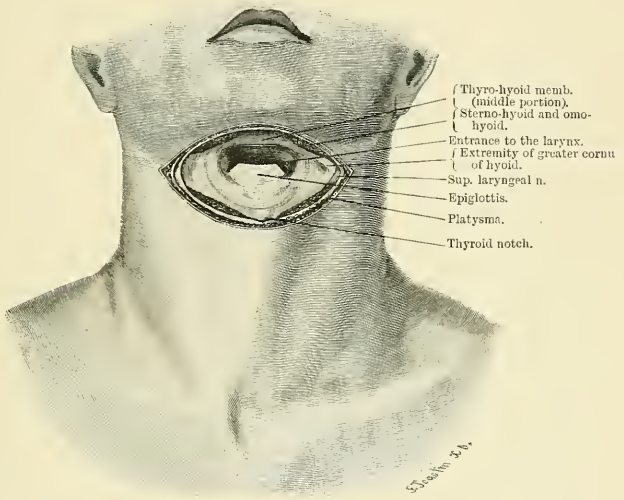

FIG. 39.—Subhyoid pharyngotomy.

and discharge from the wound. These foreign substances are not reflexly expelled by coughing, and thus dangerous septic pneumonia may arise.

The epiglottis which projects into the wound can now be seized with a sharp hook and drawn forwards, whereby a very good view of the opening of the larynx, especially of the neighbourhood of the arytenoid cartilages (the common seat of tubercle, carcinoma, etc.), and also of the lowest part of the pharynx, is obtained. As in laryngotomy, to allow of the operation being performed without interruption, the reflex excitability of the mucous membrane must be abolished by painting the surface with a 10 per cent solution of cocaine.

This method, introduced by LANGENBECK, is an operation which is

to be highly recommended for exposing the entrance to the larynx, and especially the septum between it and the pharynx, as it is not followed by any unforeseen functional disturbances.

As regards the *after-treatment* of the wound produced in pharyngotomy, it is to be borne in mind that we have to do with tissues previously infected, because the pharynx is not accessible to thorough disinfection. In ulcerations and ulcerating tumours it is desirable, therefore, to perform the operation in two stages: first, to dissect down upon the pharynx; then, having allowed the wound to granulate, to keep it thoroughly open by stuffing it with aseptic gauze. After three or four days the pharynx is opened and the tumour or ulcer excised, preferably with the thermo-cautery. Should circumstances prevent a double operation, then the chief point in carrying out the operation at a single sitting is to treat the wound by the open antiseptic method. The wound together with the pharynx is completely stuffed with carbolic gauze, squeezed out of 5 per cent carbolic, and changed every two hours. Necrosed areas are painted with tincture of iodine and rubbed over with iodoform or subnitrate of bismuth. If the carbolic should give rise to poisonous symptoms, thymol gauze wrung out of a 1 per cent solution of thymol is substituted.

It is obvious that under favourable conditions, as when the wound is so limited that it is possible to apply an accurate suture, especially to the wound in the mucous membrane, the attempt to secure healing of the pharyngotomy by first intention is occasionally justifiable, if iodoform is thoroughly rubbed into the wound surface in the pharynx. It is safer, however, at first merely to close the wound in the pharynx, and to apply a secondary suture to the external wound after forty-eight hours or later. Whenever the pharynx and the entrance to the larynx are to be plugged, *tracheotomy* must of course be performed. This is also indicated in order that the operation may be more comfortably performed, and it should be done at least three days before the main operation. When possible, a low tracheotomy should be performed, in order that the administration of the chloroform through the tracheotomy tube may not come in the way of the operation. The tracheotomy allows the trachea to be plugged in order to prevent the inspiration of blood and discharge from any ulcerated surface during the operation. When the interior of the larynx is intact, a small tampon is simply pressed against the false cords and glottis, otherwise a strip of gauze is introduced deeper downwards through the glottis. All complicated appliances for the purpose of plugging are less reliable.

H. ANTERIOR TRIANGLE OF THE NECK [1]

In passing deeply between the organs in the neck and the sterno-mastoid muscle, transverse incisions corresponding to the direction of cleavage of the skin are not always sufficient. It is often necessary to make a longitudinal incision, either mesially, or laterally along the sterno-mastoid.

44. Common Carotid Artery (Figs. 36 and 37). The common carotid artery passes vertically upwards in the shortest direction from the chest to the head. The incision to expose it runs transversely in the line of cleavage of the skin, at the level of the cricoid cartilage; the middle of the incision is at the anterior border of the sterno-mastoid, the direction of which corresponds to a line passing from the angle of the jaw to the sterno-clavicular articulation. The artery may be felt in its entire extent alongside of the trachea and œsophagus, and may be securely compressed against the vertebral column, preferably at the level of the cricoid, opposite which may be felt the projecting transverse process of the sixth cervical vertebra, the so-called carotid tubercle. The level of the cricoid cartilage is the seat of election for ligaturing the artery.

After dividing the skin and platysma, the *transverse superficial cervical nerve* is seen passing forwards over the sterno-mastoid from its posterior border (Figs. 37 and 38). The nerve is avoided, and the fascia is divided so as clearly to expose the muscular fibres of the sterno-mastoid, the anterior border of which is drawn outwards with a blunt hook, exposing beneath it the omo-hyoid muscle, which passes upwards and somewhat inwards. The artery is now sought for in the angle formed by the divergence of those two muscles. It is still covered by a second fascia, which at the same time forms the sheath of the vessel; on opening the sheath the artery is exposed. The descendens noni nerve passes downwards upon the sheath and gives off branches passing forwards to the muscles which ascend to the larynx. This nerve is carefully drawn inwards. Great care must be taken that the vagus, which lies close to the posterior surface of the artery, is not included in the ligature. It may here be remarked that this close apposition occasions symptoms of pressure upon the vagus (slowing of the pulse, dyspnœa, and syncope) when the artery has to be compressed. The internal jugular vein lies upon the antero-lateral aspect of the artery; the sympathetic nerve is behind it.

If the incision be prolonged somewhat backwards so as to expose the

[1] We regard this triangle as bounded above by the upper border of the thyroid cartilage, internally by the middle line of the neck, posteriorly by the anterior border of the sterno-mastoid from the level of the upper border of the thyroid cartilage to the sternum.

posterior border of the sterno-mastoid, the *spinal-accessory nerve* will be seen emerging from beneath it and the external jugular vein, and passing downwards and somewhat backwards towards the trapezius muscle.

45. Ligature of the Internal Jugular Vein (Fig. 37). The internal jugular vein may be ligatured at the same place as the common carotid artery. It lies upon the anterior and outer aspect of the common carotid. The indication for ligaturing it is, besides haemorrhage, the occurrence of thrombosis in its tributaries, especially in the lateral sinus, resulting from the extension of infective inflammations of the ear. The vein is very often ligatured also when it is adherent to tumours, as, for example, malignant goitres, or carcinomata and sarcomata of the lymphatic glands.

46. In the conditions above mentioned it may be necessary to **remove a portion of the Vagus Nerve** (Fig. 37). Unilateral division of this nerve does not endanger life, and indeed may not give rise to any symptoms whatever.

47. Ligature of the Inferior Thyroid and Vertebral Arteries (Fig. 40). Ligature of these two large branches of the subclavian artery is performed by means of an oblique incision which, beginning above the suprasternal notch, arches obliquely upwards and outwards over the sterno-mastoid. Recently we have often performed ligature of the *inferior thyroid artery* (recommended by WÖLFLER for goitres generally) for vascular goitres (*struma vasculosa*). A definite situation for exposing it is where it turns inwards behind the common carotid towards the posterior surface of the thyroid gland. It lies here horizontally upon the longus colli muscle covering the vertebral column, and to the inner side of the common carotid. To expose the artery, cut down as if about to expose the common carotid. The skin and platysma being divided, the anterior edge of the sterno-mastoid is exposed and drawn well outwards. The subjacent omo-hyoid, which now appears, is drawn downwards and inwards, as also is the sterno-hyoid, which lies to its inner side. The carotid artery, the internal jugular vein, and the vagus are all drawn outwards after freeing the inner aspect of the sheath. The dissection is now continued towards the vertebral column between the inner aspect of the carotid sheath and the border of the thyroid gland, covered by the sterno-thyroid muscle. The pulsation of the vessel can here be felt. The thyroid gland must be raised and drawn inwards. The artery is characterised by being arched with the convexity upwards, a course which is produced by the passage of the artery towards the middle line, to reach the place of attachment of the thyroid gland to the trachea. The *recurrent laryngeal nerve* passes upwards alongside the trachea, behind the gland and the inferior thyroid artery. The ascending cervical artery is given off at the point where the inferior thyroid turns inwards behind

the carotid. All hæmorrhage must be carefully arrested during the operation, in order that a good view of the parts may be obtained, and the recurrent laryngeal nerve (which is the main motor nerve for the larynx) thereby preserved from injury where it crosses behind the artery. The nerve usually crosses behind the bend of the artery and ascends upon the longus colli muscle, from whence it continues upwards

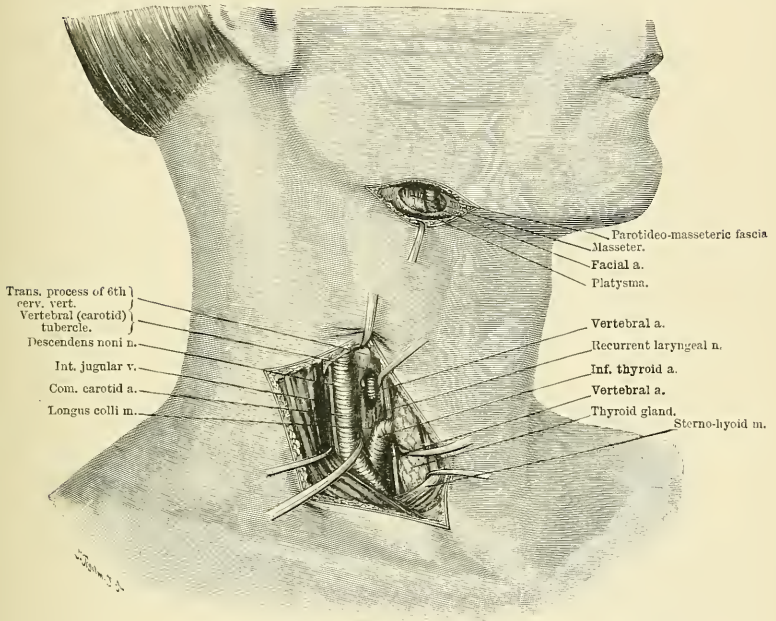

FIG. 40.—Ligature of the facial artery. Ligature of the inferior thyroid and vertebral arteries.

in the groove between the trachea and œsophagus to the lower border of the cricoid cartilage. The cardiac branches of the sympathetic must not be injured, nor indeed the trunk of the sympathetics, which often consists of two parts embracing the artery. When the thyroid gland is enlarged the fascia must be freely divided so that the gland may be raised and drawn towards the middle line with a large blunt hook-retractor; in doing this the inferior accessory thyroid vein is divided between two ligatures.

48. Vertebral Artery (Fig. 40). The operation for ligaturing the vertebral artery is similar to that for the inferior thyroid, but is more difficult, as the artery lies still deeper. It lies behind the prevertebral fascia, and is overlapped by the outermost fibres of the longus colli. The so-called *carotid tubercle* at the transverse process of the 6th cervical vertebra affords an excellent guide to the artery. The same tubercle is also made use of in tying the common carotid, hence its name. It is of no great significance, however, in ligaturing the carotid, but is very important in tying the vertebral, because the artery passes under it to enter the foramen in the corresponding transverse process. It would therefore be more to the purpose to speak of the projection as the *vertebral tubercle*. The artery passes towards the under surface of this tubercle. After drawing the sterno-mastoid outwards along with the large vessels, and the sterno-hyoid and sterno-thyroid inwards, the prevertebral fascia is divided above the arch of the inferior thyroid artery, when the vertebral artery will be felt ascending vertically upon and partly within the fibres of the longus colli, and disappearing at the lower surface of the transverse process of the 6th cervical vertebra. Externally lie the scalenus anticus, and upon it the *phrenic nerve* (Fig. 36), which descends from the outer border of the muscle across its anterior surface to enter the upper aperture of the thorax. Below the arch of the inferior thyroid artery the vertebral ascends almost vertically along with the recurrent laryngeal nerve.

49. Œsophagotomy. The œsophagus is opened from the left anterior triangle of the neck, because it projects to the left of the trachea. If it be desired to expose it on account of the presence of a tumour or a foreign body, the incision is the same as for ligature of the common carotid and inferior thyroid arteries, only longer. Langenbeck (according to whom Goursand in 1738 first performed the operation) recommends Guattani's incision at the edge of the sterno-mastoid. Frequently also an incision is made through the skin and platysma from the middle of the inner border of the left sterno-mastoid vertically downwards to the clavicle. After dividing the fascia, the sterno-mastoid is drawn outwards, the depressors of the larynx inwards, and the omo-hyoid is divided. The thyroid fascia is now divided, the gland itself is drawn inwards, and the large cervical vessels along with the descendens noni nerve are drawn outwards. The capsule of the thyroid is a part of the deep cervical fascia which is firmly blended laterally with the sheath of the large vessels. This fascia must be divided before access can be got to the œsophagus. Upon the anterior surface of the vertebral column is the longus colli muscle, and crossing it transversely, behind the common carotid, is the large inferior thyroid artery, which is to be divided between two ligatures. The red œsophageal tube now appears. Careful attention

must be directed to avoid the recurrent laryngeal nerve, which, if necessary, is to be drawn downwards and inwards with a small hook. The nerve ascends along the groove between the trachea and the œsophagus, so that the latter must be opened quite laterally, or towards its postero-lateral aspect. It is difficult to open it in the collapsed condition. It should therefore be expanded by the introduction of a bougie or an olive-shaped probang. The patient is fed through a soft œsophageal tube which is passed from the wound and retained in position; the wound is stuffed with iodoform gauze. After a simple incision into the œsophagus, closing it with a suture may be tried, in which case the main wound must be left completely open. GUSSENBAUER has incised deeply situated fibrous strictures of the œsophagus through an œsophagotomy wound in the neck.

In 1873 CZERNY first performed *œsophagectomy for carcinoma* with success. Since then, a great many excisions have been performed, mostly along with excision of the larynx, the thyroid gland, the internal jugular vein, or lymphatic glands. MIKULICZ recorded ten cases in 1886, and ROSE a successful case in 1887. We have performed the operation several times. When the œsophagus has to be divided very low down, it must occasionally be held up and fixed for a few days with a pair of catch artery forceps.

50. Retropharyngeal Space. The opening from without of *retropharyngeal abscesses* resulting from cervical caries or cervical adenitis is indicated in order to avoid bursting internally, which may lead to suffocation. The incision is made parallel to the posterior border of the sterno-mastoid. After dividing the fascia and exposing the edge of the muscle, and avoiding the transverse and descending superficial cervical nerves, the muscle is drawn forwards with a blunt hook, and if necessary nicked. The dissection is now continued with a blunt instrument down to the abscess, behind the large vessels of the neck, which along with the pharynx and larynx are pushed forwards by the abscess. The spinal-accessory nerve, which passes obliquely downwards and backwards beneath the sterno-mastoid, is to be avoided. BURKHARDT has recommended cutting down at the anterior border of the sterno-mastoid and then passing inwards close to the larynx. A *retro-œsophageal abscess* may be opened by the same operation.

These abscesses, which result chiefly from tubercular disease of the vertebral column and the lymphatic glands, are dangerous not only through obstructing the entrance to the larynx, but also on account of the possibility of asphyxia if the abscess be allowed to burst. Evacuation from without has the advantage of establishing no communication with the interior of the pharynx and œsophagus, and of affording the possibility of keeping the wound aseptic.

Laryngotomy and Tracheotomy

Cutting down mesially in the anterior triangle of the neck is the most frequent operation which one is called upon to perform for the purpose of opening the larynx and the trachea.

51. Tracheotomy (Fig. 41). In the great majority of cases where

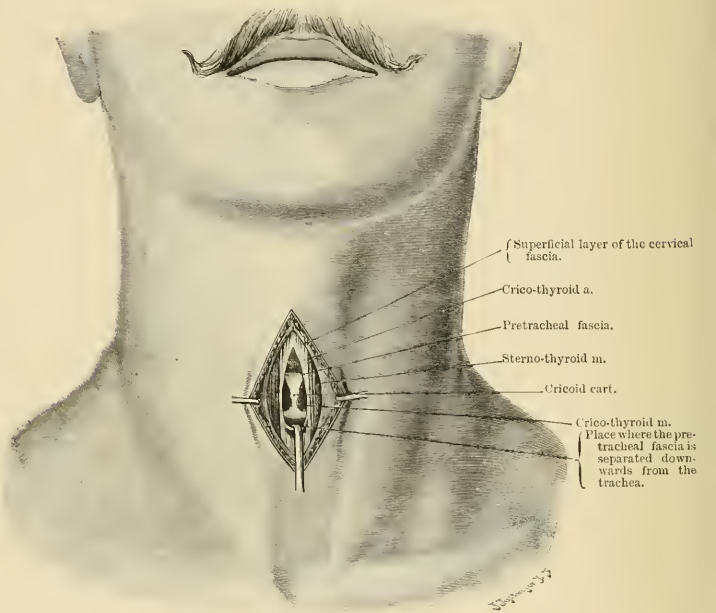

FIG. 41.—High tracheotomy.

we are compelled to perform this operation very rapidly, *crico-tracheotomy* is the safest, and attended with least hæmorrhage.

The uppermost tracheal rings are often covered by a well-developed thyroid isthmus, at the upper and lower edges of which are the large transverse communicating branches between the thyroid veins. They receive branches which descend from the pyramidal process of the thyroid, when this is present, while ascending to the process are vessels from the crico-thyroid branches of the superior thyroid artery, so that arterial branches may also cross the middle line at the upper border of

the isthmus. At the posterior surface of the isthmus the inferior laryngeal branch of the inferior thyroid artery is seen passing upwards. Below the isthmus are the large and constant inferior thyroid veins, which descend vertically one on either side of the mesial plane, and along with them the occasional thyroidea ima artery. All those vessels may be avoided if crico-tracheotomy be performed. In dealing with children, especially when aggravated dyspnœa is present (in diphtheria, for example), it is advantageous to begin the incision directly over the thyroid cartilage. After dividing the skin and fascia, the adjacent edges of the sterno-hyoid muscles are exposed and drawn apart with blunt hooks. Bleeding veins are seized with artery forceps. The lower border of the cricoid cartilage, which may almost invariably be distinguished readily, is now felt for, and the fascia over it is grasped with forceps, while a small incision is made into it in the manner recommended by Bose. In young children, and when there is marked dyspnœal ascent and descent of the larynx, it is an advantage to place a small sharp hook in the exposed lower edge of the cricoid to fix it, and then to thoroughly separate the thyroid isthmus along with the fascia and veins downwards from the front of the trachea with a director (Kocher's blunt dissector), and to keep them held downwards with a retractor. The trachea is now rapidly penetrated with a sharp-pointed knife immediately above the retractor, and the trachea and cricoid are divided in an upward direction. The edges of the tracheal wound are at once seized with fine hooks and drawn asunder.

If sufficient room is not got by crico-tracheotomy, or if it be desired to place the tracheal wound farther from the larynx, the skin incision must be prolonged downwards to the suprasternal notch, and the fascia divided exactly in the middle line below the isthmus. The inferior thyroid veins remain uninjured, as they descend vertically one on either side of the mesial plane. After dividing the pretracheal fascia, the trachea itself is reached (in adults at considerable depth from the surface) without further use of the knife, by pulling the transverse veins of the thyroid isthmus forcibly upwards with blunt hooks, whilst the transverse communicating branches of the anterior jugular veins, situated above the suprasternal notch, are pulled equally forcibly downwards (*low tracheotomy*). If necessary, an aneurism needle may be introduced between the trachea and the thyroid isthmus (previously separated from the trachea by a blunt instrument, and drawn forwards), in order that the latter may be divided in the middle line between two firmly tied ligatures. This is to be preferred when the trachea is to be freely exposed.

In tracheotomy performed preliminary to laryngotomy or laryngectomy, the lower operation is preferable, because it gives a clear field for the second operation. Such preliminary tracheotomies, moreover, should if possible be performed several days before the chief operation.

Inferior tracheotomy, however, is always a more difficult operation, because the trachea is here much deeper, and there is no palpable guide to it to take the place of the cricoid cartilage.

52. Laryngotomy and Laryngectomy. Opening into the larynx is definitely indicated in intralaryngeal malignant growths; it may be necessary also in relatively simple tumours, as laryngeal papillomata, in ulcers, and in infective diseases, as laryngeal tuberculosis. To expose the larynx mesially is a comparatively simple operation. An incision is carried in the middle line from the hyoid bone downwards to the upper part of the trachea. The following vessels are divided: the hyoid branch of the lingual artery, upon the hyoid bone; the crico-thyroid branch of the superior thyroid artery, upon the crico-thyroid membrane; a transverse branch of the superior thyroid to the pyramidal process of the thyroid gland; numerous veins, some superficial, being transverse connections between the two anterior jugulars, others situated under the fascia. All these vessels are ligatured. After dividing the skin and fascia, the muscles, which ascend from the sternum to the larynx and hyoid bone, are drawn aside. The middle portion of the thyro-hyoid membrane is divided above the thyroid notch, and the perichondrium is divided downwards along the angle of the thyroid. A grooved director is now introduced behind the angle of the thyroid cartilage, which is then split or divided from without, and the alæ are drawn apart with a pair of sharp double hooks before dividing the mucous membrane.

It must be laid down as a rule that a preliminary lower tracheotomy is to be performed several days before this operation, in order to ensure free breathing during and after the operation, and to admit of the introduction of small soft sponges from above, for the purpose of preventing the passage of blood and mucus into the respiratory tract.

Instead of simply plugging above the tracheotomy tube from the *laryngeal wound*, it may be done from the *tracheotomy wound* by tying a soft flat perforated piece of sponge to the lower part of the tracheotomy tube. To prepare this umbrella-like tampon-canula, the lower end of the tracheotomy tube (provided with a groove running round it close to its lower end) is introduced through an aperture cut in the centre of a flat piece of sponge, which is securely fixed to the tube by a silk thread tied round along the groove. In this way the sponge forms a shallow funnel which receives and keeps back the blood. The canula is very easily introduced.

In order that a good view of the interior of the larynx may be obtained, it is necessary to induce complete anæsthesia, and, at the same time, to abolish the cough reflex. In addition to giving plenty of chloroform, therefore, the parts should be painted with a 10 per cent solution of cocaine. In this way malignant new growths can be got at and removed with safety. Should there be too little room, the epiglottis is split in an upward direction. The cricoid cartilage, when it can be spared, gives

a very good support for accurately bringing together the alæ of the thyroid.

53. Laryngectomy. When the whole larynx is diseased, necessitating *laryngectomy*, a transverse incision along the lower border of the hyoid bone is added to the above longitudinal incision. This transverse incision is the same as that employed in the operation of subhyoid pharyngotomy. It is here especially desirable to perform a preliminary inferior tracheotomy several days before the operation. If the neck is too short, as is often the case in emphysematous patients, this is not practicable, and the tracheotomy tube must be introduced at the operation. In such cases the operation is performed as follows. An incision is carried in the middle line from the hyoid bone downwards to 3 cm. ($1\frac{1}{4}$ in.) below the cricoid cartilage; it divides the skin and fascia, passes down to the thyroid and cricoid cartilages, and exposes the upper border of the isthmus of the thyroid. The fascia (suspensory ligament of the isthmus) is divided at the lower border of the cricoid, and, together with the isthmus and the superior transverse communicating veins along its upper border, is separated from the trachea, and pushed downwards with the blunt dissector. The cricoid and upper rings of the trachea are now divided mesially, as in crico-tracheotomy, as far downwards as possible. Should the isthmus reach very high, it is freed at its upper and lower borders to allow a director to be pushed beneath it, and is then divided between two strong silk ligatures in order that the trachea may be divided farther down.

Next comes the introduction of the tampon-canula provided with the sponge "umbrella." It is not necessary to secure it, as the sponge is safely fixed in the trachea. A transverse incision is now carried along the hyoid bone through the skin and fascia, and the upper ends of the anterior jugular veins, one on either side of the middle line, are ligatured. The sterno-hyoids, the omo-hyoids, and part of the subjacent thyro-hyoids are divided at their insertions close to the hyoid bone, and the latter drawn up with a strong sharp hook. The strong middle portion of the thyro-hyoid membrane attached to the posterior surface of the hyoid bone is divided transversely, as is also the subjacent mucous membrane, whereby the upper part of the epiglottis can be seized with a sharp hook and drawn forwards.

If the epiglottis is found to be healthy, it is split mesially; if diseased, it is cut round beyond the diseased tissue. The thyroid cartilage is split mesially downwards into the tracheal wound. Bleeding is arrested from the wound edges, and the laryngeal and pharyngeal mucous membranes are painted with a 10 per cent cocaine solution to abolish the coughing and swallowing reflexes. The limit of the new growth is now defined and the tissues divided beyond it: this is best done by first dividing the mucous membrane with the thermo-cautery.

If the whole larynx is diseased, the mucous membrane is carefully

divided, first along the epiglottis and the arytenoid cartilages, and then along the larynx or trachea below the tumour, according to its extent. It is only now that the outer surface of the larynx is exposed. The muscles which cover its lateral and anterior aspects (sterno-thyroids, thyro-hyoids, and crico-thyroids) are as far as possible preserved, but if diseased they must be removed. The cartilages are now exposed, and are removed either partially or entirely, according to the extent of the disease. If the mucous membrane upon the posterior surface of the cricoid is healthy and movable, it is retained. The dissection is

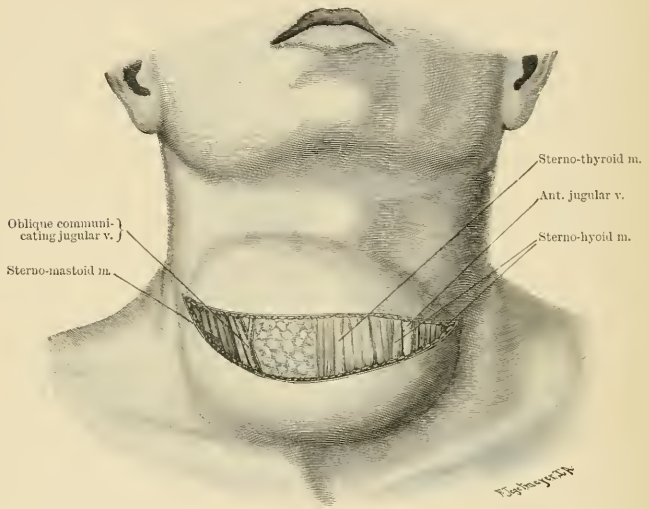

FIG. 42.—Excision of a right-sided goitre by a transverse curved incision.

continued down to the lower limit of the disease, and the healthy trachea or cricoid cartilage is divided transversely.

The anterior wall of the pharynx or œsophagus is sewn upwards as far as possible in order to re-establish the septum between the respiratory and alimentary passages.

For the after-treatment, a simple canula is substituted for the tampon-canula, because the sponge soon becomes soaked with secretion. No sutures are introduced, but the entire cavity is stuffed with carbolic gauze, which is changed every two hours. The patient is fed through an œsophageal tube. It will be seen from a paper published by Dr. OTTO LANZ[1]

[1] See LANGENBECK's *Archiv*, vol. xliv. part i.

that by this treatment we had lost only one case out of twelve, and since then we have had equally good results.

54. Excision of the Diseased Thyroid Gland (Figs. 42 to 46). The excision of a goître is an operation which in many instances is very easy, but in certain cases is attended with great difficulty. The latter is the case in goîtres which are but slightly movable, especially in malignant, in inflammatory, and in diffuse colloid goîtres. Here it is difficult to give a general description of the procedure to suit all cases, as modifications may be called for in individual operations. The

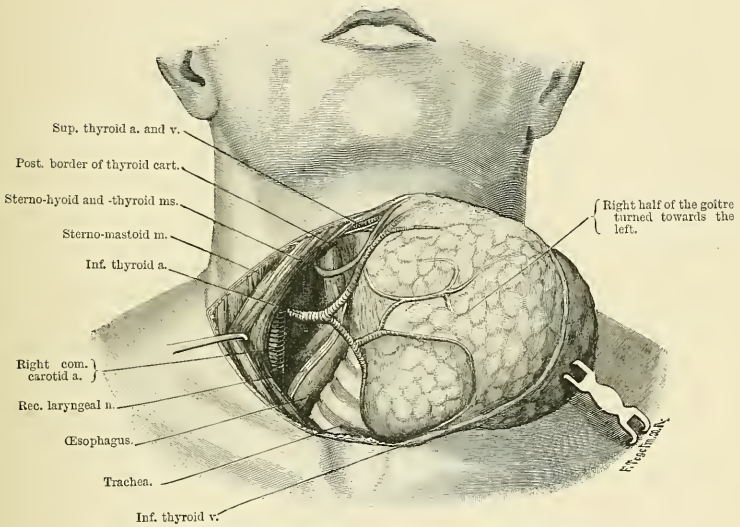

FIG. 43.—Excision of a right-sided goître by a transverse curved incision. The goître has been dislocated and rotated to the left.

most important point is to make a very large skin incision. It may also be necessary to divide the sterno-laryngeal muscles as well as part of the sterno-mastoid. In ordinary cases division of the muscles is not permissible, as it gives rise to marked contraction in the region of the wound, which results in an ugly deformity.

When it is important to avoid disfigurement, the *transverse curved incision* (our collar-incision, Figs. 42 and 43) is to be recommended as the best. It falls along the line of cleavage of the skin, and gives rise later to an almost imperceptible scar. A transverse curved incision with the concavity directed upwards is carried across the most prominent part

of the swelling, and is prolonged farther upwards and backwards over the sterno-mastoid upon the side on which the disease is most marked. The incision is placed at a higher or lower level, as may be required—in goitres situated low down, quite at the lower part of the neck. The skin and platysma are divided, and the vertical branches (often several

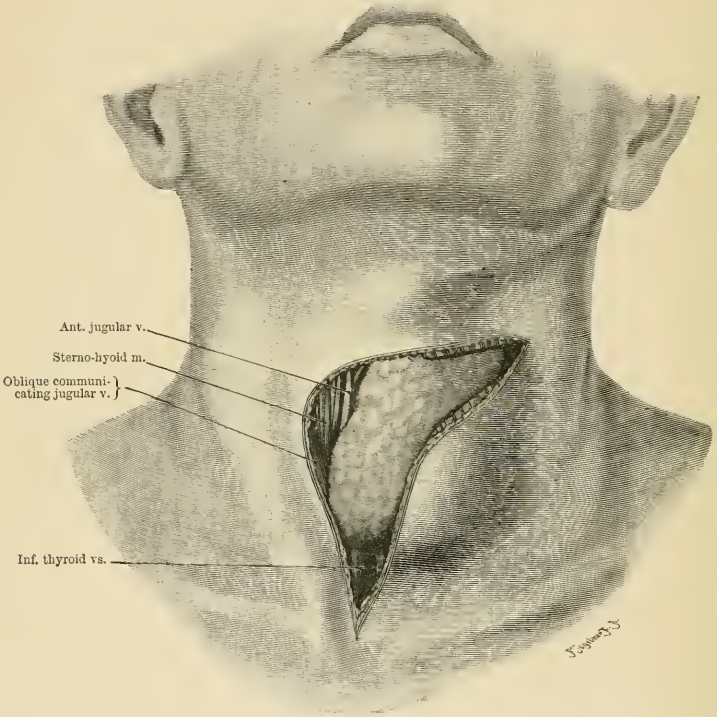

FIG. 44.—Excision of a left-sided goitre (difficult cases) by an angular incision.

in number) of the anterior jugular veins are cut across between two ligatures. The external jugular veins can generally be avoided at the extremities of the incision. After dividing the fascia, the fibres of the sterno-mastoid and of the sterno-laryngeal muscles—the latter often spread out in a very thin layer—are exposed. By cutting across the sterno-laryngeal muscles, and by nicking the anterior border of the sterno-

mastoid, the tumour may be freely exposed. If, however, it be desired to avoid division of the muscles, then the transverse curved incision is not so convenient as the *angular incision* which we originally recommended, and which, for the sake of those who have had less experience, we will make the starting-point of our description.

The angular incision is commenced over the prominence of the sterno-mastoid at the level of the thyroid cartilage, and extends almost transversely in the direction of the skin creases as far as the middle line of the neck, and from thence vertically downwards to the suprasternal

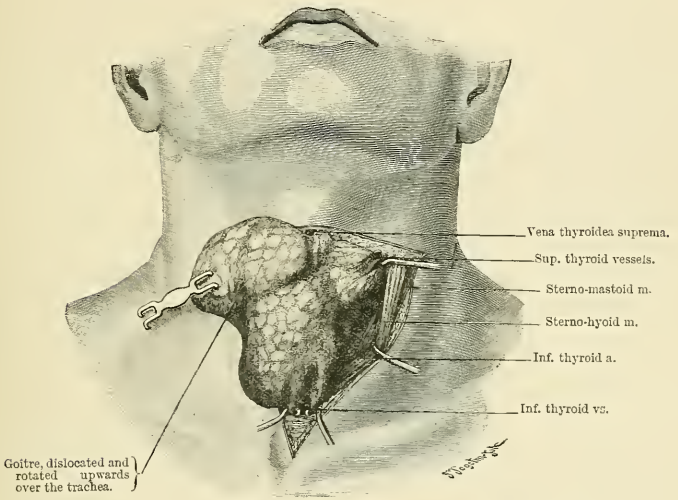

FIG. 45.—Excision of a left-sided goitre by the angular incision. Dislocation of the goitre over to the sound side, and ligature of the main vessels (inf. thyroid veins, inf. thyroid arteries, vena thyroidea suprema, and superior thyroid artery and vein).

region. In deeply situated goitres it is prolonged on to the manubrium sterni. The transverse portion of the incision divides the skin and the platysma (Fig. 44). In dividing the superficial fascia towards the middle line, the large anterior jugular vein and the oblique vein (a branch lying along the anterior border of the sterno-mastoid and connecting the anterior and external jugular veins) are divided between two ligatures. The external jugular which crosses the sterno-mastoid is usually avoided. After sufficiently dividing the superficial fascia, the fibres of the sterno-mastoid are exposed at the outer part of the horizontal incision. The anterior border of the muscle is thoroughly freed, so that

it may be drawn well aside with blunt hooks. At the middle portion of the horizontal incision the muscular fibres of the sterno-hyoids and sterno-thyroids are clearly exposed, and the fascia drawn upwards. The fascia which connects the sterno-laryngeal muscles is now divided mesially, and the vein lying transversely above the suprasternal notch is ligatured. The inner edges of the last-mentioned muscles are freed, and the finger is introduced under them so that they (especially the insertion of the sterno-thyroid) may be partially divided at their upper ends, the vessels which are divided being ligatured. These muscles also are now drawn aside with blunt hooks.

A very thin layer of connective tissue, the *outer capsule of the goître*, is now all that lies upon the gland. This must be carefully divided and stripped to either side from the surface of the goître with the blunt dissector. In doing this, transverse veins (the superior and inferior accessory veins) are often seen stretching from the capsule to the goître; they must not be torn, but are to be carefully divided between two ligatures. The outer capsule of the goître, along with the muscles already mentioned, can now be sufficiently drawn aside, to admit of the finger being passed round the outer edge of the goître and pushed carefully beneath its under surface.

Next follows the *dislocation of the goître* (Figs. 43 and 45), a very important step, which greatly facilitates its further separation, and at once gives relief to the difficult breathing when there is a tendency to compression of the trachea. The dislocation must be done carefully, so that no vessels are torn; especially must the inferior thyroid artery and its branches be uninjured, because they are transversely stretched and often drawn forwards during the dislocation.

The chief vessels are now ligatured. When the goître can be sufficiently shelled out, the inferior thyroid artery and the accompanying veins can be seen and tied behind the tumour as they arch from without inwards towards the area of attachment of the growth to the trachea (Figs. 43 and 45). On account of the close relation of the recurrent laryngeal nerve to the inferior thyroid artery, the latter must be very carefully isolated and inspected before it is ligatured, and for the same reason the vessel should not be cut through, but should be surrounded by a temporary ligature. If this procedure is too difficult, it must be left to the last.

Now turn to the upper or lower pole of the tumour, according as one or other is more easily isolated. When it is not a case of deeply seated goître, that is, when the lower horn does not reach into the thorax, then the very large inferior thyroid vein, which in the region of the goître divides into several branches, is isolated at the lower pole. It is put on the stretch by drawing forward the goître, and can be divided between two ligatures without fear of injury to the neighbouring structures.

To expose the superior thyroid artery and vein, the blunt dissector is used above the isthmus at the inner border of the upper horn—after a branch of the superior thyroid vein (especially large when the pyramidal process is well developed), which ascends towards the middle line, has been isolated and divided between two ligatures. We now pass upwards to the inner border of the upper horn, which is grasped between the finger and thumb; and while the outer capsule of the goître and the remaining soft parts are well drawn upwards so as to stretch the superior thyroid vessels, the director is passed under them, and they are then tied and divided.

Next follows the isolation of the isthmus. At the upper and lower borders of the isthmus is a superior and an inferior communicating vein, and higher up here and there an artery to the pyramidal processes. When possible they are isolated and ligatured. The director can now be slowly inserted between the trachea and the isthmus, and the latter surrounded by a strong silk ligature, which is tightened up while the isthmus is being cut across. The fingers of the left hand are now pushed under the goître, which is at the same time drawn downwards and raised from the surface of the trachea. The posterior border of the gland is still firmly attached to the trachea, and during its complete separation from it the recurrent laryngeal nerve may, in spite of every care, be injured, more especially as it passes beneath the lower border of the larynx. It is desirable, therefore, to cut through the tissue of the goître parallel to the surface of the trachea, ligaturing the small vessels, *thus leaving behind a portion of the posterior part of the capsule of the goître as a protection against injury to the recurrent laryngeal nerve.* When dealing with an encapsulated thyroid nodule the posterior portion can often be cleanly stripped off from the thyroid tissue (the internal thyroid capsule); in other cases, however, the latter must be cut through until a sufficient distance from the trachea is reached at which the division may be made without danger.

In cases where a single, though still a large, colloid or cystic nodule is to be removed, the question of *enucleation* has to be considered. This plan, which was recommended by Porta, has been brought into general use by Professor Socin. It appears to be a far simpler method than excision. *A priori*, injury to the recurrent laryngeal nerve is out of the question. Lastly, the important healthy gland tissue is in this way best preserved.

The method consists in the complete exposure of the surface of the goître in the way already described, and preferably by means of the transverse curved incision. The healthy thyroid tissue (inner capsule) which covers the nodules is then incised, and the latter are shelled out. There are cases, especially cystic, where this procedure is easily carried out. The rule, however, is that the shelling-out is attended with a much greater amount of hæmorrhage than excision, which can generally be

performed almost bloodlessly. In enucleation it is occasionally necessary to arrest the severe hæmorrhage by plugging.

If hæmorrhage is to be avoided, the main vessels must first be ligatured in the way we have described. It will be seen, therefore, that enucleation has no advantage over excision, either as regards simplicity or preservation of normal thyroid tissue. We therefore employ *enucleation-resection* for all cases of isolated nodules (Fig. 46). When, however, the disease is diffuse, unilateral excision is alone indicated.

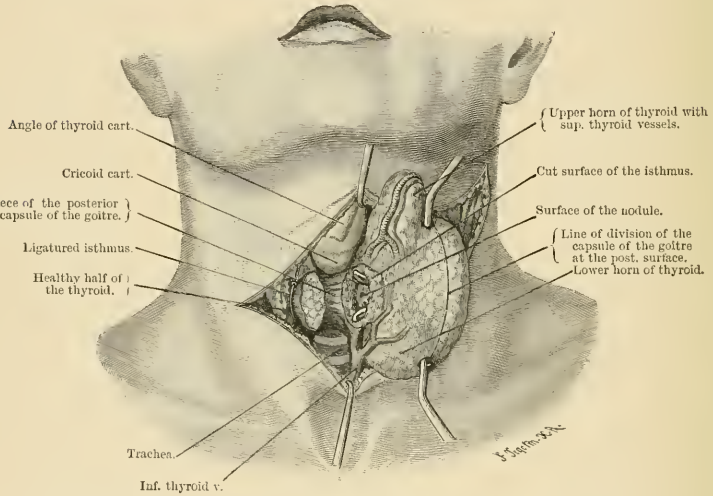

FIG. 46.—Enucleation-resection of an hypertrophied nodule from the left lobe of the thyroid. The left lobe of the thyroid has been brought out of the skin incision, the isthmus ligatured and cut across, the cut surfaces of the latter drawn apart so as to bring into view the surface of the colloid nodule. The line of division of the capsule of the goitre is indicated on the anterior surface by the two aneurism needles, on the posterior surface by the interrupted line (which has been placed too far forward).

We perform enucleation-resection as follows :—A transverse or angular incision is made according to the difficulty of the case. The goitre is freely exposed, and when possible luxated in the same way as in excision, ligature of the chief vessels, however, being omitted. After luxating the goitre, the isthmus is ligatured and divided in the manner previously described. Access is got to the nodule through the cut surface left after dividing the isthmus, whereby the inner border of the nodule is exposed. The blunt dissector is now passed upwards and downwards between the

surface of the nodule and the inner thyroid capsule (the overlying gland tissue), and the latter is divided between two ligatures along the line indicated by the two aneurism needles in Fig. 46. The anterior surface of the inner capsule which remains connected with the nodule towards the upper and lower cornua can now be separated, and the nodule enucleated with the finger at its upper and lower part. From here the posterior surface of the nodule may now be freed until a fair extent of the posterior part of the inner capsule is separated, which is then divided vertically with the scissors upon its posterior surface, so that the cut opens into the line of section running between the upper and lower horn on the anterior surface. In Fig. 46 the line indicating this posterior vertical incision has been drawn too far forward; as a rule it is made nearer the seat of attachment of the gland to the trachea.

55. Resection of a Goître. One of the modified forms of enucleation-resection may be necessary in diffuse colloid degeneration of both lobes of the thyroid.

This operation is especially difficult. It requires a long transverse incision prolonged upwards on both sides, free transverse division of the muscles, and when possible ligature of the main vessels both above and below on the one side and either above or below on the other side. Whenever practicable, first the one and then the other half is to be sufficiently luxated. It is only in this way that, in performing partial removal of both sides, the thyroid tissue can be satisfactorily cut across without producing too extensive hæmorrhage; numerous artery forceps are applied to the cut surface as the tissue is divided.

In inflammations and malignant growths, the overlying muscles on the anterior surface must be removed along with the tumour.

In all goîtres in which excision is performed on account of severe difficulty of breathing, anæsthesia should be avoided in consequence of the danger of asphyxia and subsequent pneumonia from inspiration of the tracheal and bronchial secretions, which are often abundant. Ether is therefore contra-indicated. Slight morphia narcosis, or still better merely local anæsthesia with cocaine, is best in such cases.

56. Innominate Artery (Fig. 47). This is the nearest artery to the heart which it is permissible to ligature. The operation is a dangerous one on account of secondary hæmorrhage. As a rule therefore the simultaneous ligature of the two chief branches in which the recurrent circulation takes place is preferable. These two vessels are the common carotid and the vertebral arteries.

The pulsation of the innominate artery can be felt at the suprasternal notch. To ligature it an oblique incision is made from the junction of the middle and lower thirds of the anterior border of the right sterno-mastoid to the anterior surface of the manubrium sterni. After dividing the skin and fascia, the sternal origin of the sterno-mastoid is separated from the sternum. Two veins are to be avoided, namely, the transverse

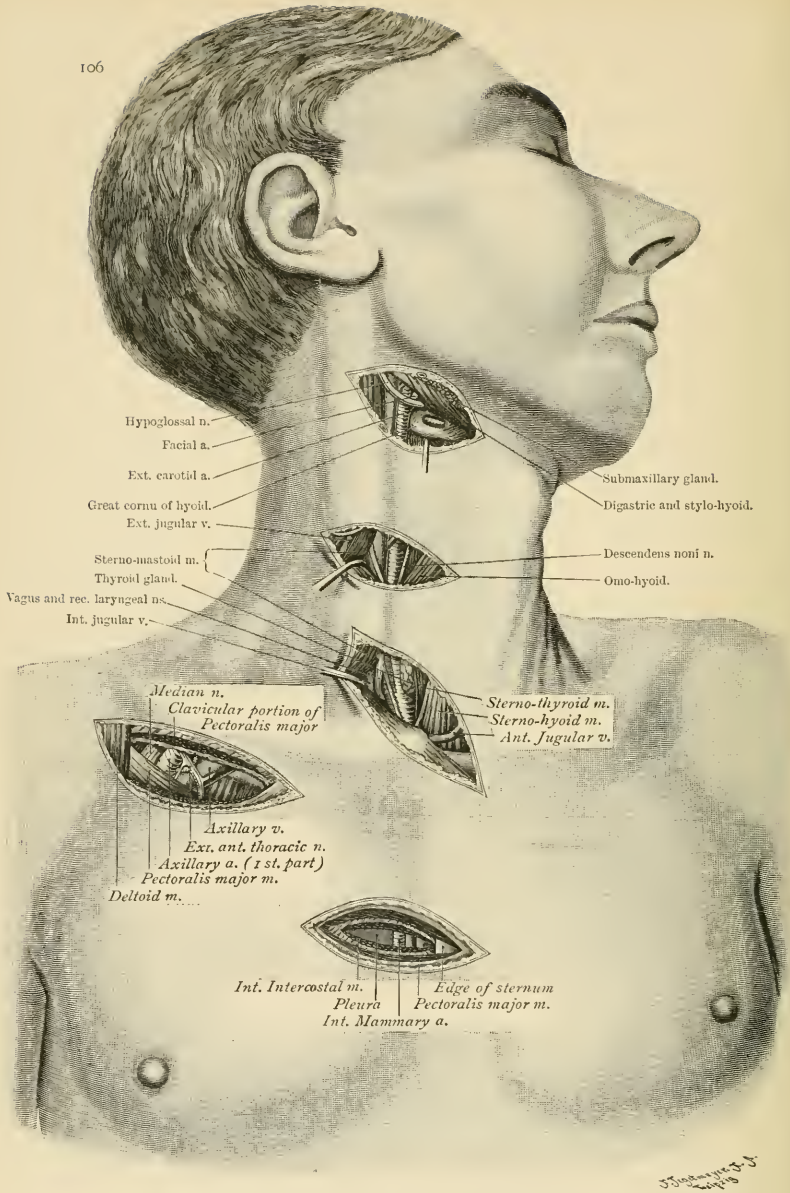

FIG. 47.—Ligature of the lingual artery above the greater cornu of the hyoid. Ligature of the common carotid at the level of the cricoid cartilage. Ligature of the innominate artery. Ligature of the first part of the axillary artery. Ligature of the internal mammary artery.

vein connecting the two anterior jugulars at the suprasternal notch, and the transverse terminal portion of the anterior jugular behind the origin of the sterno-mastoid. The outer borders of the sterno-hyoid and sterno-thyroid muscles, which are attached to the posterior surface of the manubrium sterni, are drawn inwards along with the branches of the descendens noni nerve, and the second layer of fascia is then divided. In this way the common carotid artery is reached behind the sterno-clavicular articulation. The right inferior thyroid vein is ligatured and divided. After passing between the sterno-mastoid and the last-named muscles, the carotid is followed downwards to its junction with the subclavian, below which the trunk of the innominate is ligatured, the pleura which lies posterior and external being avoided. The left innominate vein crosses from left to right in front of the artery. The vagus nerve which descends in front of the subclavian artery, the recurrent laryngeal nerve which winds round it, and the phrenic nerve lie at its outer side, and are left uninjured.

J. THE INFERIOR LATERAL TRIANGLE OF THE NECK

This triangle is bounded by the clavicle, the sterno-mastoid, and the trapezius. The surgery of this region is simpler than that of the upper lateral triangle. It is here that the great vessels and nerves pass to the arm, and that many of the branches of the subclavian artery and vein are to be found. The floor of the triangle is formed by the 1st rib and the 1st intercostal space, together with the lateral muscles of the neck, especially the scaleni.

The *normal incision* for this region corresponds to the line of cleavage of the skin, and is almost transverse, passing from the origin of the sterno-mastoid at the clavicle outwards and slightly upwards to the edge of the trapezius. This incision is employed in ligaturing the subclavian artery, and is described with that operation.

57. Subclavian Artery (Fig. 48). Arising behind the manubrium sterni, the artery arches over the pleura and apex of the lung and above the 1st rib between the scalenus anticus and medius; it then passes beneath the middle of the clavicle between the subclavius and the serratus magnus to the outer surface of the thorax. It may be securely compressed at the outer border of the scalenus anticus muscle.

To ligature the artery a transverse incision is made a finger-breadth above the clavicle, beginning over the clavicular portion of the sterno-mastoid and passing outwards and slightly upwards to end at the anterior border of the trapezius. After dividing the skin and platysma, the clavicular branches of the descending superficial cervical nerve are

seen and must be divided. They pass over the clavicle to supply the skin over the shoulder and chest down to the level of the 2nd rib. The external jugular vein, which lies along the posterior border of the sterno-mastoid and finally winds round it to join the internal jugular, is to be avoided. It is dangerous to open this vein, because it is

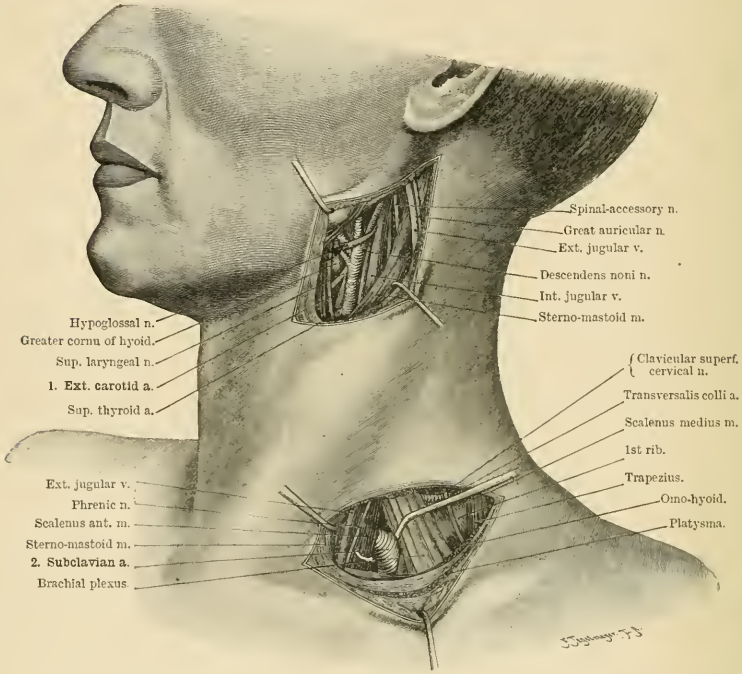

FIG. 48.—Ligature of the external carotid with the origins of the lingual, facial, and occipital arteries. Ligature of the subclavian artery.

kept patent where it passes through the fascia, and air may be drawn into it during inspiration. In case it cannot be drawn inwards, a double ligature is to be applied before it is divided. After dividing the fascia, the omo-hyoid muscle appears at the inner angle of the wound, and passes upwards and inwards in the fatty tissue which contains the lymphatic glands of the triangle. The muscle is drawn either upwards and outwards, or downwards and inwards. In the fatty

tissue lie the suprascapular artery running outwards behind the clavicle, and the superficial cervical artery running backwards and upwards. Above the latter, but under the deep fascia, is the larger transversalis colli artery, which passes backwards either upon or through the cords of the brachial plexus. After the adipose tissue has been removed, the large nerve cords of the brachial plexus (covered by a thin fascia) appear between the scaleni, and pass almost vertically downwards under the clavicle. The relation of the artery to the plexus is very definite. The scalenus anticus is now followed downwards in front of the plexus to its attachment to the scalene tubercle (*tubercle of Lisfranc*) of the 1st rib, behind which lies the artery overlapped by the nerves. Internal to the scalenus anticus is the bulbous portion of the internal jugular vein; in front of the artery, and separated from it by the scalenus anticus, is the subclavian vein. The phrenic nerve descends into the chest upon the anterior surface of the scalenus anticus. The thoracic duct ascends from the chest into the neck close to the scalenus anticus, and opens into the angle between the subclavian and internal jugular veins.

Of the three branches of the subclavian artery already mentioned, two pass inwards in front of the scalenus; the third, namely the transversalis colli, passes outwards. Ligature of the vertebral and inferior thyroid arteries has already been described.

For ligature of the internal mammary artery, see page 110.

In relation to the operation of stretching the *brachial plexus* it should be remembered that, of the three trunks, the uppermost (formed by the 5th and 6th cervical nerves) gives origin especially to the musculo-cutaneous and median nerves; the middle (from the 7th cervical nerve), which is situated more posteriorly, to the musculo-spiral and circumflex nerves; the lowest (from the 8th cervical and 1st dorsal nerves), which lies most deeply and in contact with the artery, to the ulnar and to the fibres of the musculo-spiral and median nerves, which go to the muscles of the forearm and hand (Fig. 38).

58. The Spinal-Accessory Nerve (Fig. 38). The spinal-accessory enters the posterior triangle of the neck after appearing from beneath the middle of the posterior border of the sterno-mastoid muscle. It lies quite superficially beneath the deep fascia, and passes obliquely downwards and backwards to the under surface of the trapezius. In stretching or dividing it for spasmodic conditions, the nerve is exposed by making a transverse incision across the middle of the posterior border of the sterno-mastoid muscle.

59. The Transverse and Descending Superficial Cervical Nerves and **60. The Great Auricular Nerve** may be secured by the same incision as for the spinal-accessory (Fig. 38).

The short branches, as well as the trunks of the brachial plexus, can be exposed through the normal incision for the posterior triangle. The former diverge from one another, and pass backwards, outwards, and

forwards over the thorax. The *nerve to the levator anguli scapulæ and rhomboids* pierces the scalenus medius and passes backwards; the *suprascapular nerve* passes outwards through the suprascapular notch to the supra- and infraspinatus muscles; the *circumflex nerve* passes through the quadrilateral opening (bounded by the teres muscles, the long head of the triceps, and the humerus) close to the outer wall of the axilla, to the under surface of the deltoid, the teres minor, and the skin upon the posterior aspect of the upper arm; the *three subscapular nerves* descend upon the posterior wall of the axilla to supply the teres major, the subscapularis, and the latissimus dorsi muscles; the *posterior thoracic nerve* passes along the inner wall of the axilla to supply the serratus magnus; lastly, the *anterior thoracic nerves* embrace the first part of the axillary artery and pass forwards to supply the two pectoral muscles.

K. BACK OF THE NECK

The surgery of the suboccipital region has already been dealt with along with the back of the head (see occipital artery and the great and small occipital nerves).

No large vessels and nerves lie in the lower part of the back of the neck. Incisions are often required in this region in inflammations, especially boils and carbuncles; they may be made without fear of injuring important structures.

For the operation of opening the spinal canal, see Vertebral Column.

L. THE THORAX

Diseases of the mamma, of the pleura, and of the ribs afford the chief indications for operating in the region of the thorax; seldom diseases of the lungs themselves, and least frequently diseases of the pericardium. Of the larger arteries, the internal mammary, the intercostals, and above all the first part of the axillary and its branches must be dealt with.

61. Internal Mammary Artery (Fig. 47). It supplies the inner surface of the anterior wall of the thorax, and gives off perforating branches to the skin. It lies with its accompanying vein upon the pleura, separated from it only by a very thin layer of fascia and lower down also by the triangularis sterni muscle. Anteriorly are the costal cartilages and the intercostal muscles.

It is ligatured by making a transverse incision in those intercostal spaces opposite which the sternum is narrowest, preferably therefore the second. The incision is carried from the middle line of the sternum transversely outwards between the costal cartilages. After dividing

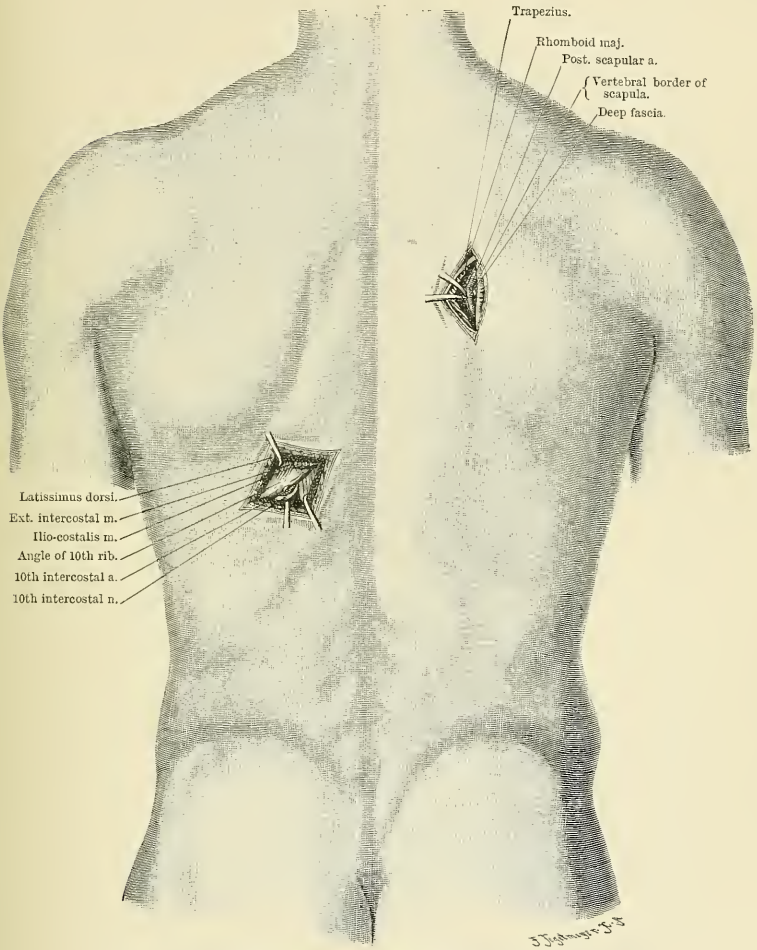

FIG. 49.—Exposure of the 10th rib and the 10th intercostal artery and nerve. Ligature of the posterior scapular artery.

the skin, fascia, and pectoralis major, the oblique fibres of the anterior intercostal membrane are seen passing downwards and inwards; beneath

this very thin and often interrupted membrane are the muscular fibres of the internal intercostal, which pass downwards and outwards with a well-marked fascia upon their under surface. After these are divided, the artery is seen descending upon the pleura about $\frac{1}{2}$ to 1 cm. from the border of the sternum. The vein lies to its inner side.

62. Intercostal Artery (Fig. 49). The chief branch of this artery runs between the two intercostal muscles at the lower border of the rib, a smaller branch running along the upper border of the subjacent rib. The artery is not easily ligatured, because it lies hidden under the projecting lower margin of the rib. The oblique fibres of the external intercostal muscle are divided close to the rib and drawn downwards; the nerve, and with it the artery, can now be drawn down out of the groove of the rib, and an aneurism needle is carefully passed round the artery. To secure the vessel with greater safety, a piece of the overlying rib may be resected subperiosteally.

63. The Intercostal Nerve lies between the intercostal muscles below the artery. It may be exposed in the same way as the artery—for the purpose of stretching it in intercostal neuralgia.

64. Amputation of the Mamma, with clearing out of the Axilla (Fig. 50). The removal of the mamma alone is a very simple operation, and may be done by means of a curved incision with the concavity upwards along the lower border of the gland. The gland is shelled out subcutaneously, by separating it from the fascia covering the pectoralis major up to its upper border, and then dissecting it off from the skin. We have often performed the operation in this way in diffuse adenoma and multilocular adeno-cystoma (*maladie kystique*). In lipoma, circumscribed adenoma, and fibroma situated in the deeper part of the mamma, the latter may be thrown upwards and the tumour shelled out from its under surface without removing any of the healthy gland along with it. When the tumour is situated superficially, a simple radial incision is preferred, the skin, superficial fascia, and a thin layer of gland tissue being divided, and the tumour shelled out.

Malignant tumours call for very different treatment. *Carcinoma* spreads along the lymphatics from a primary nodule to the rest of the mammary gland and its surroundings, and from thence along the large lymphatic trunks to the lymphatic glands. We have to deal here, therefore, not merely with the removal of a cancerous nodule, which is often no larger than an ordinary adenoma, but with the thorough removal of all suspicious tissues, together with the lymphatic vessels and lymphatic glands. We shall describe and illustrate this operation below, as the further course of the disease depends upon the way in which it is performed, and therefore the responsibility of the surgeon is great. Every experienced surgeon knows that the results of operations for carcinoma, including carcinoma of the mamma, are, thanks to improved technique, infinitely better now than formerly.

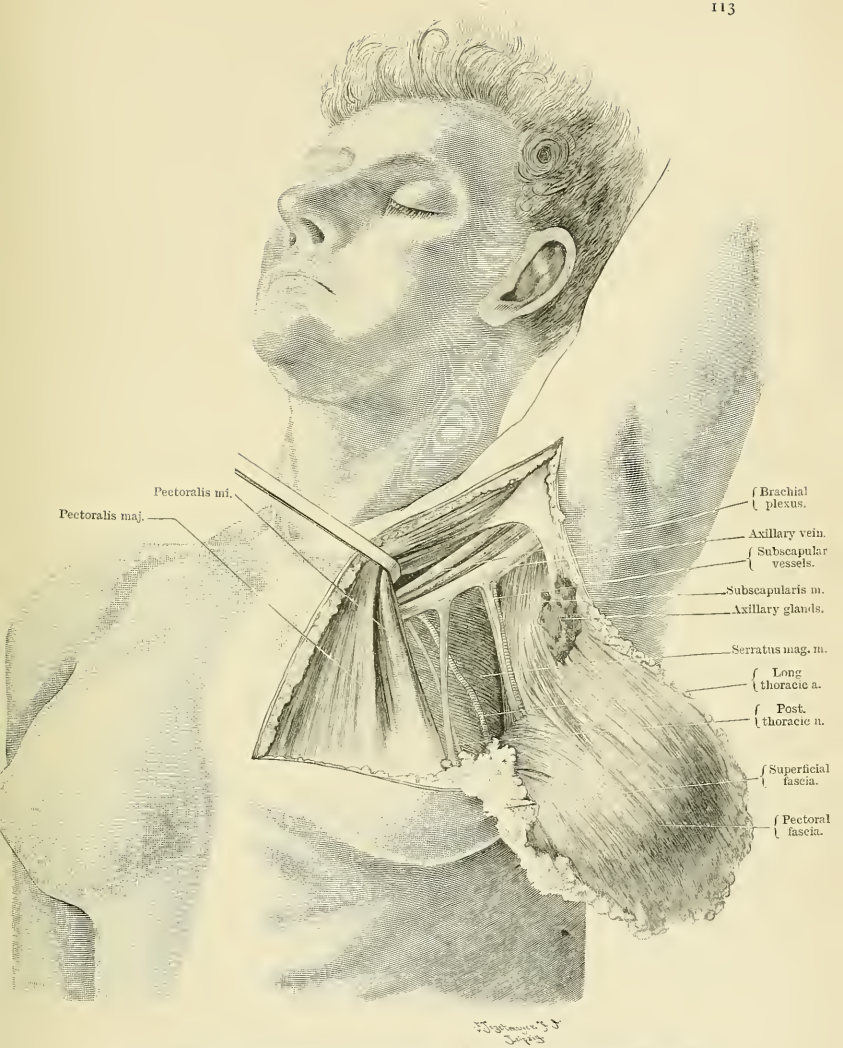

FIG. 50.—Amputation of the mamma, with clearing out of the axilla. The mamma, together with the axillary fat and lymphatic glands, is dissected off from the pectoral muscles, the serratus magnus, and the subscapularis, and thrown downwards. The axillary vein and nerves are exposed together with the long thoracic and subscapular vessels, and the posterior thoracic and long subscapular nerves.

It is customary in excising the mamma to make the first incision along the lower border of the gland, but this is opposed to the principle which we have heard LANGENBECK lay down in his clinique, namely, always to begin the operation at the side from whence the greatest blood supply is derived, because the main vessels can then at once be seized and if necessary ligatured, the other incisions being then attended with less hæmorrhage. But here a still more definite principle is present for making the incision at the upper border of the gland first, and it is this. In order that the axilla may be cleared of all its fat, glands, and fascia high up, and also that it may be rendered as accessible as possible both upwards and downwards, the incision is carried along its anterior fold, and the fascia peeled downwards and backwards together with the tissues connecting the axillary contents with the mamma. It is therefore absurd to remove the gland from below and to clear out the axilla from above, as both should be removed in direct connection with the lymphatic vessels lying between. The incision recently recommended by RYDYGIER, which we had already frequently employed, avoids this mistake.

We recommend the following procedure. An incision is made, with its convexity upwards, transversely above the areola, and two finger-breadths beyond the place where the tumour is adherent to the skin. It reaches outwards as far as the outer margin of the mamma, *i.e.* as far at least as the axillary border of the pectoralis major, and from thence upwards along it to where it overlaps the biceps. The skin is drawn upwards by means of sharp hook-retractors, and the gland tissue with its overlying fat is exposed as far as the uppermost limit of the organ, where the pectoral fascia is divided and the fibres of the muscle laid bare. Several vessels (branches of the superior thoracic and acromio-thoracic arteries) in the skin and subcutaneous tissue require ligature.

The posterior surface of the mamma together with the pectoral fascia is now pulled well downwards, and separated from the fibres of the pectoral muscle. When the muscle is involved, it is cut through above, transversely to its fibres, and in certain circumstances is detached along with the pectoralis minor from the costal cartilages and intercostal muscles nearly up to the lower border of the gland, some bleeding occurring from the perforating branches of the intercostal and internal mammary arteries.

The ends of this incision are now connected by a transverse upwardly concave incision placed below the tumour and the areola, and extending from the axillary border of the pectoral muscle to the sternum. The skin is drawn upon with sharp hooks and dissected downwards and outwards as far as the margin of the gland, which is then detached internally and inferiorly with a few snips of the scissors. It is now attached only at its "tail," which consists of fatty connective tissue enclosing the lymphatic vessels, and extends upwards into the axilla upon the serratus magnus and edge of the pectoral.

Instead of dividing the tail, the fascia is detached from the edges of both pectoral muscles backwards towards the lateral aspect of the chest and the axillary vessels. At the arm the tendinous portion of the biceps is first exposed, and beside it the large brachial nerves which cover the artery. The large axillary vein lies below and upon the axillary aspect of the nerves, a smaller vein also lying upon them. By clearing the edge of the vein, its branches are very distinctly seen, and may be ligatured at their origin when necessary.

The vein is now followed upwards under the pectoralis minor as far as the clavicle, the adjacent fatty tissue being drawn downwards. The finger is introduced up to the clavicle to ascertain if any glands can be felt in the interval between the pectoralis major and minor. The outer borders of both pectorals are to be exposed as far as the outer surface of the serratus magnus, and the vessels which appear (branches of the long thoracic) are to be drawn upon and ligatured.

By detaching the fascia from the serratus magnus the remaining prolongation of the mamma is separated along with the fascia as far as the external oblique muscle of the abdomen, and likewise the prolongation of the mamma upwards along the pectoral muscles. After having divided the intercosto-humeral nerves to the arm, and having ligatured and divided the long thoracic artery and vein, the dissection reaches the anterior surface of the scapula covered by the subscapularis muscle. The posterior thoracic nerve, which accompanies the long thoracic artery upon the outer surface of the serratus magnus, may be avoided. The large subscapular artery and vein are met with upon the subscapularis muscle accompanied by the long subscapular nerve, which should be preserved if it can be freed from the surrounding fatty tissue and glands; the subscapularis muscle itself is thoroughly cleaned. Lastly, the axillary fat and glands and the axillary tail of the mamma are separated from the posterior fold of the axilla and from the posterior part of the margin of the wound.

A drainage-tube is introduced between the scapula and thorax through a small incision at the posterior axillary line, the large wound being then closed by a continuous suture. When the edges of the wound cannot be brought together, the raw surface should be at once covered with strips of cutis-epidermis shaved off from the stretched skin of the thigh (THIERSCH).

65. Opening the Pleural Cavity. Puncture of the pleural cavity has in recent times been extensively employed in the medical wards for diagnostic as well as therapeutic purposes. If merely a hypodermic needle or the canula of an aspirator be used, it may be pushed through any intercostal space, provided care be taken that the skin and soft parts be firmly pressed into the intercostal space by the fingers of the other hand in order to make sure of the proper place for puncturing. This is all the more necessary when a very large trocar is used for the purpose

of establishing puncture-drainage (BÜLAU). In this case the puncture should be made at the upper border of the lower rib, as with a large instrument there is no danger of injuring the small artery which lies here. The large intercostal vessels and nerves which run at the lower margin of the ribs must be avoided, and it must be remembered the space is often pretty narrow. A 1 per cent sterilised solution of cocaine should be injected at the point of puncture. In using a large trocar it is desirable to make a small skin incision to facilitate its introduction.

When a large opening is desired, the proper method is to resect a piece of rib subperiosteally, and to pass in through the periosteum, because by this form of thoracotomy there is no risk of injuring the neighbouring structures, and it is only in this way that a sufficiently large and permanent opening can be made into the pleural cavity.

66. Resection of the Ribs. An incision is carried through skin and muscle down to the bone, midway between the upper and lower borders of the rib, no large vessels or nerves being divided. The periosteum is incised and carefully separated with an elevator from the outer and inner surfaces of the rib, and the exposed portion is removed by means of a suitable pair of bone forceps.

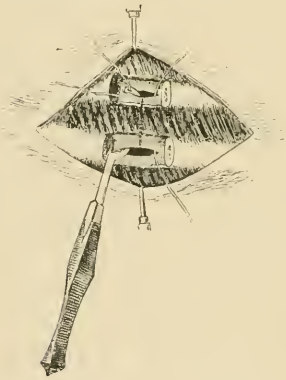

FIG. 51.—Making a free opening into the thorax by resecting portions of two ribs.

Behind the periosteum is the pleura, from which it is separated by the very thin intrathoracic fascia. These three layers are incised in the direction of the rib. In doubtful cases the presence of the exudate may be previously ascertained by an exploratory puncture.

Very often resection of one rib is not sufficient. In this case a portion of the rib above is removed through the same incision by drawing the skin well upwards, the pleura being opened in the same way as before. A threaded aneurism needle is now introduced, first at the outer and then at the inner extremity of the lower opening, and is passed each time beneath the intervening tissues of the intercostal space and out again at the extremities of the upper pleural opening, so as to apply two ligatures to the vessels along with the pleura and muscles. The two pleural openings are now united by a vertical incision between the ligatures, thus making a horizontal I shaped opening.

When a permanent drain is to be provided, the opening should be made at the lowest part of the cavity. In the mammary line this is

done by removing the cartilage of the 6th rib; in the lateral region the right pleura will still be opened by removing the 9th rib, and the left by removing the 10th rib; posteriorly in the scapular line (on both sides) by removing the 12th rib. A preliminary puncture should never be made at these lowest limits, because the diaphragm may be immediately subjacent to the wall of the chest. It is better therefore in the first instance to open the pleural cavity in the region where one is quite certain of finding fluid, *i.e.* where its presence has previously been ascertained by puncture, or by aspiration with an exploring syringe. After a free opening has been made, a probe or the finger is introduced to ascertain the deepest part of the cavity, over which a second opening may then be made by resecting a piece of rib. In this way provision is made for syringing out the cavity through two openings.

67. Exposure of the Convex Surface of the Liver through the Diaphragm (Fig. 52). An incision is carried obliquely forwards from the anterior axillary line between the 6th and 7th (or 7th and 8th) ribs, which are then exposed by dividing the aponeurosis of the external oblique muscle of the abdomen and detaching its fibres from the ribs. Portions of the 6th and 7th ribs are now resected in the manner already described (page 116), and the soft parts of the corresponding portion of the 6th intercostal space are removed, after they have been ligatured in two places and dissected off the thin subjacent intrathoracic fascia. When the two layers of the pleura are united, the muscular fibres of the diaphragm will be seen running obliquely downwards, and after dividing them the peritoneum and the convex surface of the liver are exposed. When the two layers of the pleura are not united, only the parietal layer should be divided, and their adhesion brought about by slight cauterisation, or simply by keeping the wound open for four to eight days by a dry iodoform dressing. After adhesions have formed, the diaphragm is divided.

68. Resection of a Larger Area of the Wall of the Chest. Extensive excisions of the chest wall are called for in empyema with collapse of the lung. Closure of the abscess cavity is here a mechanical impossibility in consequence of the rigidity of the wall. The operation is also performed for new growths, especially for chondromata and sarcomata of the ribs which have invaded the pleura. The operation goes by the name of ESTLANDER'S operation, although individual extensive resections had previously been performed and published (DE CERENVILLE). Several ribs can easily be resected from a single long incision running parallel to them. When a larger portion of the chest wall is to be removed in one piece, a flap must be made. For this purpose two different incisions may be recommended. (1) An incision passing obliquely downwards and backwards from the anterior fold of the axilla across the lateral aspect of the chest, between the attachments of the external oblique muscle of the abdomen anteriorly and the serratus magnus and

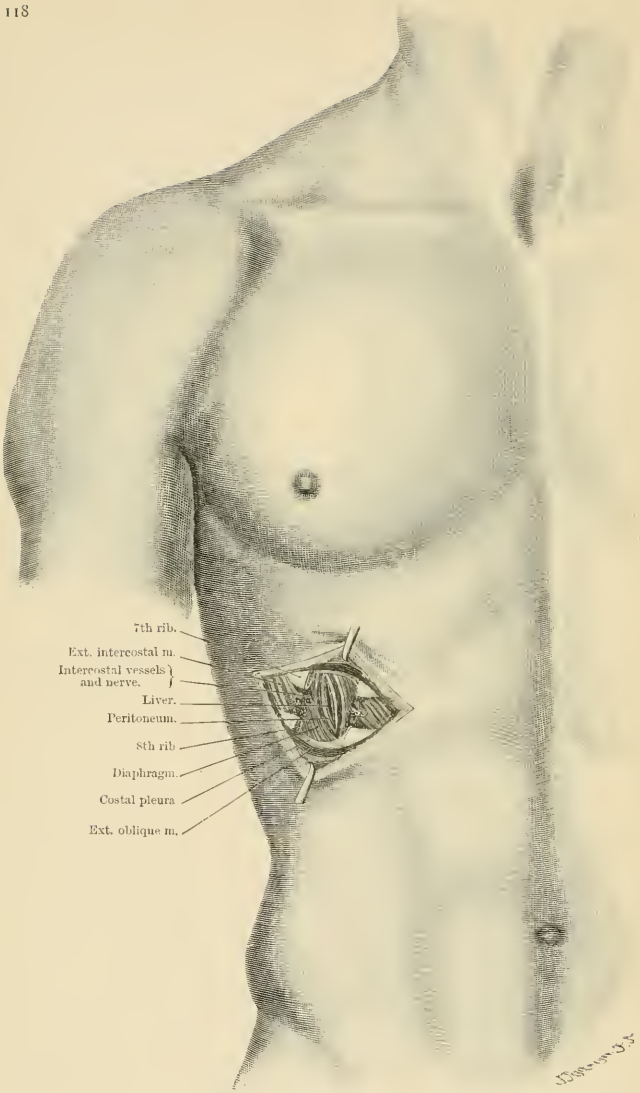

Fig. 52.—Exposure of the convex surface of the liver through the 7th intercostal space.

latissimus dorsi posteriorly. To this incision is added an oblique one parallel to the rib at the desired level. (2) An incision extending vertically along the edge of the extensors of the back down to the angles of the ribs. The tendinous part of the latissimus and part of the trapezius and serratus posticus inferior are divided. This incision corresponds to the interval between the muscles and to the frontier of their nerve distributions. If necessary a second incision may be carried forwards from it along one of the ribs.

69. Operations on the Lung. The lung may be exposed in the same way as the pleural cavity. This may be done at any place where abscesses, cavities, or new growths (exceptionally) in the lung itself afford indications for surgical interference. When the disease has not already given rise to adhesion of the lung to the pleura, this condition must be brought about artificially before incising it, either by cauterisation, or by directly fixing the affected part of the lung to the chest wall.

To open cavities at their most frequent seat, namely, the apex of the lung, proceed as follows. Carry an incision outwards from the inner end of the 1st intercostal space parallel to the clavicle. The skin, fascia, pectoralis major, and both intercostals are divided, but the internal mammary vessels internally, and the axillary vein externally, must not be injured. The periosteum having been divided at the lower border of the 1st rib and carefully detached, the lower two-thirds of the rib is resected, leaving a bridge towards its inner border so as not to injure the large vessels lying upon the rib. The position of the cavity is ascertained by an exploring syringe, and a small incision is then made through the pleura, and widened with forceps.

M. THE BACK

70. Ligature of the Posterior Scapular Artery (Fig. 53). An incision is made from a little outside the vertebra prominens, obliquely outwards and slightly downwards towards the shoulder. It passes over the place where the superior angle of the scapula can be felt. The skin, fascia, and trapezius are divided parallel to the fibres of the muscle, whereby the upper border of the rhomboideus minor is exposed, running from above downwards and outwards. Externally is the thick belly of the levator anguli scapulæ descending from the neck to be attached to the angle of the scapula. By pulling this muscle outwards, the artery will be found upon its under surface passing backwards from the transversalis colli artery. Upon the thorax lie the upper part of the ilio-costalis muscle internally, the insertion of the scalenus posticus superiorly, and the ribs and intercostal muscles externally. At the level of the middle of the infraspinous fossa the artery will be found by making an incision along the inner border of the scapula. At the upper angle of the

incision is the oblique lower edge of the trapezius muscle. On detaching the rhomboideus major from the scapula, the artery will be seen upon the under surface of the muscle, running parallel to the border of the scapula.

71. Suprascapular Nerve. An incision is carried upwards and inwards through the skin and fascia from the root of the acromion towards the vertebra prominens. The trapezius is divided in the direction of its fibres. The supraspinatus muscle is separated from the spine of the scapula up to the suprascapular notch, where the nerve will be found lying upon the bone.

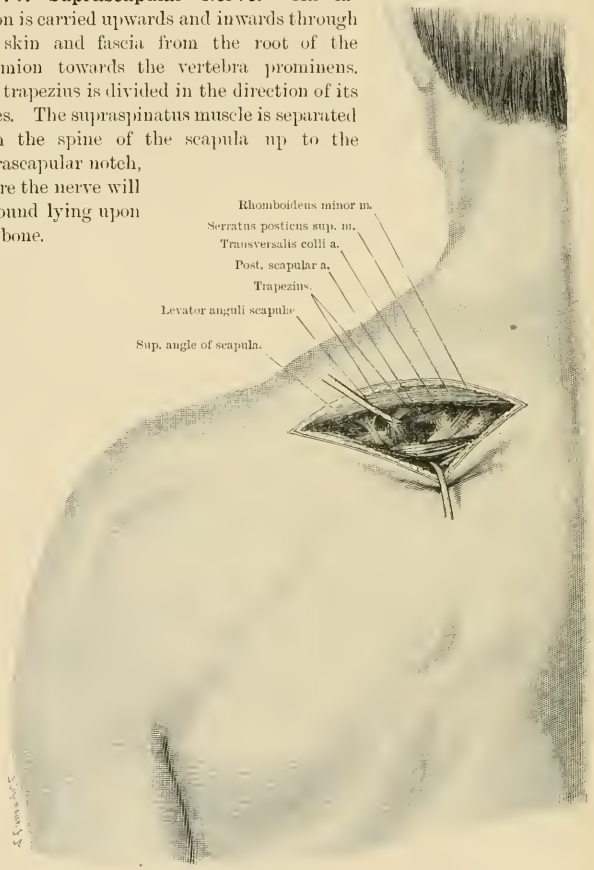

FIG. 53.—Ligature of the posterior scapular artery.

72. The Dorsalis Scapulæ Artery from behind. The incision is made along the upper border of the latissimus dorsi, which can be

defined by palpation a little behind and above the posterior axillary fold. After dividing the skin and fascia, the upper borders of the latissimus dorsi and teres major come into view, and the lower border of the teres minor is seen at the axillary border of the scapula. The artery will be found at the inner border of the long head of the triceps by exposing the lower margin of the teres minor two finger-breadths below the humerus.

73. Opening the Posterior Mediastinum. The question of opening the posterior mediastinum may have to be considered for the purpose of extracting foreign bodies from the œsophagus, possibly for the removal of a circumscribed carcinoma of the œsophagus, and lastly for opening abscesses in the posterior mediastinum (for example, after perforation of the œsophagus, or in the case of a suppurating lymphatic gland).

The operation has been investigated by QUENU and HARTMANN (Soc. de Chir., Feb. 1891). They recommend passing in from the left side, in spite of the aorta and intercostal arteries, because the pleura extends much farther towards the right in the form of a pouch behind the œsophagus. After making an incision midway between the middle line and the inner border of the scapula, the trapezius and rhomboids are divided and the sacro-lumbalis is drawn aside. The ribs are then exposed, and after resecting the 2nd to 5th, the pleura (along with lung) is separated towards the middle line.

74. Opening the Spinal Canal. The brilliant operations of HORSLEY have shown what excellent results can be attained, even in very advanced cases, by removing the pressure upon the spinal cord caused by tumours; and other surgeons have produced effects no less satisfactory by the removal of pressure caused by fractures and dislocations of the vertebræ or by the opening of abscesses.

The operation is performed in the following manner. A long median incision is made over the vertebral spines, and the muscles on either side (semispinales and multifidæ spinæ) are separated with the knife close to the bone. The strong fascia covering the muscles may if necessary be nicked transversely. The exposed spines are cut through at their bases with bone forceps, and removed together with the interspinous ligaments. The laminæ are removed by first dividing the ligamenta subflava transversely close to their upper and lower edges, and then snipping through the laminæ on both sides, and levering them out one after the other until the spinal cord is sufficiently exposed. The fatty tissue is separated. The large spinal veins are cut across after being ligatured on either side, and the dura is divided in the middle line. The dura is of course not opened when it is merely a case of pressure from a displaced or fractured vertebra, or an extradural tumour or abscess.

In cases in which the dura has been opened, it is to be accurately sutured. Complete primary union should result within forty-eight hours.

N. LUMBAR REGION

75. Nephrotomy and Nephrectomy (Fig. 54). The normal incision for the lumbar region is best illustrated by that employed to expose the kidney. Nephrotomy is performed for the purpose of fixing a wandering kidney to the skin and fascia; in opening the pelvis and calyces of the kidney in hydro- and pyo-nephrosis; in renal calculus; and for tumours of the kidney. Nephrectomy is performed for the removal of the whole kidney in cases of tumour, and in extensive renal disease resulting from calculi, inflammation, or tuberculosis. The same incision may be employed to expose the ureter.

The proper line of incision extends from over the prominence of the sacro-lumbalis muscle, in the angle between it and the 12th rib, obliquely downwards, forwards, and outwards as far as the axillary line. The incision divides the skin and subcutaneous tissue, the strong lumbar fascia, and the muscles arising from it, viz. the latissimus dorsi and the subjacent serratus posticus inferior. The outermost digitation of the latissimus appears as a broad flat mass. The serratus posticus forms a thin muscular layer where it overlies the sacro-lumbalis, but beyond it the fibres pass obliquely upwards and outwards, forming a still thinner layer, which is not always well enough developed to be distinctly recognised. The edge of the sacro-lumbalis may either be nicked or drawn forcibly inwards. When a larger incision is made, the posterior border of the external oblique muscle of the abdomen, which descends from the last rib at the anterior angle of the wound, is divided transversely for a short distance, as also are the subjacent fibres of the internal oblique, which ascend obliquely upwards and forwards. Beneath the sacro-lumbalis, and occupying the interval between it and the nicked edges of the oblique abdominal muscles, is the strong, glistening, transversely striated lumbar fascia, which gives origin to fibres of the transversalis abdominis muscle. In *nephroraphy* it is only necessary to divide the latissimus dorsi and the lumbar fascia between the outer border of the sacro-lumbalis (under which is the quadratus lumborum) and the posterior edges of the oblique abdominal muscles, the muscles themselves being left uninjured. After dividing this fascia, the edge of the quadratus lumborum is seen passing almost vertically upwards parallel to the margin of the sacro-lumbalis, beyond which it projects. The last dorsal nerve appears at the lower border of the 12th rib, and passes obliquely downwards and forwards, sometimes beneath and sometimes over the edge of the internal oblique. The ilio-hypogastric nerve (from the 1st lumbar) extends downwards and outwards from (in the prone position) beneath the edge of the quadratus.

The outer edge of the quadratus may either be nicked or drawn

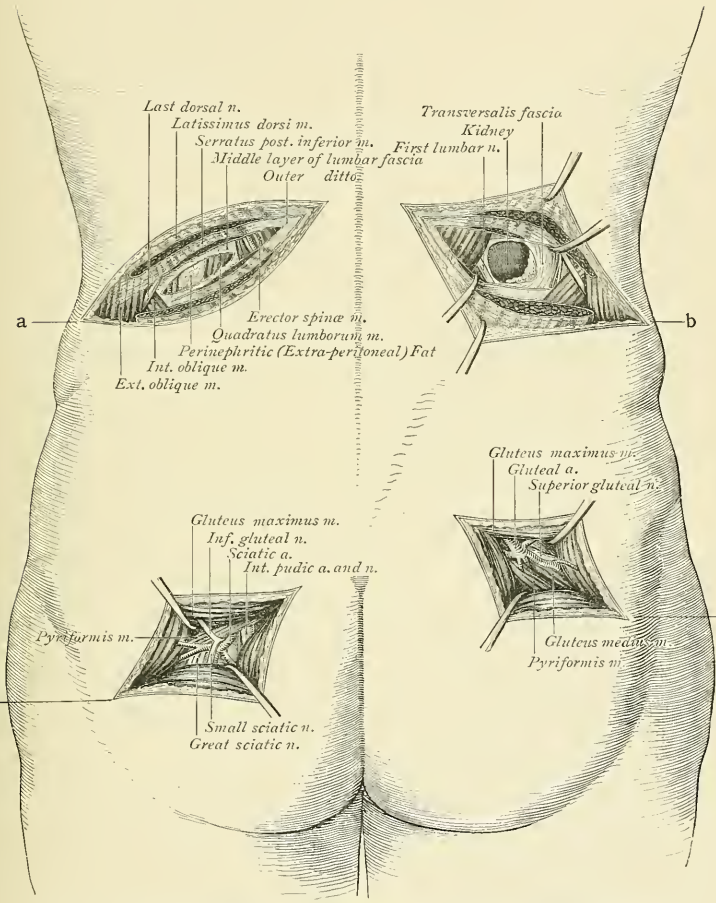

FIG. 54.—(*a*) and (*b*) Nephrotomy. (*c*) Ligature of the sciatic and internal pudic arteries; exposure of the great sciatic, small sciatic, and pudic nerves. (*d*) Ligature of the gluteal artery and exposure of the superior gluteal nerve.

inwards. The abundant loose post-renal fat, and the vessels which lie beneath the transversalis fascia, are then exposed. The kidney is now reached by carefully separating this fatty capsule with the finger. It is only in cases of floating kidney that pressure must be applied to the abdominal wall from the front. In nephroraphy the thin fibrous *capsula propria* of the kidney is incised and stripped from the organ, so that a good grip of it may be included by the four to six sutures which are used to unite it firmly to the lumbar fascia. The exposed kidney substance lies at the bottom of the wound, which is left open in order that the firm scar may extend from the skin to the kidney substance. The nerves already mentioned must not be included in the suture.

When it is desired to dislocate the entire kidney in order to examine it, or to incise or excise it, then the *capsula propria* is not stripped off. The pelvis of the kidney may be manipulated by grasping the organ in the neighbourhood of the hilus from behind, as the ureter lies behind the vessels. When the pelvis is dilated, it is opened from behind. In other cases it is better to make a short longitudinal incision at the convexity of the kidney, and having introduced the finger into it, to bore one's way into the pelvis, in the direction of the hilus. When the kidney substance has been interfered with, it is desirable to treat the wound by the open method, or to use a secondary suture, not only on account of the escape of urine, but because it has been the experience of myself and Dr. TAVEL that the surrounding tissues are readily infected in kidney injuries. The kidneys generally harbour and excrete micro-organisms which give rise to inflammation. It is well, therefore, to give such patients a course of salol (45 grains a day) before the operation.

In nephrectomy we have for years past adhered to the practice of dividing the transversalis muscle as far forwards as to expose the reflection of the peritoneum on to the colon in the region of the posterior axillary line, and at this point to open the peritoneum. We have always succeeded in passing the hand through this opening far enough into the abdominal cavity to be able to touch the opposite kidney, to form an opinion regarding its size and consistence, and also to feel the renal artery. The under surface of the liver and the region of the gall bladder can also be palpated, a step which is often desirable in order to settle the diagnosis. After ascertaining the presence of a well-developed kidney upon the opposite side, the opening in the peritoneum is sutured and the removal of the kidney proceeded with, according to the nature of the disease. After ligaturing all the accessible larger vessels going to the capsule, the kidney is drawn forward as much as possible in order to expose the region of the hilus, so that a silk ligature (3 or 4 plies of fine silk being preferable to a single thick piece) may be passed round the renal artery and vein and firmly knotted. When the ureter can be isolated, a separate double ligature is to be applied to it, and after

dividing it between the ligatures the stump is disinfected with a sublimate swab.

76. Ureterotomy. *a. Anterior Ureterotomy.* The incision is the same as for ligature of the common iliac artery.

We have excised the ureter by this method in a case of tuberculosis of the ureter which had been diagnosed by vaginal palpation as well as by the condition of the urine. An incision is made three finger-breadths above the outer two-thirds of POUPART'S ligament, its outer extremity being continued vertically upwards, just as for exposure of the common iliac artery. The skin, superficial fascia, external oblique aponeurosis, and the two inner abdominal muscles are divided; at the outer vertical part of the incision the external oblique is still muscular, and both the inner muscles, especially the internal oblique, are well developed.

The fascia transversalis is then divided, and the peritoneum, which is not to be opened, is now stripped off the iliac fossa as far as the psoas. This is easy when there are no abnormal adhesions. The ureter may readily be recognised as it descends in front of the iliac artery into the true pelvis towards the lateral part of the base of the bladder. It is still easier to follow it upwards external to the vertebral column. As the ureter by this method can be exposed from the kidney to the bladder, and as the kidney may when necessary be excised at the same time (as was done in the above case), we regard this procedure as the best for diffuse diseases: it allows of excision of the ureter in its whole extent. Anterior ureterotomy gives the best access also for merely incising the ureter; for example, for the purpose of removing an impacted calculus the exact situation of which cannot be made out with certainty. In certain diseases of the kidney, especially when it is displaced, this incision may occasionally be employed for its removal.

b. Posterior Ureterotomy. The upper part of the ureter can be well exposed by an incision similar to that given for nephrotomy (Fig. 54), except that it is placed more nearly vertically.

c. Inferior Ureterotomy. The lowest part of the ureter near its termination in the bladder can be exposed by the parasacral incision as described for excision of the rectum. It may, however, also be exposed from the perineum by an incision to be described later (p. 163).

77. Splenectomy. The spleen may be exposed in a manner similar to the kidney by prolonging forwards the incision on the left side. We give no complete description of the operation, which necessarily varies very much in different cases, being influenced more especially by the size and nature of the tumour.

O. ABDOMEN

Normal Incisions

An anterior *mesial incision* gives access to the viscera of the abdomen with least injury. No vessels of any importance are met with, apart from the occasional presence of an unobliterated umbilical vein, and some veins situated in the extra-peritoneal fat.

The skin, superficial fascia, and the linea alba (line of union of the sheaths of the two recti muscles) are divided. Under these lie the fascia transversalis, and still deeper the peritoneum, covered by more or less extra-peritoneal fat. Above and below the umbilicus the peritoneum is loosely connected with the linea alba; at and near the umbilicus, however, it is more firmly united.

The median incision does not always suffice for deeper organs placed laterally, that is to say, it inflicts unnecessary injury, because the intestines lie anteriorly; the organs which lie in the hypochondriac and iliac regions are especially far from the median incision. The much-employed lateral longitudinal incisions along the outer borders of the recti are to be discarded, because they divide the nerves which go to these muscles. With a long incision, especially if placed in the upper part of the abdomen, this disadvantage must not be under-estimated, as the paralysis of the muscles predisposes to a ventral hernia.

Besides the median incision, the only really rational incisions which have regard for the course of the nerves are the *transverse or slightly oblique incisions* placed parallel to the nerves. It is true that such transverse incisions divide the three broad abdominal muscles, but the nerves lying between the individual layers, especially those lying between the internal oblique and transversalis muscles, can be pushed aside. As regards the rectus itself, a transverse incision through it does less injury than a longitudinal one at its outer edge, because the motor nerves remain intact, and an artificial tendinous intersection is all that is produced, so that the muscle contracts as before. With transverse incisions, however, the superior and inferior epigastric arteries are divided, and must be ligatured.

Epigastrium

78. Gastrostomy (Figs. 55 and 56). The making of a gastric mouth in cases of inoperable stricture of the œsophagus, especially in the carcinomatous variety, is an excellent operation, as it distinctly prolongs the life of the patient and greatly reduces his suffering. A patient on whom we operated ten months ago, and who had been previously treated

by gradual dilatation, followed by the introduction of tubes left *in situ*, assures us that he derived far greater benefit from the gastrostomy than from the earlier treatment; but in order that this may be the case, care must be taken that a gastric mouth is made which is capable of *spontaneous closure*. After testing the various methods which have been recommended, we have come to the conclusion that ALBERT'S method, somewhat modified, is the simplest and most reliable.

An incision beginning two finger-breadths below the margin of the ribs is carried from above downwards and outwards over the rectus muscle; it approaches the vertical rather than the horizontal direction. The skin, superficial fascia, and the thick anterior layer of the rectal sheath are divided. The muscular fibres of the rectus are separated vertically towards the inner edge of the wound with a blunt instrument, and the fibres drawn outwards. The posterior layer of the rectal sheath is now divided, the peritoneum opened, and the stomach drawn forward. As the stomach is often very much contracted, the relations of the vessels and of the omentum must be carefully examined in order to make certain that a portion of the transverse colon is not sutured.

A long conical diverticulum of the stomach is now drawn well out of the wound, and the parietal peritoneum stitched round its base (without constricting it too much) by means of a continuous suture which penetrates first the serous and a portion of the muscular coat of the stomach, and then the parietal peritoneum along with the posterior layer of the sheath of the rectus. A small incision is now made through the skin at the level of the costal cartilages, and the diverticulum of the stomach is drawn upwards under the skin and over the lower costal cartilages as far as the small skin incision, to the edges of which the apex is fixed by two sutures. A small opening is then made into the stomach, and other two to four fixation sutures passed through the wall of the stomach and the skin. The lower wound is closed by a continuous suture. The result is that the stomach is bent upwards, that the base of the diverticulum is gripped by the muscular fibres of the rectus, and that a short upwardly-directed subcutaneous œsophagus is formed. Escape of the contents of the stomach is thus prevented, whilst the patient has no difficulty in introducing food by means of a catheter.

79. Gastro-Enterostomy (Fig. 57). An incision 10 to 15 cm. (4 to 6 in.) in length is carried down to or beyond the umbilicus according to the difficulties to be anticipated. After drawing the omentum upwards and exposing the intestine, a loop is pulled forward, and followed in both directions until the place is reached where the commencement of the jejunum appears from beneath the mesocolon. We have not risked suturing the first loop of intestine which presents itself, as LÜCKE has done, although in his cases no distinct disadvantage resulted. Nutrition is certainly interfered with if, as in the cases of ALSBERG and LAUENSTEIN, the fistula is placed only one metre (3 ft. 4 in.) above the ilio-cæcal valve.

It is a question how far the vomiting (which frequently occurred also in LÜCKE's cases—in one case it was faecal, and attended with great danger to life) is to be ascribed to such a procedure. By our method, however, a

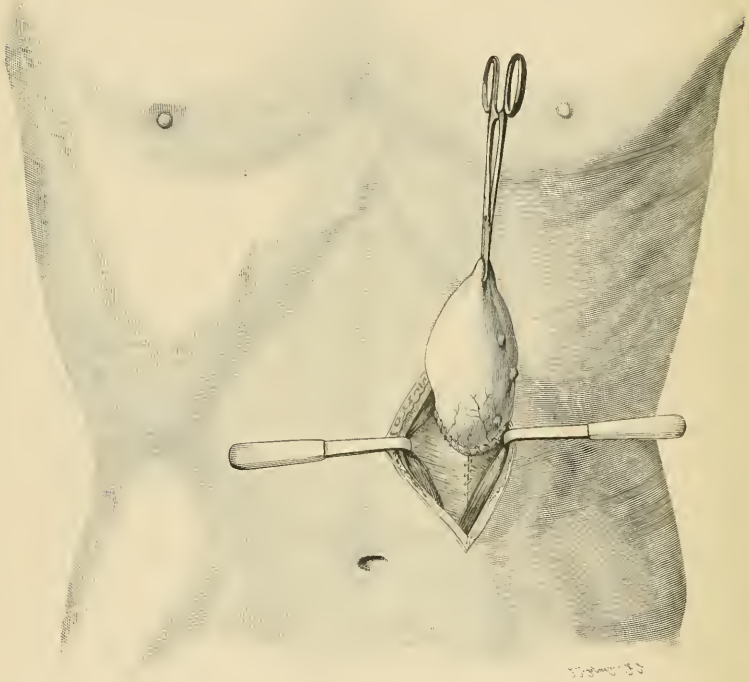

FIG. 55.—Gastrostomy according to Albert (somewhat modified). A portion of the stomach is drawn forward out of the abdominal wound and sutured at its base to the peritoneum and posterior layer of the sheath of the rectus, the muscular fibres of the rectus being held apart.

pretty large amount of intestine must often be drawn forward, the rejected parts being immediately replaced. Adopting WÖLFLER's proposal, a loop about 16 inches from the origin of the jejunum is selected and applied to the stomach. We have, in agreement with SOCIN, refused to employ the complicated methods of HACKER, COURVOISIER, and BILLROTH, which

consist in bringing the intestine up to the posterior surface of the stomach through the gastro-colic omentum or mesocolon. Such procedures seem *a priori* reasonable, but they all have the great disadvantage of rendering the introduction of the sutures difficult. Moreover, the

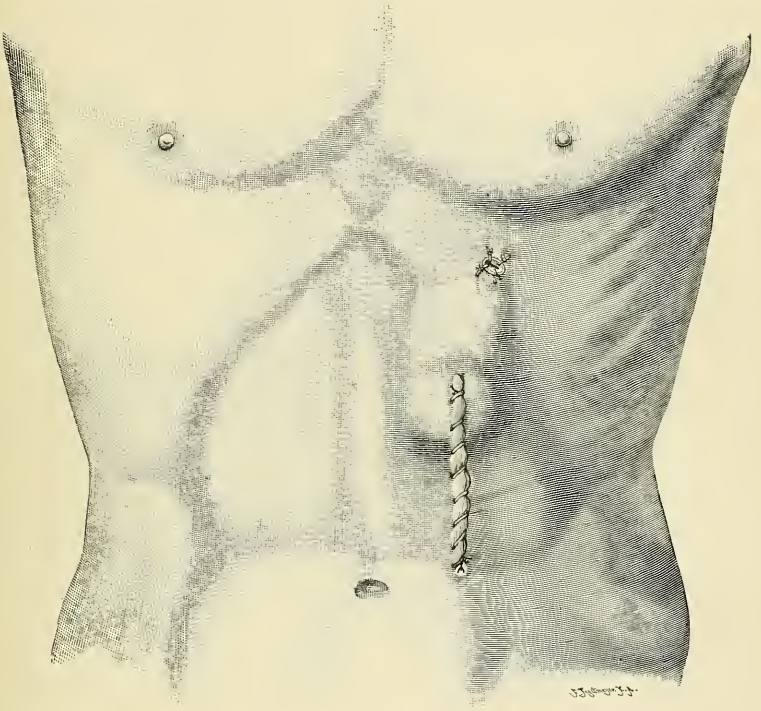

FIG. 56.—Gastrostomy according to ALBERT, completed. The main wound is sutured; the apex of the drawn-out portion of the stomach is sutured to a small opening in the skin above the costal margin, and is then opened.

parts cannot be drawn sufficiently far down out of the abdomen, and the intestinal contents which escape cannot therefore be prevented with certainty from entering the abdominal cavity. We have always performed the so-called *anterior gastro-enterostomy antecolica*. This operation is performed as follows.

The position and direction in which the intestine is united to the stomach are a matter of essential importance. WÖLFLER has drawn attention to the fact that the intestine must be applied to the long axis of the stomach in such a way that the direction of the onward movement of the contents of the former must correspond with the flow in the stomach, *i.e.* that the proximal portion of the intestine must be towards the left and the distal portion towards the right. The most important point, however, appears to us to be that the contents of the stomach should be able readily to reach the distal portion of the intestine, and that

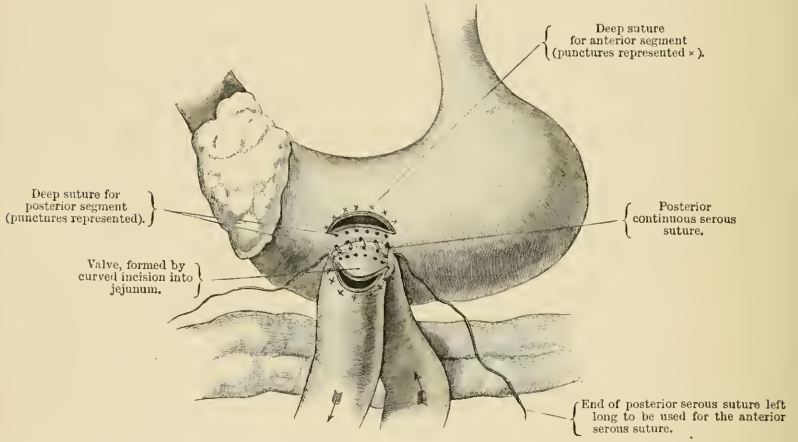

FIG. 57.—Gastro-jejunostomy. The jejunum is placed vertically to the stomach, so that the proximal portion of the loop passes vertically upwards and the distal portion vertically downwards. A flap is formed from the intestine to prevent regurgitation into the stomach.

kinking and spur formation should not take place between the two limbs of the loop, as in SENN'S [1] cases. On the other hand, it appears to us to be of the highest importance that the contents neither of the lower nor of the upper end of the intestine should readily enter the stomach, as we have formerly observed fatal cases which occurred after successful suturing and in the absence of any peritonitis, and which could only be attributed to the absorption of intestinal contents which had reached the stomach and subsequently undergone decomposition. We have sought to meet the above-mentioned indications as follows. The intestine as shown in Fig. 57 is placed, not in the direction of the long axis of the

[1] *New York Med. Record*, November 1861.

stomach, but at right angles to it, and in such a way that the proximal portion of the loop ascends and the distal portion descends. The escape of the stomach contents into the distal portion is thereby greatly favoured. In order, however, to be able to unite the stomach and intestine at right angles to their axes, the latter must be opened, not longitudinally, but transversely upon its convex side, to the extent of almost half its circumference. Moreover, the intestine is sutured to the stomach in such a way that the proximal part of the loop lies directly upon the stomach, while the distal part is free upon it. The distended distal part of the intestine can thus bring about compression of the proximal portion, but not *vice versa*. When therefore the distal portion becomes filled from the stomach, there is less chance of anything reaching the proximal portion. If on the other hand the proximal portion of the loop empties itself into the distal portion, the latter, being empty, is at once filled, and contracts.

In order, however, to still further ensure that the contents of the stomach and proximal piece of intestine should pass on into the distal portion, an artificial valve is constructed (Fig. 57) by making a curved incision into the convexity of the intestine at some little distance from the stomach. The outer surface of the base of the flap is now sutured to the lower edge of the wound in the stomach, the edge of the flap itself being left free. The upper edge of the stomach wound is sutured to the lower and concave edge of the intestinal wound in the usual simple manner. WÖLFLER had previously endeavoured to establish a valve at the stomach opening; but, according to SOCIN'S statement, his method is difficult to carry out even upon the cadaver, and therefore difficult also upon the living subject. The sutures are applied in a manner similar to that about to be described for stomach and intestinal resections. The method has recently been particularly recommended in a somewhat modified form by BRAUN.[1] After placing the intestine and stomach in contact, a continuous serous suture is first introduced; this securely fixes the loop of intestine to the stomach, and may be termed, according to WÖLFLER, the *posterior serous suture*. The incisions into the intestine and stomach are now made, but at first only through the serous coats, in the way described by KUMMER and employed by us in the submucous method of resection of the stomach. A *second continuous posterior suture* is now introduced through the entire thickness of the wall as far as the muscularis mucosæ. After the contents have been pressed out from the proximal and distal portions of the loop, it is desirable that the bowel be carefully closed by the fingers of the assistant, because in incising the intestine the mucous membrane is often divided or torn through at some point. While the intestine is being compressed, it is not difficult at the same time to so compress the stomach as to prevent the escape of its contents. After incising the intestine and stomach to the extent already

[1] *Deutsche Medic. Wochenschrift*, 1891, No. 1.

mentioned, it may be desirable to introduce a special *mucous suture*, as recommended by BRAUN. All our sutures are without exception *continuous*, and we entirely agree with RYDYGIER that it is only by the use of these that an air-tight and water-tight closure can be guaranteed. The ends of the posterior suture are therefore left long, and secured provisionally with artery forceps. Next comes the *anterior suture*, which is much more easily introduced, and in reverse order: first, the *anterior mucous suture*, which is of no great importance as it easily cuts through, then the anterior suture through the *entire thickness of the wall*, and lastly the *anterior serous suture*. The ends of the threads are knotted with the ends of the posterior suture, which had been left long. In incising the stomach and intestine it is desirable to arrest the bleeding from all the more important vessels with fine silk ligatures. Fine and strong silk is employed for all sutures without exception.

Before opening the intestine and stomach, gauze must be carefully packed under and around these organs in order that no intestinal contents may reach the abdominal cavity. The cut surfaces and the parts in the immediate neighbourhood of the sutures must be very carefully disinfected with a 1 : 1000 sublimate solution. Irrigation is undesirable, as infectious materials may thereby be conveyed into the abdominal cavity. Except for the above-mentioned purposes, the employment of antiseptic substances is, as in all laparotomies, to be avoided, and only a ·75 per cent salt solution which has been sterilised by half an hour's boiling, and in which sterilised swabs, etc., are dipped, is to be employed. The wound in the abdominal wall is closed by strong interrupted buried sutures for the fascia, and by a continuous suture for the skin. A collodion strip is used for the deep dressing.

Any one who has witnessed the transformation experienced by a patient on whom gastro-enterostomy has been performed for carcinoma of the pylorus, and still more for simple stricture, must regard this operation as categorically indicated. The patient who previously has been limited to a very restricted diet and tormented with pain after every meal until the greater part was vomited, and who as a result of imperfect nutrition has become far reduced, is, within a fortnight, able to digest any kind of food, acquires week by week a healthier appearance, and ultimately may return to work again. In a more advanced stage of the disease, when extensive adhesions have formed, and when glandular infection has occurred and the greater part of the stomach has been involved by the growth, it is too late to expect any benefit from surgical interference.

Pylorectomy

While the results claimed for gastro-enterostomy are fully recognised, pylorectomy must be looked upon as the operation of the future in selected cases.

The longest period during which life can be prolonged and rendered tolerable, after a palliative operation, is but little over a year. The results after resection of the pylorus are quite different; the time the patient can be kept in a satisfactory state of existence has in a number of cases been considerably longer. Among the recorded cases is one in which the operation was performed by WÖLFLER, and in which the patient lived for $5\frac{1}{4}$ years after the operation. This is the longest period of survival recorded up to the present time. During five years of this time, the patient had no digestive derangement and no local recurrence. She died from glandular recurrence around the portal fissure and in the iliac fossa. The stomach was normal in form and size; the peptic glands were absent from the neighbourhood of the scar; but the mucous glands and the muscular bundles were well preserved. There was no recurrence in the stomach itself. RYDYGIER has reported the case of a woman who died of recurrence $2\frac{1}{2}$ years after the operation, after being entirely free from complaint for two years. BILLROTH has recorded observations in which the duration of life after operation reached $2\frac{1}{2}$ and $1\frac{1}{2}$ years. In 1887 we recorded the case of a woman upon whom we operated, and who lived three years after the operation, and who died ultimately of simple fibrous stricture, in which Professor LANGHAUS could not detect a local recurrence. As a permanent recovery has not been published up to the present, we consider it especially valuable to record a case in which the operation was performed five years and four months ago, and in which there is at present no sign of recurrence; on the contrary, the patient (the mother of a medical man) enjoys perfect health, and can take pretty well any food, just like a healthy person. In appearance she is up to the present very healthy-looking. We have therefore every right to look upon this as a permanent cure. The report furnished by Professor LANGHAUS leaves no doubt as to the carcinomatous nature of the affection, and he has again recently informed us that the pathological and anatomical diagnosis is certainly carcinoma.

80. Resection of the Pylorus. Although a permanent cure is still the exception after excision of a carcinoma of the stomach, it would appear that the imperfect results hitherto obtained furnish the real explanation why so many practitioners cannot make up their minds to recommend their patients to seek surgical advice at a sufficiently early period of the disease. The surgeon often sees patients with advanced and inoperable carcinoma of the stomach who are astonished on being told that an operation might have been performed. Although a great deal has been written on the importance of the presence of hydrochloric acid, little has come out of it so far as radical treatment is concerned; and yet the entire welfare of the patient depends upon the earliest possible excision, just as in carcinoma in other parts of the body. It is the duty of the surgeon, however, to take care that the immediate danger of the operation is

reduced to a minimum by perfecting the technique. Our later results justify us in giving once again an exact description of the method we employ. In sixteen of our resections for carcinoma of the stomach we have employed the original BILLROTH-WÖLFLER method. Twice we have departed from it by closing the stomach and duodenum after having excised the tumour, and then re-establishing the continuity of the stomach and intestine by gastro-enterostomy. This operation was first proposed by BILLROTH, and was carried out by him in the year 1885 by first performing gastro-enterostomy by WÖLFLER'S method, after which the extirpation of the carcinoma was undertaken. The patient recovered from the operation, but recurrence soon took place. Neither the results of the BILLROTH-WÖLFLER method, nor those of the plan just referred to, have fulfilled our expectations, the mortality of all the operations performed in hospital and private practice amounting to 66 per cent. It is only since we have employed the method about to be described that we have attained a degree of certainty regarding the immediate result of the operation. In ten cases we have performed the operation by first excising the cancerous pylorus, and then suturing the duodenum to a special opening in the wall of the stomach. Of these ten cases only two have died, eight having recovered.

Our method of *resection of the pylorus with gastro-duodenostomy* is the following (Figs. 58, 59, and 60):—

A mesial incision 10 to 15 cm. (4 to 6 in.) long is carried downwards for a greater or less distance below the umbilicus, according to the position of the tumour. The umbilicus is excised, and all hæmorrhage arrested. After opening the abdominal cavity, the tumour is drawn out as far as possible and its limits determined in both directions. The greater and lesser omenta are separated from the stomach and duodenum over an area corresponding to the amount of stomach and intestine to be removed. This separation should be made as close to the stomach as is consistent with complete removal of the disease, and is effected by the fingers or a blunt instrument; the larger vessels are avoided as much as possible, and all bleeding points ligatured. After isolating the tumour, sterilised gauze is passed beneath it and around the duodenum and stomach in order to prevent the possibility of any stomach or intestinal contents reaching the abdominal cavity.

A clamp is now placed upon the duodenum close to the edge of the tumour, and two (one from above and one from below) upon the stomach towards the gastric side of the tumour (Fig. 58). The clamps chosen for this purpose are large artery forceps, which can be closed by means of the usual catch. The clamps may be firmly closed without hesitation, as there is no danger of causing necrosis of the gastric or intestinal walls. A second clamp is placed upon the healthy duodenum parallel to and beyond the first one, and the duodenum is then cut across between them. The edge of the gut which projects beyond the clamp is thoroughly

disinfected by means of a small swab soaked in a 1 : 1000 sublimate solution. The divided duodenum towards the side of the tumour is merely wrapped round with sterilised gauze and the new growth lifted out; the other end of the duodenum is folded over the right margin of the wound and covered provisionally with moist gauze (Fig. 59). The

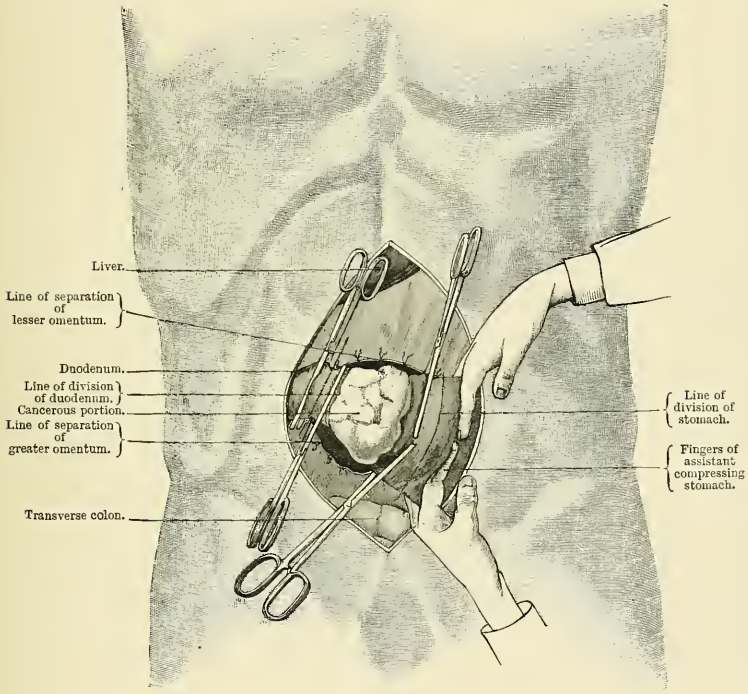

FIG. 58.—Resection of the pylorus, first stage. The carcinomatous portion is isolated by separating the lesser and greater omenta, and then shutting it off by means of clamps. The cavity of the stomach is shut off by the fingers of an assistant, and that of the duodenum by clamps. The lines of section are indicated by interrupted lines.

assistant now grasps the stomach from above and below between the fore-finger and thumb[1] in order to close it securely, and after placing a ring of

[1] Or between the index and middle fingers as shown in Fig. 58.

gauze over the hands of the assistant and around the stomach, the latter is cut across along the two clamps (along the interrupted line, Fig. 58). The new growth is laid aside, and after swabbing away any escaped gastric contents, and ligaturing the more important bleeding vessels, the stomach is closed by a continuous silk suture which penetrates *all three coats*, and passes from the greater towards the lesser curvature, or *vice versa* (Fig. 59).

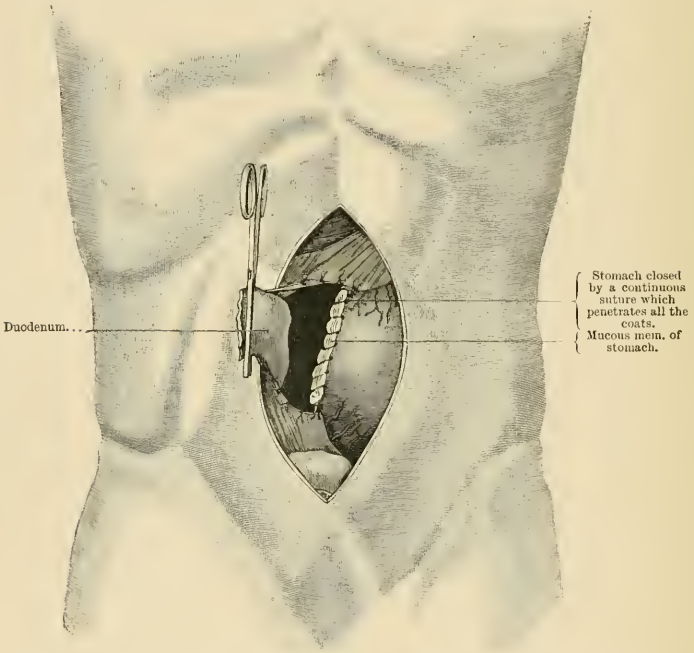

FIG. 59.—Resection of the pylorus, second stage. The stomach is closed by the first continuous suture, which penetrates the whole thickness of its walls; the duodenum, still closed by means of the clamp-forceps, is thrown over the right edge of the wound.

The projecting edges of the mucous membrane are thoroughly cleansed with sublimate lotion. With the assistant holding the stomach so as not to stretch its walls, the continuous deep suture is invaginated, and a continuous LEMBERT'S suture is introduced in such a way that the serous coats are completely and reliably approximated in their whole length.

After changing any gauze that may have been soiled, the assistant

grasps the stomach with both hands so as to direct its posterior wall forwards and to the right, and at the same time presses it against the right margin of the wound so as to close the duodenum. The posterior

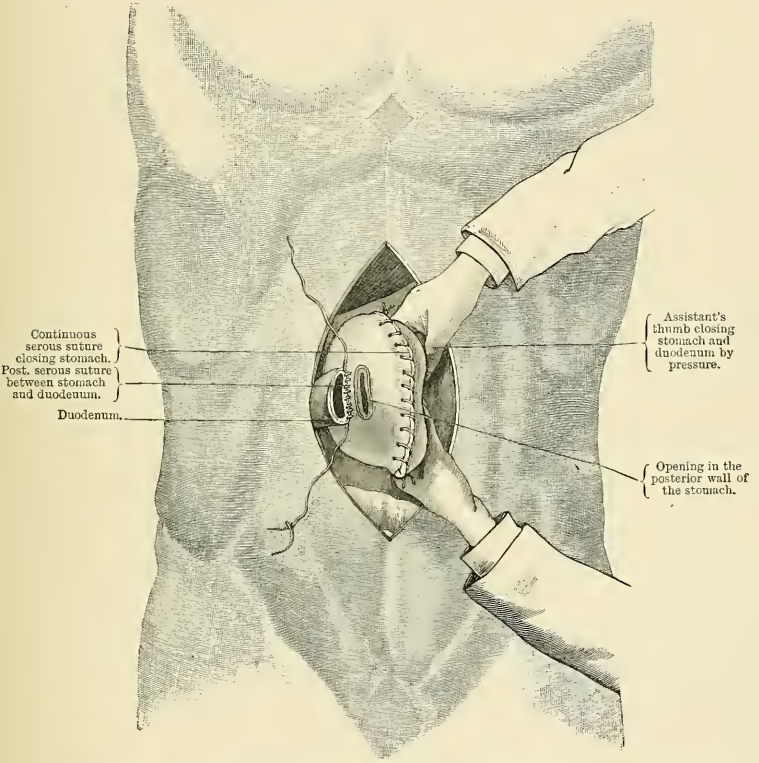

FIG. 60.—Resection of the pylorus, third stage. The stomach is closed by a double suture, and an opening is made upon its posterior surface, to the posterior segment of which the duodenum is united by a continuous serous suture. The assistant is pressing the stomach and duodenum against the right edge of the wound in order to close them.

wall of the duodenum (with the forceps still clamping it) is now applied to the posterior wall of the stomach in such a way that a *continuous posterior serous suture* may be comfortably introduced from its upper to its lower edge (Fig. 60). It is only now that the forceps are removed

from the duodenum. The escaping contents are thoroughly removed and the lumen disinfected. Ligatures are applied to arrest hæmorrhage from the edges of the duodenal wall. The stomach is next incised $\frac{1}{2}$ to $\frac{3}{4}$ cm. (about $\frac{1}{4}$ in.) from the posterior serous suture for a distance corresponding to the breadth of the duodenum. The bleeding vessels having been caught and tied, a single *posterior continuous suture* is introduced through all three coats, or two rows of continuous sutures may be introduced, one including the serous and muscular coats and the other the mucous coat. The ends of the posterior sutures, which have been left long, are now re-threaded and employed in succession for the *anterior sutures*, the order being reversed. The protecting gauze having been removed, the lines of suture are again thoroughly disinfected, the stomach and intestine replaced, and the abdominal wound closed by deep interrupted sutures and a continuous cutaneous suture. Collodion strips are applied over the wound.

All the eight cases which have been operated on by this method healed completely. In one case we had an interesting experience of the pyloric insufficiency which has been referred to by EBSTEIN.[1] It is not to be wondered at that after the excision of that portion of the stomach, the motor functions of which are so important, the capacity of the stomach for emptying itself into the duodenum should suffer, and that conversely the intestinal contents should regurgitate into the stomach and there undergo decomposition, in consequence of the deficiency or absence of acid in the gastric juice. Vomiting is thus induced, attended with the danger of acute inanition, or of serious symptoms from absorption. We have got rid of this condition mechanically, by simply placing the patient upon the right side. The vomiting ceases at once when this is done, but tends to recur for some time when the patient turns on to the back. Since adopting the above precaution it has been our experience that the patient feels much better and vomits less. There is a gradual improvement both in the chemical and in the motor functions of the stomach. SOCIN has drawn attention to this. The observations of OBALINSKI and JAWORSKI[2] upon the very imperfect restoration of the mechanical and chemical activity of the stomach after pylorectomy for carcinoma refer only to a short period following the operation.

Were we to emphasise the points which seem to us to be essential to the success of the operation, we should mention the following:—

1. The operation must be performed *aseptically*, and the greatest care must be taken to avoid the entrance of disinfectants into the abdominal cavity. Sublimate and its substitutes must only be used to disinfect the lines of suture and the areas of peritoneum which have been directly contaminated by the gastro-intestinal contents: they must never be used for washing out. The numerous cases of collapse after the operation can only be attributed to the employment of antiseptics, as the same danger has been found to exist after the much

[1] VOLKMANN'S *klin. Vorträge*, No. 87. [2] *Wien. klin. Wochensch.* 1889, No. 5.

less severe and simpler gastro-enterostomy. (ROCKWITZ reports that most of LÜCKE'S cases showed severe collapse after the operation.) This is not the case, however, even in a very prolonged operation, if physiological salt solution is employed exclusively for swabs and for all the gauze placed round about the wound. It is essential to use plenty of soft gauze, in order to prevent the escape of gastro-intestinal contents into the abdominal cavity.

2. The *continuous suture* so warmly advocated by RYDYGIER and LAUENSTEIN appears to us to be absolutely essential to success. All the sutures, not merely the deep ones which penetrate the whole thickness of the wall, but also the superficial serous sutures, must be introduced continuously and without the least interruption from one end of the wound to the other; and this is why we have so forcibly advocated the necessity of leaving the ends of the posterior sutures long after knotting them, in order that they may be again reliably knotted with the anterior sutures. A perfectly secure closure is thus attained, and there is not the slightest necessity to prove that the suture is water-tight by distending the intestine. Moreover, it appears very important to carry the continuous suture through the *entire thickness* of both gastric and intestinal walls, as it is only by this means that reactionary hæmorrhage—which has been the cause of, at any rate, a certain number of fatal cases—can be prevented with certainty. We are satisfied that GELY'S suture, which we formerly recommended for closing the stomach, may be replaced by the simple continuous *glover's suture*, which penetrates all three layers. The latter is much more easily and rapidly introduced. The application of clamps to the sound side of the stomach must, however, be dispensed with, and the closure of the organ effected merely by the fingers of a reliable assistant. We have never employed the method of suturing by plates so ingeniously developed by SENN, as it appears to us to be more complicated than the method of suturing which we have recommended, and the results which have been obtained by their use do not seem to have quite fulfilled expectations. It is pretty generally recognised that for continuous sutures—from which such a very important mechanical object is demanded—only fine strong silk, and not the less reliable catgut, is to be employed. We have not seen any of the disadvantages ascribed to silk. It remains in position for months.

3. The last point, upon which we place great value in simplifying the operation and adding to its security, is *the employment of clamps.* They are absolutely necessary for the closure of the cancerous portion both on the duodenal and on the gastric side. It is only in this way, as we have already pointed out (*Centralblatt für Chirurgie*, 1883, No. 45), that the dangerous escape of cancer juice can be prevented with certainty. The clamps have an additional advantage which should not be undervalued, namely, that the intestine, and more especially the stomach, can be cut

across along an exact line at the place desired, a matter which is otherwise not always easy. Further, the application of clamps greatly shortens the operation. They produce complete closure, and serve as convenient handles for drawing up and pushing aside the new growth, as well as the stomach and intestine. They increase the possibility of thoroughly disinfecting the cut edges immediately after the section, by preventing them slipping back. The fact that they necessitate the removal of somewhat more of the sound tissue, as has been stated by LAUENSTEIN, can scarcely be looked upon as a disadvantage, as the prospect of a permanent cure is thereby increased. The theoretical disadvantages which have been attributed to the clamps do not in reality exist. We are quite convinced that it is an error to attribute subsequent necrosis of the edges of the wound to the use of clamps. If the suturing is properly done, and the operation performed aseptically, then in spite of clamps no necrosis occurs. We have no hesitation, therefore, in applying a clamp to the healthy portion of the duodenum where it is afterwards to be stitched. It completely closes the intestine, and prevents any bleeding until the duodenum has been fixed in a definite position to the stomach by the continuous serous suture, after which the arrest of hæmorrhage as well as the application of antiseptics can be done with greater certainty. Our method of applying the clamps differs, however, from that of other surgeons, inasmuch as we do not pay the slightest attention to diminishing the pressure by applying an elastic covering to the blades according to GUSSENBAUER'S method, or by using elastic bands according to RYDYGIER. We do not, however, intentionally close the clamps with special firmness, but still firmly enough to thoroughly close the intestine and stomach, and we have observed that both become at once actively vascularised and bleed as soon as the clamps are removed. Moreover, we must remember that LÜCKE, who has had such brilliant results in gastro-enterostomy (seven successful cases in succession), employed clamps. They have also been recommended by PETERSEN of Kiel. And finally, we may remark that our clamps require no more room than those of RYDYGIER, so that the reproach of LAUENSTEIN, that they necessitate a greater separation of the omentum, does not apply.

Hypochondrium

81. Cholecystotomy (Fig. 61). To open the gall bladder, an obliquely transverse incision (in the figure the incision is too oblique) 10 to 15 cm. (4 to 6 in.) long, and at a distance from the costal margin of from 4 to 6 cm. ($1\frac{1}{2}$ to $2\frac{1}{2}$ in.), is made. It begins near the middle line over the prominence of the rectus, and divides skin, superficial fascia, and the aponeurosis of the external oblique, which in front of the rectus is united with that of the internal oblique. The rectus

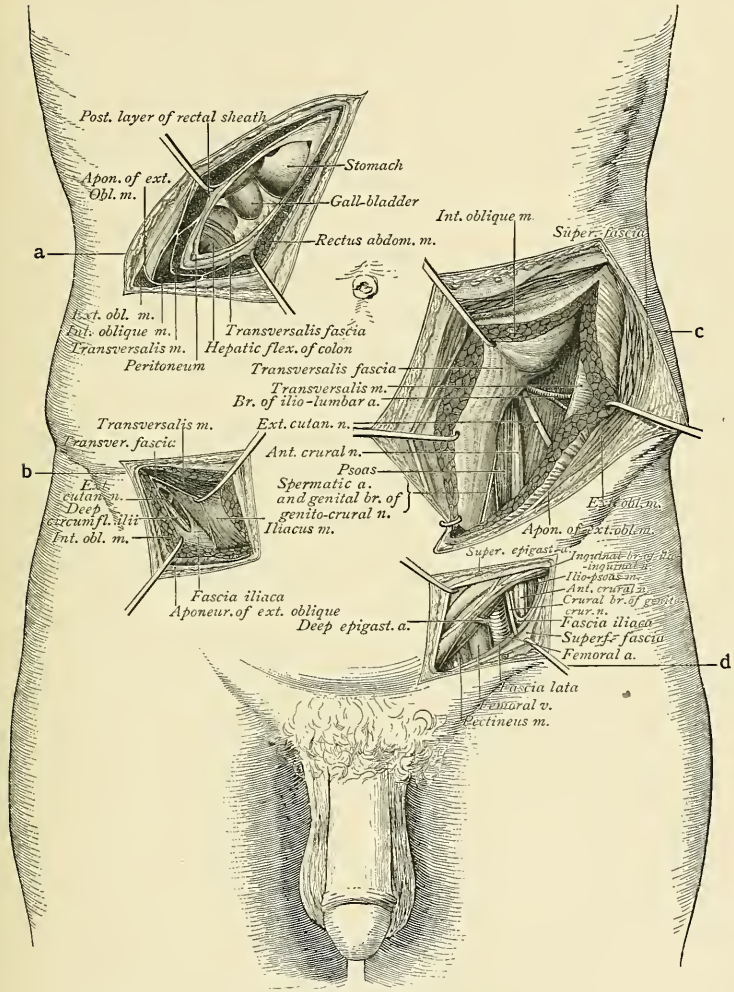

FIG. 61.—Cholecystotomy. Ligature of the deep circumflex iliac artery. Ligature of the common iliac artery. Ligature of the common femoral artery.

muscle then appears and is divided, the superior epigastric artery which lies beneath it close to its outer border being ligatured, as well as some muscular branches. The external oblique, and under it more internally the internal oblique, are divided at the outer part of the wound. The intercostal nerves pass inwards towards the rectus beneath the internal oblique, while upon the surface of the external oblique are the small perforating branches of these nerves. The muscular fibres of the transversalis extend beneath the edge of the rectus to end in an aponeurosis which, having united with the deep layer of the internal oblique, passes inwards behind the rectus to the linea alba. Beneath this again are the transverse fibres of the transversalis fascia, on dividing which the peritoneum is exposed.

After dividing the peritoneum, the gall bladder, if elongated and enlarged, can be seen and drawn forward. Upon its inner side is the pyloric portion of the stomach, upon its outer side the colon. The omentum often lies in front of it, and must be pushed downwards and to the left; it is frequently adherent to the gall bladder.

The gall bladder is now drawn as far as possible into the wound, and the edges of the parietal peritoneum sutured on both sides close up to it, after which (provided the wall of the gall bladder has not been rendered too friable by the inflammation) a circular suture is introduced uniting the parietal to the visceral peritoneum. When this cannot be done, then the edges of the opening in the parietal peritoneum are merely brought together by sutures, so as to leave an opening, which is drawn closely round the base of the part of the gall bladder which has been protruded. The rest of the wound is left open, and iodoform gauze is placed around the projecting portion of the gall bladder.

82. Cholecystectomy. The visceral peritoneum covering the anterior surface of the gall bladder is divided high up parallel to the margin of the liver, and is then freed subperitoneally with a blunt instrument as far back as the cystic duct. The cystic artery is ligatured. The cystic duct is now divided between two ligatures. As micro-organisms can wander from the intestine into the gall bladder, the peritoneum must be protected from contamination by sterilised gauze; and after cutting across the cystic duct, the stump must be carefully disinfected either by 1 : 1000 sublimate swabs or by the thermo-cautery. While separating the gall bladder from the right lobe of the liver, the more important bleeding points can be ligatured; but if there is general oozing, compression must be resorted to for a time.

Umbilical Region

In the absence of any special indication, the abdomen is opened by a mesial incision, situated somewhere along the line which extends from the ensiform cartilage to the symphysis pubis, because, after dividing the

skin and subcutaneous tissue, the aponeuroses of the abdominal muscles will be found to be fused into a single layer (the linea alba), under which the fascia transversalis remains distinct. When possible, it is desirable to keep the incision away from the immediate region of the umbilicus. We may get rid, however, of the furrows and dimples of the umbilicus by excising it (omphalectomy). In umbilical hernia, for example, this can be avoided by making a transverse incision over the tumour, either above or below the umbilicus.

83. The Radical Operation for Umbilical Hernia. This operation, and that for strangulated umbilical hernia, are performed by making a transverse incision through the skin and subcutaneous tissue, either above or below the umbilicus, according to its relation to the main part of the swelling. The sac of the hernia is often intimately adherent to the skin, especially in the region of the umbilical cicatrix.

The fatty and fascial coverings are separated from the outer surface of the sac up to its exit from the umbilical ring. The sac is now opened, and one must again be prepared for adhesions, as in old persons large masses of omentum very often lie in the sac, and form extensive adhesions with the body as well as with the neck of the sac.

The separation of the omentum is often difficult; and, as it is always rolled up and shrunk, one may come to be very close to the transverse colon, in which case large vessels will require to be tied. Ligature of these vessels *en masse* may lead to thrombosis, and to necrosis in the region of the pedicle, which, with the tendency of old people to pneumonia, is not without danger. In such cases it may be desirable not to remove the portion of the sac to which the omentum is adherent, but to replace it along with the latter. When the contents have been successfully replaced, it is most desirable in the case of omental herniæ of long standing not to place a ligature around the neck of the sac, as is usually done in inguinal and femoral herniæ, but to cut away the thickened neck of the sac and to introduce deep sutures simultaneously through the aponeurosis (linea alba) and peritoneum (neck of the sac). It is best to use interrupted sutures at intervals of not more than 1 cm., and to apply them in such a way that the umbilical opening is firmly closed in a transverse direction.

Hypogastric and Iliac Regions

84. Puncture of the Abdomen. When the withdrawal of an accumulation of fluid in the abdominal cavity is indicated, the puncture is made in the lower part of the abdomen, midway between the umbilicus and the middle of POUPART'S ligament. The advantage of this situation is—as in the case of the incision for exposing the vermiform appendix—that the puncture is made external to the edge of the rectus, and therefore external also to the deep epigastric artery, and that it at the same

time avoids the muscular portions of the broad abdominal muscles, because they are here aponeurotic, and run together towards the sheath of the rectus. In using a large trocar, it is desirable to make a small preliminary skin incision, and to use, as in ovariotomy, a trocar with an inner canula having a blunt edge, which may be pushed forwards.

As the type of the normal incision for the *iliac regions* may be taken that for *ligature of the common* (Fig. 61) *or external iliac artery.* In the former, the abdominal wall is divided down to the peritoneum by cutting through the muscles and the fascia transversalis two finger-breadths above POUPART'S ligament. In the latter, the peritoneum is altogether avoided by keeping close to POUPART'S ligament, and dividing only the transversalis fascia, which is attached to it, the peritoneum being reflected on to the fascia iliaca half a centimetre higher up. (See ligature of these arteries.)

Abscesses in the iliac fossa can, in like manner, be opened extra-peritoneally by passing in front of or behind the iliac fascia; or the peritoneum may be opened, if one wishes to resect the vermiform appendix, to remove tumours of the cæcum, to make an artificial anus in the sigmoid flexure, or to remove the sigmoid on account of tumour. When the bladder is to be opened, a transverse incision from the right across to the left external abdominal ring is indicated.

Inguinal Region

To clear out the groin (to excise the glands), LAUENSTEIN makes one incision along POUPART'S ligament and a second one vertically over the great vessels.

The incision is made directly down over the line of the inguinal canal when it is desired to expose the spermatic cord in castration, or to search for the round ligament of the uterus, or lastly to reach the neck of a hernial sac lying in the inguinal canal (herniotomy).

Especially would we emphasise the fact that latterly in tumours of the testicle also we have, in the majority of cases, avoided incising the scrotum itself, and this in the interest of a more certain asepsis and of a better approximation of the edges of the wound. The purification and accurate suturing of the skin of the scrotum is more difficult than that of the skin over the inguinal canal; and with an incision over the latter, large tumours, hydroceles, etc., may readily be drawn out of the scrotum, and if necessary put back again. Our normal incision therefore serves also for herniotomy in both inguinal and femoral herniæ, for castration, for varicocele, for excision of a hydrocele, and for a modification of ALEXANDER'S operation for prolapsus uteri.

85. Exposure of the Spermatic Cord. Operation for Varicocele. Castration. Excision of the Tunica Vaginalis. A transverse incision is carried downwards and inwards over the inguinal canal a finger-

breadth above and parallel to the inner half of POUPART'S ligament. This incision corresponds exactly to the line of cleavage of the skin, and therefore comes together very easily. Two large veins which descend in the superficial fascia, the one at the outer and the other at the inner part of the wound, require to be ligatured.

When the incision is prolonged outwards, the superficial epigastric vessels which ascend from the femoral over POUPART'S ligament are divided. The external spermatic fascia which is prolonged down upon the cord from the edges of the external abdominal ring is then divided; next, the muscular fibres of the cremaster (from the internal oblique); and lastly, the strong infundibuliform fascia, the continuation of the fascia transversalis. Within the latter lies the spermatic cord or the round ligament according to the sex, and possibly a peritoneal diverticulum in the form of a hernial sac.

In *castration* the vas deferens is cut through, and the vessels (spermatic artery, artery to the vas deferens, and the venous plexus) individually caught up and divided. When this must be done higher up on account of the presence of tumour nodules, or of disease (tubercle) of the vas deferens, the anterior wall of the inguinal canal (aponeurosis of the external oblique) is slit up. Should the disease extend still deeper subperitoneally, the posterior part of the canal must also be slit up, and the canal very carefully sutured again.

In *varicocele* the large tortuous veins are isolated and excised as far as the testicle, for a distance of from 15 to 20 cm. (6 to 8 in.).

Provided the testicle is not adherent to the scrotum or markedly enlarged, it may easily be pushed upwards out of the wound and removed, or it may be replaced again when it is merely intended to slit up and *excise the tunica vaginalis* in cases of vaginal and funicular hydroceles.

When the skin is adherent, or in the case of large tumours of the testicle, *castration* is performed by means of a *transverse incision in the coronal plane* at the lower end of the scrotum. After dividing the skin and dartos between the larger visible scrotal vessels, the testicle is shelled out from its coverings. As the incision is parallel to the scrotal vessels, and parallel also to the branches of the spermatic vessels which ramify upon the surface of the tunica vaginalis towards its lower pole, it is a much more suitable incision than that which is generally employed, viz. a vertical incision, descending upon the anterior surface of the scrotum.

86. Herniotomy and the Radical Operation for Inguinal and Femoral Hernia. The incision for inguinal herniotomy is the same as that just described for exposing the spermatic cord, except that it is somewhat longer. The skin and subcutaneous tissue are divided a finger-breadth above the inner two-thirds of POUPART'S ligament. The superficial epigastric artery, and a vein (vena pubica) which descends farther inwards towards the middle line, are ligatured. The external

spermatic fascia of COOPER (prolonged down upon the cord from the margins of the external abdominal ring), the cremasteric and the infundibuliform fasciæ are divided one after the other, after which the neck of the hernial sac can be separated from the structures of the spermatic cord, and its fundus can be pulled out of the scrotum. By stretching out the structures of the cord and holding it up to the light, the outline of a thin hernial sac can be seen shining through it.

In performing a radical operation, the sac is carefully isolated and firmly drawn downwards until the part occupying the internal abdominal ring is reached, and ligatured by first transfixing it and then tying the two halves. On cutting across the sac below the ligature, the stump retracts quite into the abdomen. A series of deep sutures (canal sutures) are now passed through the external oblique and subjacent fibres of the internal oblique, in order to narrow the inguinal canal in its whole length.

We have employed this simple method of performing a radical operation for years, and with very good results. It corresponds essentially to that of LUCAS-CHAMPIONNIÈRE.

Our latest method for the radical cure (the displacement method—*Verlagerungsmethode*) of herniæ, in which the sac is not too large or its wall too thick, is the following:—

The incision is the same as that above described, viz. above and parallel to the inner two-thirds of POUPART'S ligament. The characteristically directed fibres of the aponeurosis of the external oblique are exposed, and the hernial sac is completely isolated in the way already described (Fig. 62). Now comes the characteristic and essential step of our method. A small opening (Fig. 63) is made in the strong portion of the external oblique above and external to the middle of POUPART'S ligament (above and external to the region of the internal abdominal ring), and a special pair of curved dressing forceps are pushed through it, *i.e.* through the aponeurosis of the external oblique and the muscular fibres of the internal oblique, and along the inguinal canal in front of the spermatic cord to emerge at the external ring, where they are made to seize the fundus of the isolated hernial sac (Fig. 63), which is drawn from below upwards and outwards along the canal and through the small opening above mentioned (Fig. 64).

Traction is now made upon the sac in an outward and somewhat upward direction away from the cord, and the funnel-shaped opening at the neck of the sac is drawn well into the small opening in the abdominal wall. The portion of the sac which is brought through the opening is now transfixed and stitched to the adjacent part of the abdominal wall. (In the illustration (Fig. 64) the sac should have been represented as drawn outwards and upwards, and the needle (1) which transfixes it is too small and should penetrate deeper. The external needle (2) should also pass through the whole thickness of the abdominal wall, because the suture which it introduces is intended to increase the

resistance of the wall.) The sac is now folded together and placed upon the *outer surface* of that part of the external oblique which forms the anterior wall of the inguinal canal, and is fixed to it by two or three sutures (Fig. 65). The remainder of the sac is cut away. The sutures which fix the sac should take as deep a grip as possible of the upper and lower walls of the canal, and should therefore pass immediately over the spermatic cord, which is kept pulled downwards, and protected by means of the finger introduced into the canal.

Recently, instead of placing the sac in the line of the canal, we have directed it *outwards towards the anterior superior iliac spine* and sutured it to the aponeurosis of the external oblique in order to stretch the peritoneum still more in an outward direction, and so make it impossible for a hernia to escape along the line of the spermatic cord. The operation is completed by passing a suture deeply through the internal ring, close to and beneath the neck of the sac; and canal sutures are introduced to shorten and strengthen the anterior wall of the canal in the region of the cord. We have given up the earlier practice of twisting the hernial sac, as it often led to necrosis.

This method has the great advantage that, unlike the much-favoured method of BASSINI, it does not slit up the inguinal canal. If once suppuration should occur, and the sutures fail to hold, then decided harm is done by BASSINI'S method; whilst by our method the result is still a good one in spite of it. Our method is also, as stated by ANGERER of Munich, much simpler and more rapidly performed, and is quite as well calculated to close the internal abdominal ring as BASSINI'S method. While in the latter the spermatic cord is displaced in order that the sutures may be accurately introduced, we displace the neck of the sac from its relation to the cord and introduce a suture which penetrates deeply, and completely closes the internal ring.

We are not prepared to give up this advantage of displacing the sac, as it solves in a very simple manner the problem of preventing the exit of a hernia by an opening which is normally present. We have adopted the same principle in *femoral hernia*.

Radical Operation for Femoral Hernia

An incision is carried along the inner third of POUPART'S ligament down through the skin, superficial fascia, and cribriform fascia, until the hernia, which is generally surrounded with fat, is exposed. The sac is completely isolated with a blunt instrument up to the crural ring. A small opening is made above POUPART'S ligament through the tense outer pillar of the external abdominal ring, and the curved forceps are introduced through it downwards behind POUPART'S ligament. The fundus of the sac is now seized, and the sac is drawn back through the strong

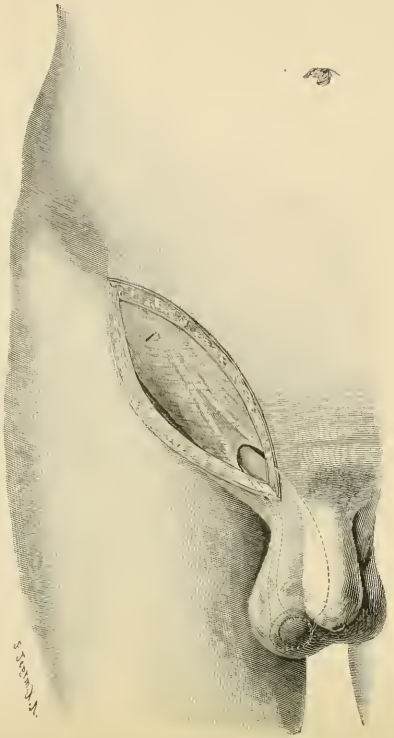

FIG. 62.

FIG. 62.—Radical operation for inguinal hernia. First step: exposure of the aponeurosis of the external oblique and of the sac.

FIG. 63.—Radical operation for inguinal hernia. Second step: the drawing of the isolated sac through the inguinal canal by means of curved forceps.

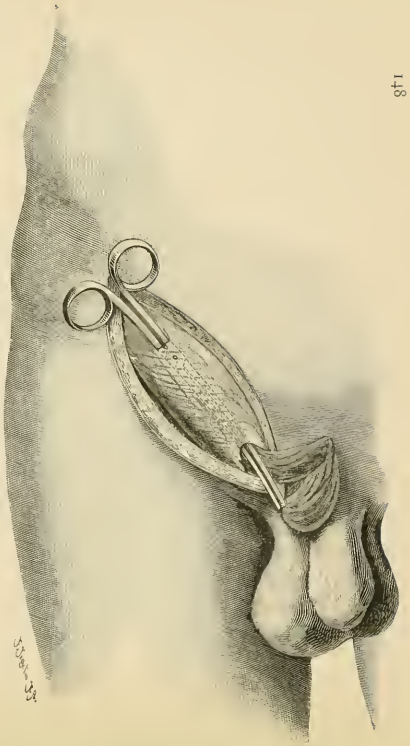

FIG. 63.

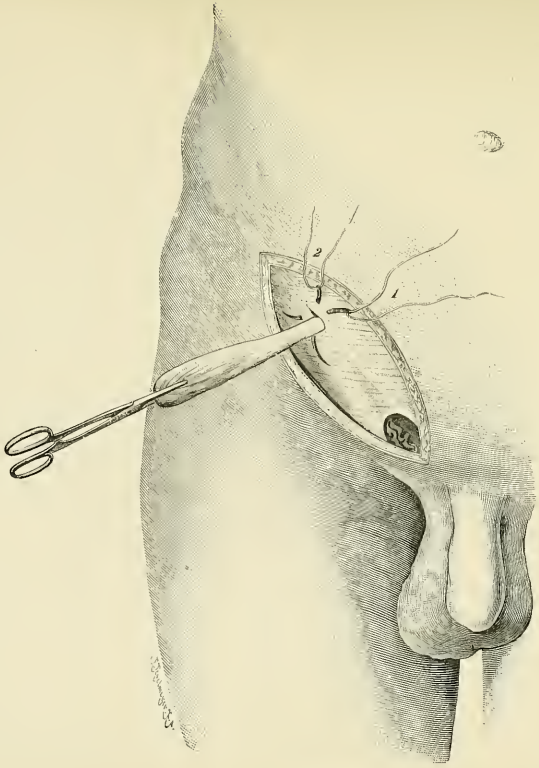

Fig. 64.

Fig. 64.—Radical operation for inguinal hernia. Third step: the hernial sac is drawn forward through the anterior abdominal wall and pulled well outwards and upwards (much more than is represented in the figure) towards the anterior superior iliac spine. The opening for the sac is closed by two deep sutures; (1) transfixes the neck of the sac; (2) passes through the whole thickness of the abdominal wall.

Fig. 65.—Radical operation for inguinal hernia. Fourth step: a portion of the sac is placed upon the aponeurosis of the external oblique, so that the anterior wall of the inguinal canal is pressed in forming a sort of gutter. The sac is then fixed in position by sutures which transfix it as they pass deeply through the upper and lower walls of the inguinal canal (canal sutures).

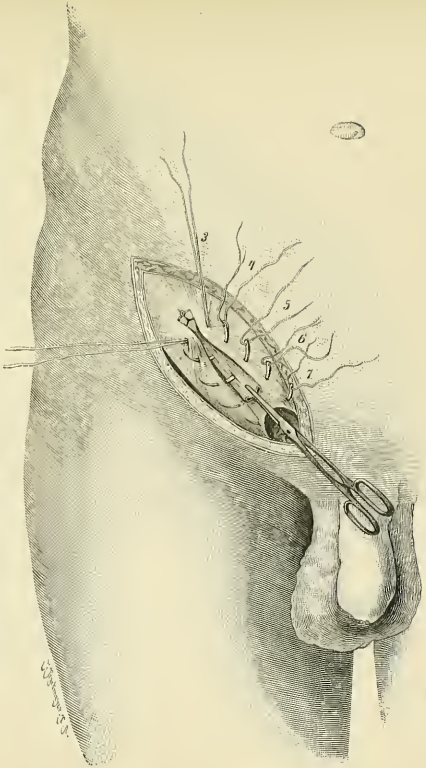

Fig. 65.

aponeurosis of the external oblique. A suture is then introduced through the edges of the opening and the neck of the sac, and firmly tied. The sac is fixed to the crural ring by passing sutures deeply through POUPART'S ligament, the deep crural arch (ligament of COOPER), the sac, and the pectineal fascia. By means of two or three such sutures POUPART'S ligament is made to act as a support and continuation of GIMBERNAT'S ligament on to the pectineal fascia as far as the femoral vein, beyond which the ring cannot be closed on account of the danger of setting up thrombosis. The superfluous part of the sac is cut off.

In femoral hernias with a broad base, just as in direct inguinal hernias, it is better to remove the sac high up, according to the method first described. There is no difficulty in completely closing the opening in direct inguinal hernia by sutures, because the spermatic cord is very little in the way.

In operating for inguinal hernia in the female the closure of the inguinal canal is a very simple matter, as we have no spermatic cord to deal with. The round ligament, however, with its accompanying vessel, lies close to the sac. It should be isolated and drawn out along with the sac external to the opening in the external oblique, and there fixed with sutures. The mere cutting it across may give rise to displacement of the uterus.

87. Isolation of the Round Ligament. Alexander's Operation for Prolapse (Fig. 66). The round ligament in the female is isolated in exactly the same way as the spermatic cord in the male; it is much more easily done however, because there is no cremasteric covering and no well-developed infundibuliform fascia. The line of incision will depend upon how the ligament is to be advanced and stitched, in order to counteract respectively *retroversion, retroflexion,* and *prolapse of the uterus.* We have had very good results from the following *modification of Alexander's operation.*

An incision is carried through the skin and superficial fascia parallel to and a small finger-breadth above the entire length of POUPART'S ligament. At the inner half of the incision the aponeurosis of the external oblique is divided, and the anterior wall of the inguinal canal opened. In the superficial fascia are the superficial epigastric artery, its companion vein, and a vein which descends vertically at the inner angle of the wound, all of which are tied. The round ligament, together with its accompanying vessels, can now be isolated and raised up with a director from the groove of POUPART'S ligament and from the accompanying fibres of the internal oblique and transversalis muscles. The ligament is freed from its peripheral attachments towards the symphysis, and then drawn well outwards towards the anterior superior iliac spine. In this way, as may readily be seen upon the cadaver, the uterus is drawn upwards and bent forwards, and when the operation is performed on both sides, it is so stretched in both directions that it remains fixed in its new position.

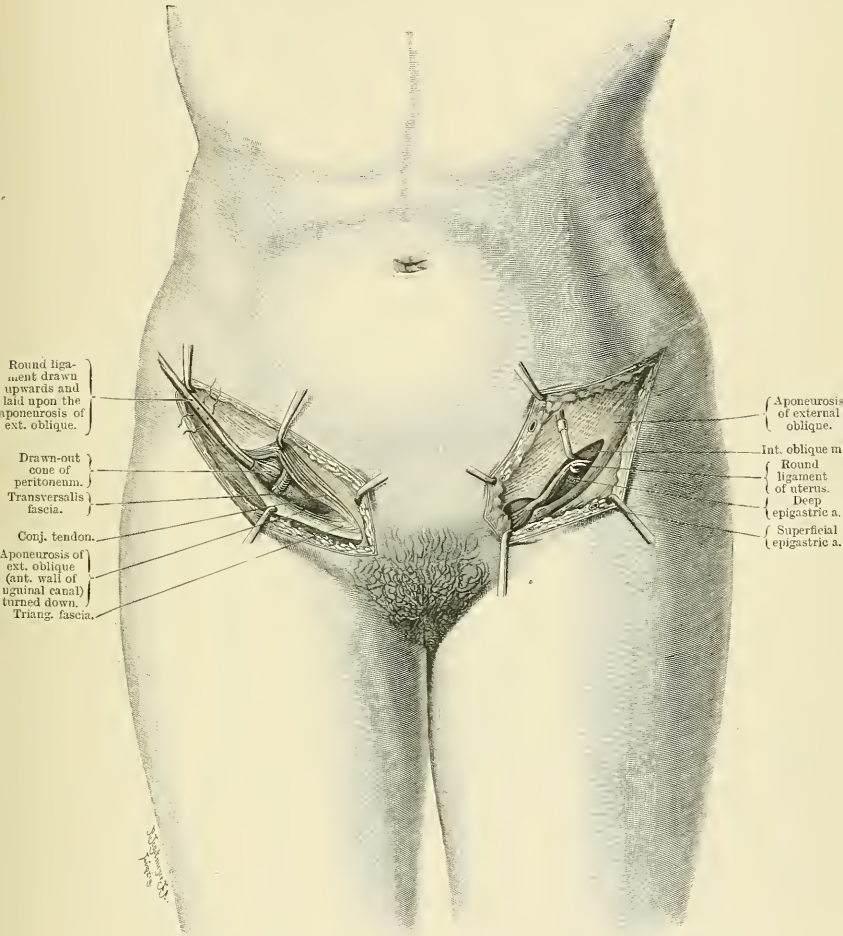

FIG. 66.—KOCHER's modification of ALEXANDER's operation for retroflexion and prolapse of the uterus.

A cone of peritoneum up to 3 cm. ($1\frac{1}{4}$ in.) in length is drawn outwards along with the round ligament, immediately to the outer side

of the deep epigastric artery. This cone can generally be pushed back with a director after well isolating the ligament, although it is true that the peritoneum is often torn during the process, in the event of which the opening must be closed by a suture. After we are satisfied that no viscus is drawn forwards into the cone, the round ligament is stitched by means of a continuous silk suture to the aponeurosis of the external oblique, above the outer half of POUPART'S ligament. The suture is begun at the anterior superior iliac spine, and is continued down to the internal abdominal ring, where it includes the peritoneal cone. The inguinal canal is then closed by deep sutures, uniting the upper cut edge of the external oblique aponeurosis, along with the fibres of the internal oblique and transversalis muscles and the conjoined tendon, to POUPART'S ligament.

88. Resection of the Vermiform Appendix (Figs. 67 and 68). We can only here give a description of an operation which will serve as a guide to resection of the appendix during the interval between recurrent inflammations; that is to say, in the absence of perityphlitic or paratyphlitic exudations and abscesses.

An incision is made three finger-breadths above the middle and outer thirds of POUPART'S ligament, and directed obliquely downwards and inwards so that the edge of the rectus is not reached at its lower extremity, and only the most anterior fibres of the broad abdominal muscles at its upper extremity. The incision divides the skin and fatty superficial fascia with the superficial epigastric vessels, the aponeurosis of the external oblique, and lastly, the most anterior fibres of the internal oblique and transversalis muscles, or simply their aponeuroses. The extra-peritoneal fat is now exposed and separated until the peritoneum appears. A small fold is then raised up with the forceps, and at first only a limited incision is made into it, because in the presence of adhesions there is a possibility of injuring the intestine; the opening is afterwards enlarged with scissors. The finger is now introduced, the cæcum brought out, and the seat of entrance of the ilium ascertained, as it is towards it that the origin of the vermiform appendix is to be found. The free portion of the appendix, which varies very much in position, is sought for and drawn forwards by proceeding towards it from the root. Its mesentery, along with the artery which ascends from its place of attachment, is ligatured, the former in successive portions, and detached from the appendix. The serous and muscular coats are divided circularly 1 cm. from its root and pushed back towards the cæcum, after which the mucous membrane is ligatured higher up with silk (Fig. 68), and the appendix completely severed with the thermo-cautery. The serous and mucous coats are now drawn purse-like over the stump of mucous membrane and there ligatured. The abdominal wound is closed by a row of interrupted buried sutures, including the peritoneum and muscles, and by a continuous suture for the skin.

In dealing with an abscess following perforation of the appendix, an incision is made over the dull area. The value of passing down between the matted intestinal coils as far as the appendix should always be kept in view, otherwise a superficial abscess may be opened, whilst the main abscess which is more deeply situated may be left untouched. The parts are thoroughly disinfected with a 1 per cent solution of lysol,

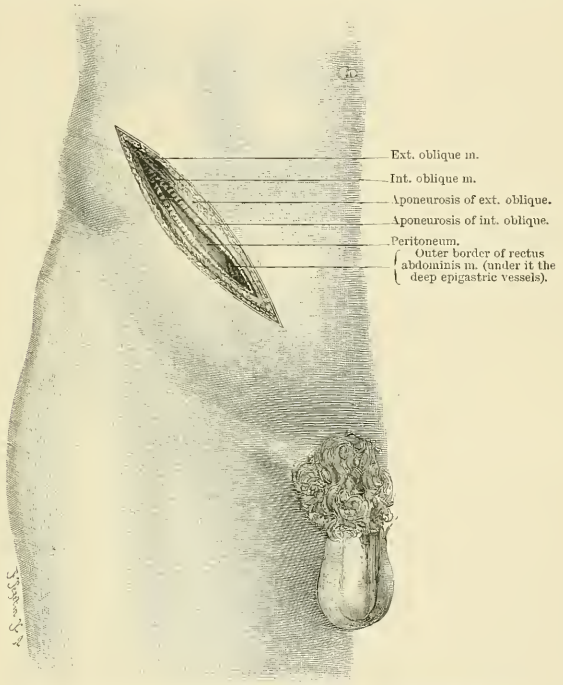

Fig. 67.—Resection of the vermiform appendix. Incision through the abdominal wall.

and when possible the perforated appendix is removed in the manner above described. On account of the suppuration, catgut is employed instead of silk for the ligatures.

89. Resection of the Ileo-Cæcal Region (Fig. 67). We have performed resection of the cæcum together with the lowest part of the ileum and sometimes more or less of the ascending colon with very good results in cases of tuberculosis and carcinoma, which occur not infrequently at the ileo-cæcal valve.

The incision is the same as that for removal of the vermiform appendix, except that it must be somewhat prolonged outwards and upwards when there are extensive adhesions. After opening the abdomen, the first thing to do is to free the cæcum by separating the thick masses of omentum which are adherent to the diseased intestine, and

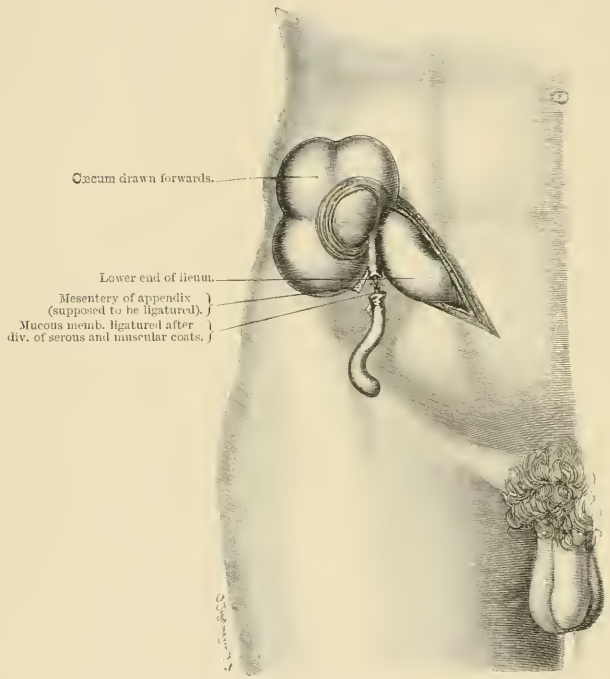

FIG. 68.—Resection of the vermiform appendix. Second step: the cæcum and lower end of the ileum are drawn forward: the mesentery and the serous and muscular coats of the appendix are divided. (In the figure, too long a piece of the appendix has been represented as left behind.

then to separate the cæcum from its connections with the fascia over the ilio-psoas. All bleeding must be carefully arrested, and the larger strands of omentum must be firmly ligatured before division.

If by this procedure the intestine has been rendered movable, it is drawn out of the wound and resected according to the rules given for resection of the intestine. If the separation of the omentum and of the

adhesions with the fascia does not suffice, then the mesentery, which may be infiltrated or thickened through infection of the glands, must also be divided after ligature of its vessels, so that the cæcum may be drawn out from the wound. The diseased bowel having been removed, there is apt to be an inequality in the width of the ileum and colon, which may, however, be compensated by hypertrophy and dilatation of the former resulting from the long-continued stenosis. In such cases we have never had any special difficulty in performing the simple end-to-end union of small and large intestine according to our method. In exceptional cases we have either divided the ileum more obliquely than usual so as to obtain a greater circumference, or, with the same object, made a small incision on the side opposite the mesentery. Only very exceptionally is it necessary to close the cut end of the colon and to make a special opening laterally to receive the ileum. The end-to-end union is much simpler and equally safe.

90. To make a Fæcal Fistula (Fig. 69). In all cases where the passage of flatus is arrested so as to lead to interference with breathing and imperfect absorption of chyme, the indication is to make a temporary fæcal fistula; this may also be done in complete intestinal obstruction, and in peritonitis. Many a life may be preserved by the time thus gained. If the operation be properly performed, it should be free from danger. It must not be too long postponed.

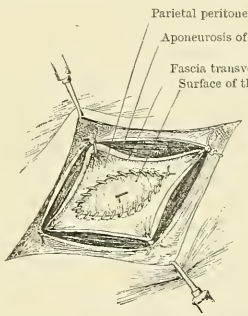

FIG. 69.—Formation of a fæcal fistula.

The position of the incision varies; preferably, however, it is made two to three finger-breadths above and parallel to the middle of POUPART'S ligament, and for a length of about 6 cm. ($2\frac{1}{2}$ in.). After dividing the abdominal wall down to the peritoneum, an opening 2 to $2\frac{1}{2}$ cm. (1 in.) in length is made in the latter. The distended intestine which is generally found presenting at the wound is to be so arranged that it fills up the wound without, however, being allowed to project beyond it. The intestine is now fixed to the abdominal wall by means of an interrupted suture placed at each of the four corners of the wound. These sutures pass through the serous coat of the intestine and the parietal peritoneum (at some distance from the edges of its opening), then through the fascia transversalis and the aponeuroses of the abdominal muscles. The serous coat of the intestine is now stitched to the edges of the parietal peritoneal opening by means of a fine continuous silk suture,

which hermetically presses together the two serous layers. The intestine is opened by rapidly plunging a fine knife into it, after which a probe is introduced to make sure that the lumen has been properly reached. Iodoform or aristol powder is rubbed into the wound, which is then covered with warm moist 1 : 1000 salicylic gauze, which should be frequently changed.

91. To make an Artificial Anus (Fig. 70). For the purpose of emptying the intestine temporarily in tympanitis, a small fæcal fistula always suffices. An artificial anus is made, however, when a permanent escape of the intestinal contents is desired, and when it is intended to prevent the contents from passing into the bowel below the opening. The operation is performed in the following manner. An incision is carried outwards from a point two finger-breadths above the middle of POUPART'S ligament on the left side. The abdominal muscles and the fascia transversalis having been divided as above described for fæcal fistula, the peritoneum is opened to a more limited extent, and a complete loop of the sigmoid flexure (in inoperable carcinoma of the rectum) is drawn out of the wound. It is most important to satisfy oneself as to which is the proximal and which the distal portion of the loop. The loop is now stitched to the edges of the opening in the parietal peritoneum with a continuous silk suture, in such a way that plenty of room is given for the proximal part of the loop, which in its turn is made to compress the distal portion (this condition is not represented in the illustration). A triangular piece is now removed from the convexity of the loop up to the attachment of the mesentery. When the case is not an urgent one, the opening of the intestine should be deferred for two days, that is to say, until adhesions have formed.

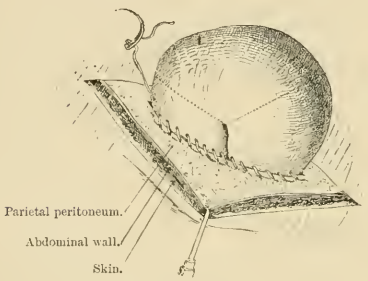

FIG. 70.—Formation of an artificial anus.

92. Resection of the Intestine (Figs. 71, 72, and 73). Resection of the intestine has become an exceedingly important and comparatively frequent surgical operation, by the proper performance of which the surgeon is able to preserve many lives which would be otherwise lost. It is absolutely necessary that besides attending to the obvious necessity of asepsis, the definite steps in the technique of the operation must be adhered to.

By observing these rules, large portions of the bowel may be removed. We have performed a considerable number of very extensive

intestinal resections, the most extensive being the removal of 7 feet of small intestine, and in another case 5 feet 4 inches. Both patients made an uninterrupted recovery. It is important to know that such very extensive resections can be performed without doing any harm, and with uninterrupted recovery, because the first rule in intestinal as in stomach resections is this: *only to suture together wound edges which are thoroughly well nourished.* Before the sutures are introduced one must be absolutely certain that plenty of blood is flowing to and from the mesentery at the ends of the intestine which are to be united. If we are not certain of this, it is far better to resect a further portion of intestine before proceeding with the suturing.

In view of this all-important rule, the mesentery also—as we were the first to mention—is never to be divided elsewhere than along its attachment to the intestine. No additional incisions are to be made towards its root. Where one cannot be absolutely certain that a free entrance and exit of blood from both ends of the intestine are guaranteed, then no suturing is to be risked, but the operation must be postponed until time has been allowed to prove whether or not the affected portion of intestine is viable. The ends of the intestine are stitched to the abdominal wall, so as to form a temporary artificial anus. Whenever we have departed from this rule, we have always had cause to regret it. In resections of the ascending and descending colon, of the lower part of the sigmoid flexure, and of the commencement of the rectum, it is often difficult to decide whether the edges of the intestine possess an absolutely secure circulation, and in such cases the roundabout plan of making an artificial anus and performing secondary intestinal suture at a later date is the only treatment which is calculated to bring about a successful issue.

If we are of the opinion that the ideal intestinal resection (immediate union) may be safely performed, the following rules are to be observed:—

1. The piece of intestine to be resected is to be drawn well out of the abdominal cavity, so that the operation may be performed extra-peritoneally and leisurely. The entrance of fluid into the abdominal cavity is to be prevented by carefully packing soft cloths moistened with sterilised ·75 per cent salt solution round the loop of intestine.

2. Two clamps are applied close together to the part of the intestine where the section is to be made (Fig. 71), a part being chosen where the wound edges will be well nourished. These clamps are not to be applied exactly at right angles to the long axis of the intestine (as has been erroneously represented in Fig. 71), but somewhat obliquely, as indicated by the dotted line in the same figure, so that more intestine is removed from the convexity than from the mesenteric side. The transverse vessels which run towards the convexity are thus more likely to escape injury. Experience has shown us that it is not necessary to cover the blades of the clamps with india-rubber, and

that they may be securely closed and pressed together without doing any harm.

3. The intestine is cut through between the clamps, and the cut surfaces carefully mopped with moist sublimate swabs (1 : 1000). The mesentery (mesocolon, mesosigmoid) is then divided *along its attachment to the part of the intestine to be removed*, the vessels being seized one after another with artery forceps. The intervening piece of intestine with a clamp at each end is thus removed.

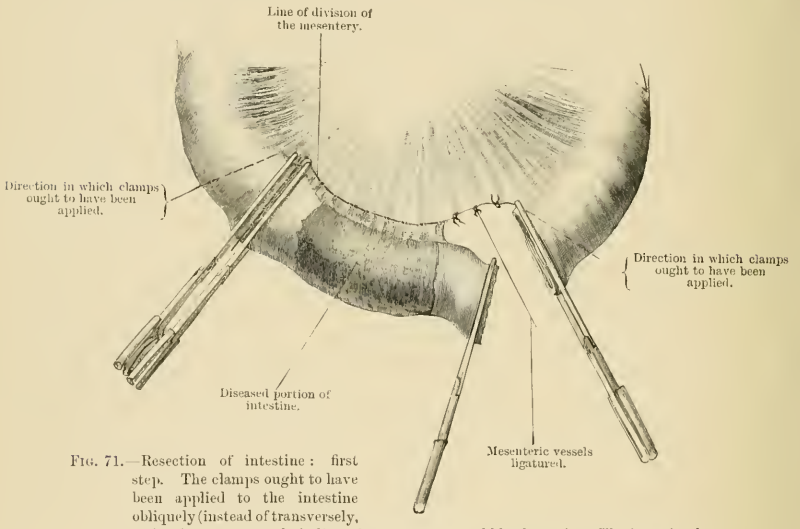

FIG. 71.—Resection of intestine: first step. The clamps ought to have been applied to the intestine obliquely (instead of transversely, as has been erroneously indicated) to ensure a good blood supply. The intestine has been cut across between two of the forceps, and between the other two the line of section is indicated by an interrupted line. The line of division of the mesentery is shown, part of it having been divided and its vessels ligatured.

4. The intestinal contents of the ends to be united are now pressed along the lumen of the bowel away from the clamps, and the emptied portions having been grasped between the index and middle fingers (Fig. 72) the clamps are removed and the two intestinal openings disinfected with sterilised gauze swabs.

5. Now comes the end-to-end suturing of the intestine. In order to ensure the approximation of corresponding parts of the intestine, two *fixation sutures* are first introduced, one at the mesenteric attachment, and the other at the convexity. In this way the lumina are brought into accurate apposition, and are retained there by pulling upon the ends

Fig. 72.—Resection of intestine: second step. The diseased piece of intestine has been removed; the ends of the intestine are compressed between the assistant's fingers, and fixed in position by two fixation sutures, one at the concavity and the other at the convexity; the posterior continuous suture has been introduced through the whole thickness of the wall.

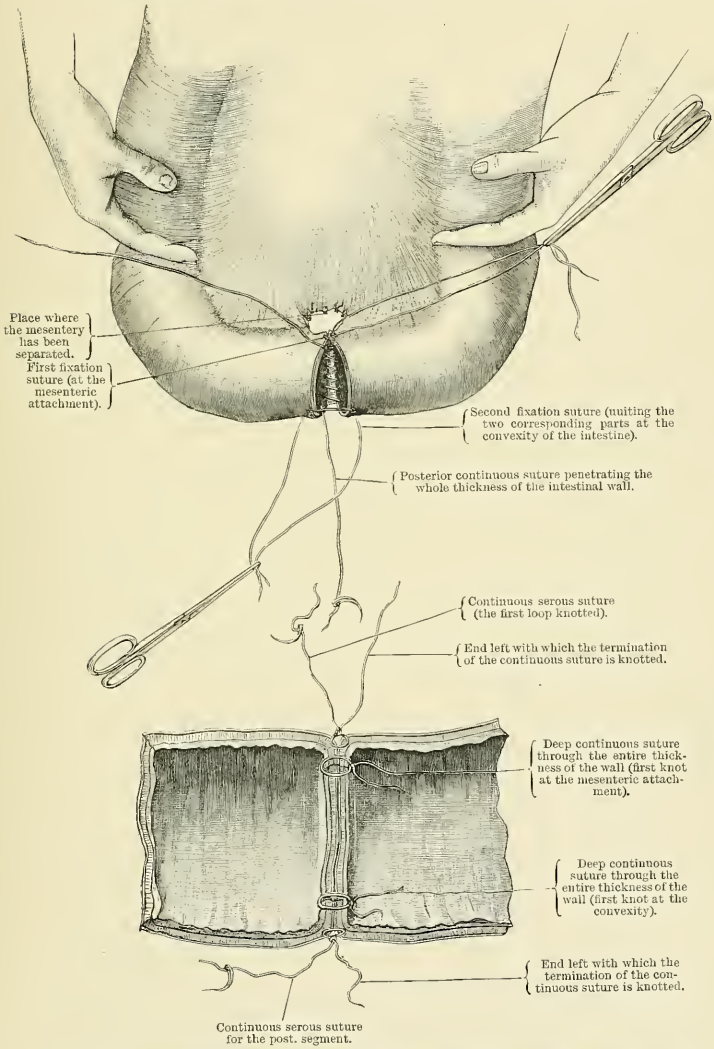

Fig. 73.—Intestinal suturing: to demonstrate the double row of sutures; posterior half of gut cut longitudinally; viewed from within.

of the sutures (Fig. 72). The continuous suture which follows penetrates the whole thickness of the intestinal walls, but takes a wider grip of the serous than of the mucous layer. The ends of the first loop having been knotted, the one is left long enough to tie with, while the other, to which the needle is attached, is used to bring the edges of the gut into uninterrupted and firm contact by means of a simple continuous glover's suture carried right round the circumference to the starting-point, where it is knotted with the end which has been left long. The intestine is thus firmly and securely closed. The line of suture is cleansed with sublimate swabs, and the protruded intestine washed, first with a 1 per cent solution of lysol, and then with a warm (98·6° F.) sterilised salt solution, the surrounding cloths preventing the disinfectants from reaching the abdominal cavity.

6. Fresh cloths are now substituted for the soiled ones, and the real *uniting suture* applied (the suture above described may be designated the *fixation suture*), with the finest possible needle, and fine but strong silk. The suture penetrates only the serous and a part of the muscular coats in such a way that the former are inverted and brought into broad position—the well-tested LEMBERT'S suture. The double suture (indicated in longitudinal section in Fig. 73) was first described by CZERNY, and then by us without knowing that he had employed it.

The first loop of the uniting suture is knotted and is then carried uninterruptedly right round the intestine, and knotted with the initial end which has been left long. The line of suture is again disinfected with sublimate, and the protruding intestine and mesentery washed with lysol, which is then removed by a warm sterilised salt solution. The towels having been removed, the intestine is put back into the abdomen, care being taken not to use any force. The abdominal wall is closed with a double row of sutures.

If the intestine is so distended with flatus and fluid contents that its reduction is rendered difficult, it should be opened above the line of suture by a transverse incision 3 to 4 cm. ($1\frac{1}{2}$ in.) in length, and the contents allowed to flow into a small glass dish, after which the opening is stitched up. The part is again cleansed as above described, and the reduction of the intestine effected.

We maintain that continuous sutures are alone permissible in enteroraphy, and fine silk is to be exclusively employed.

Operations on the Bladder

93. Suprapubic Cystotomy. An incision above the symphysis is nowadays the normal method of opening the bladder for the very various conditions in which cystotomy is indicated, because, unlike the perineal operation, it admits of the possibility of primary healing. The normal incision is carried transversely along the fold above the symphysis and

divides the skin, the thick layer of fat, and the deep fascia, and exposes the muscular fibres of the recti. By elevating the pelvis according to the plan recommended by TRENDELENBURG, a very clear view of the surface and interior of the bladder is obtained. Some veins which lie vertically in front of the bladder must be divided and ligatured. In order to get plenty of room without bringing the peritoneum into danger, the soft parts above the symphysis are freely divided by a curved incision extending from above one inguinal canal to the other. The origins of the recti and pyramidales are detached to a considerable extent from the symphysis, and in addition a longitudinal incision is carried through the linea alba and between the recti. The finger is now introduced behind the symphysis so as to draw upwards the thin fascia, the extra-peritoneal fat, and along with it the reflexion of the peritoneum, which can either be seen or felt as a transverse fold or projection.

By means of this manipulation, combined with elevation of the pelvis, distension of the bladder or of the rectum is quite superfluous; indeed the latter plan is attended with a danger of rupturing or injuring these organs when they are diseased. It is desirable to pass a loop of silk through the entire thickness of the muscular coat at the lowest part of the bladder which can be conveniently reached; a second loop is similarly passed through the muscular coat below the line of reflexion of the peritoneum. The introduction of these two fixation sutures greatly simplifies the subsequent suturing of the empty bladder.

The muscular coat of the bladder is divided vertically between the two fixation loops until the mucous membrane is seen to bulge forward in the form of a bluish vesicle. The bleeding having been arrested, the bladder is opened by plunging the knife through the bulging mucous membrane. The finger is introduced into the opening before all the fluid is allowed to escape. The opening may now be enlarged to suit the necessity of the case, for example, to admit of the removal of a calculus or a new growth, or of the mere inspection and digital exploration of the bladder. The mucous membrane, on account of its greater extensibility, does not require to be so freely divided as the muscular coat.

The bladder is closed by a double row of silk sutures, of which the first row includes the mucous membrane only. The superficial one, also continuous, includes both the muscular coat and the superjacent cellular tissue. Finally, the external wound is closed.

Before the operation the bladder is thoroughly washed out and filled with 5 to 7 ounces of a boiled 4 per cent solution of boracic acid at 98·6° F.

For the after-treatment a NÉLATON'S catheter is introduced along the urethra and retained in position by a silk suture passed through the frænum. The urine is conveyed by a rubber tube into a vessel containing a 5 per

cent carbolic or a 1 : 1000 sublimate solution. The catheter is kept in for eight to fourteen days, that is to say, until the bladder wound is healed. A glass drainage-tube is introduced into the wound as far as the bladder through a separate opening; in exceptional cases it is kept in for eight to ten days.

94. Opening the Bladder, with Resection of the Symphysis. If a large transverse incision does not give sufficient room for operations in and upon the bladder (especially in the region of the vesiculæ seminales and of the prostate), it is best, after detaching the origins of the recti and pyramidales superiorly, and the obturatores externi below and externally, to resect subperiosteally a triangular portion from the symphysis with a broad base above and its apex below towards the pubic arch, the periosteum being well separated posteriorly (HELFERICH). This procedure does no harm to the rigidity of the pelvis. BRAMANN leaves the resected piece of bone from the symphysis connected with the muscles (temporary resection). Dr. NIEHAUS performs the resection only on one side of the symphysis.

95. Puncture of the Bladder. As puncture of the bladder is only called for in retention of urine with marked distension, it is made in the middle line 3 cm. ($1\frac{1}{4}$ in.) above the symphysis, *i.e.* about the middle of our normal transverse suprapubic incision. The trocar is directed backwards and somewhat downwards for a depth of 4 to 6 cm. ($1\frac{1}{2}$ to $2\frac{1}{2}$ in.)—according to the amount of fat in the abdominal wall—until the urine escapes.

When the bladder requires to be emptied only once,—or even several times, provided there is a prospect of soon restoring the outflow along the normal channel,—the simple POTAIN'S aspirator with a long canula is employed. If the urine has to be withdrawn suprapubically for a longer period (as in certain prostatic and urethral diseases), a larger curved trocar is employed, the calibre of which must be large enough to admit of the introduction of a rounded-off canula through it into the bladder, so that the edge of the trocar will not injure the bladder wall.

P. PERINEUM

Anatomically the perineal region is somewhat complicated, especially as regards its fascia.

Operations on the perineum are performed for the purpose of exposing the lower part of the rectum, the urethra, the prostate, the vesiculæ seminales, the floor of the bladder, the vagina, and the uterus. For years, however, cutting for stone was the prevailing operation.

96. Up till recently **Perineal Lithotomy** was admitted to be the normal operation, and the only question that had to be considered was which of the various modifications (lateral, bi-lateral, or median) was most

suitable. The reason why the perineal incision was so long employed was that it assured at any rate a free escape of the urine and discharges from the wound, so that the danger of infection was not increased by their infiltration into the tissues, whilst by the suprapubic incision infection of the wound could not be prevented.

At the present time, however, the only distinct indication for perineal lithotomy is afforded by those rare cases in which small stones cannot be removed by litholapaxy, and are not small enough to pass along the urethra.

In this case the membranous portion of the urethra is opened by an incision the same as that for external urethrotomy. The latter is performed not only in rupture of the urethra, in strictures, and in urinary fistulæ, but also for the purpose of exploring the bladder with the finger, and lastly for the removal of foreign bodies from the bladder and from the urethra. Abscesses and new formations in connection with the prostate and vesiculæ seminales afford further indications for the perineal incision.

The prostate, apart from its middle lobe which often projects into the bladder, is best reached from the perineum, by a method which has been practised by DITTEL and ZUCKERKANDL.

Diseases of the uterus are dealt with from the vagina; those from the rectum are treated preferably by a posterior incision (see surgery of the posterior region of the pelvis). The prostate and vesiculæ seminales can also be very conveniently reached by dissecting down in front of the rectum from this posterior incision.

97. To open the Spongy and Bulbous Portions of the Urethra. A mesial incision is made down to the fibrous envelope of the corpus spongiosum. If the latter is not diseased, and does not need to be slit up or in part removed, then one edge of the wound is drawn aside and the urethra is opened through its lateral wall close to the bulb.

98. To open the Membranous and Prostatic Portions of the Urethra. Normal incision for obtaining free access (Figs. 74 and 75). This operation also gives access to the prostate, vesiculæ seminales, and the vasa deferentia. The external incision must be here an extensive one, so that the median incision is no longer suitable. A purely lateral incision, as formerly employed, divided the branches of the internal pudic artery and nerve passing towards the middle line, viz. posteriorly the inferior hæmorrhoidal vessels and nerves, anteriorly the superficial perineal vessels and nerves and the artery to the bulb. Although the sacral resections have shown that unilateral division of these nerves does not necessarily lead to permanent motor disturbances, nevertheless they should, if possible, be avoided, and the *transverse curved incision* should therefore be looked upon as the normal incision for obtaining free access. This is a curved incision carried from one ischial tuberosity to the other, its convexity reaching forwards to the lower border of the pubic symphysis.

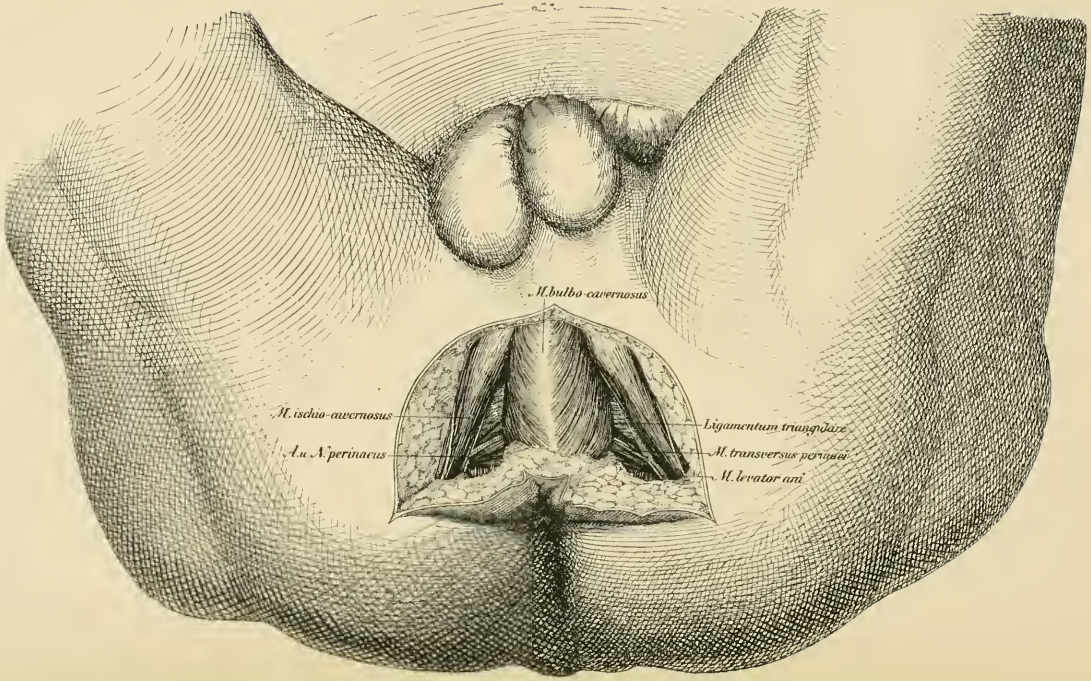
M. bulbo-cavernosus
M. ischio-cavernosus
A. u. N. perinaeus
Ligamentum triangulare
M. transversus perinaei
M. levator ani

Fig. 74.

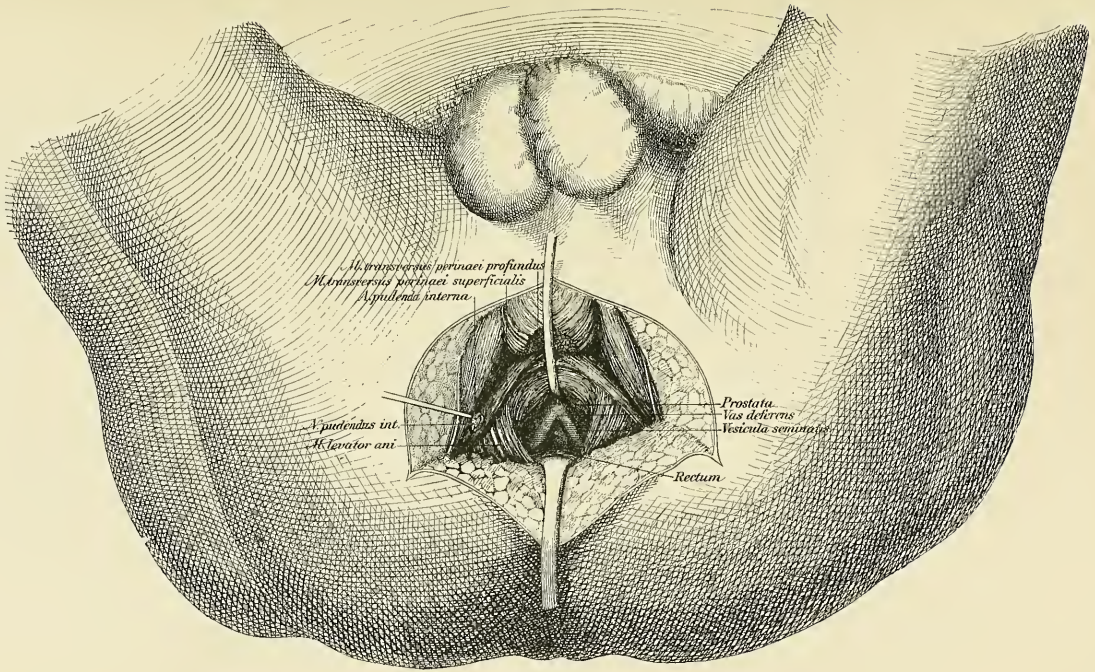
M. transversus perinaei profundus
M. transversus perinaei superficialis
A. pudenda interna
N. pudendus int.
M. levator ani
Prostata
Vas deferens
Vesicula seminalis
Rectum

FIG. 75.

After dividing the skin and thin superficial fascia, the incision comes down laterally upon the fatty tissue which is continued upwards into the ischio-rectal fossa between the pelvis and the rectum. This fatty tissue is now dissected through as far as the under surface of the levator ani, the fibres of which extend from before backwards and from without inwards towards the rectum. In doing this the inferior hæmorrhoidal vessels and nerve situated posteriorly, and the transverse perineal vessels and nerve, the artery and nerve to the bulb, and the transverse superficial perineal muscles, all situated anteriorly, are pushed forwards and drawn out of the way. The bulb of the urethra and the muscular fibres of the accelerator urinæ, which extend forwards and outwards from either side of the median raphe, are exposed at the anterior part of the wound. The fibres of the transverse perineal muscles extend from the posterior end of the bulb outwards and backwards towards the ascending ramus of the ischium. The fibres which connect the external sphincter ani and the accelerator urinæ at the central point of the perineum are divided transversely close to the bulb, which is then drawn forward along with the transversales perinei. By cutting transversely and more deeply towards the posterior surface of the bulb, the posterior fibres of the compressor urethræ muscle, which covers the under surface of the membranous urethra, are exposed. Above this muscle is the prostate, which is covered on its postero-inferior surface by a dense layer of connective tissue (part of the capsule of the prostate, derived from the pelvic fascia) containing non-striped muscular fibres. This layer must be drawn downwards and divided transversely, the smooth posterior surface of the prostate being thereby exposed, so that the finger can now be pushed upwards upon it as far as its upper border. Still deeper the vasa deferentia may be easily recognised converging downwards and forwards, and lying immediately outside these the vesiculæ seminales, which may be dissected out with a blunt instrument.

By drawing backwards the rectum with a long blunt hook, a layer of connective tissue with fibres of the levator ani is put on the stretch upon either side.

99. Internal Pubic Artery and Nerve in the Perineum (Fig. 75). An incision is begun at the inner border of the tuber ischii and carried forwards along the edge of the ascending ramus. The skin and fascia are divided, avoiding, however, the branches of the long pudendal nerve to the scrotum. The muscular fibres of the erector penis are exposed, and the transverse perineal muscle is either cut across close to its origin from the ascending ramus, or drawn downwards and inwards. On dividing the base of the triangular ligament and the adjacent parietal pelvic fascia, the artery will be found passing forwards upon the inner surface of the obturator internus muscle above the attachment of the great sacro-sciatic ligament; the internal pubic nerve accompanies the artery, lying upon its superficial aspect.

Q. SACRAL REGION

The surgery of the sacro-coccygeal region has attained greater interest since it has become recognised that access to the pelvic organs from behind is for many reasons preferable to that to be obtained from the perineum.

100. Excision of the Rectum by a Posterior Longitudinal Incision. In the extirpation of new growths it is better to expose the rectum from behind. The same route is chosen in exposing the upper part of the vagina, the uterus, the prostate, the floor of the bladder, and the vesiculæ seminales. After VERNEUIL proposed excision of the coccyx in operating for imperforate anus, we carried out a similar procedure in operating for carcinoma of the rectum. KRASKE has since gone a step further and partially resected the sacrum; and HOCHENEGG, BARDENHAUR, and ROSE have gone as high as the second sacral foramen. By employing the parasacral incision, we again have endeavoured to limit greatly the injury to the bone by resecting only the coccyx.

Twenty cm. (8 in.) or more of the rectum may readily be excised from behind. The patient must previously be well purged for several days, then during the two days preceding the operation the colon is kept empty by large doses of bismuth along with some opium.

The skin incision (normal incision) is begun outside, and as a rule to the left of the gluteal cleft at the hollow between the sacrum and the projecting gluteus maximus, two finger-breadths below the posterior superior iliac spine, and is carried downwards to the middle line and along it past the tip of the coccyx to the posterior edge of the anus, which it encircles to terminate at the perineal raphe.

Part of the origin of the gluteus maximus is divided, and the edge of the sacrum having been exposed, the ligaments and the other muscles are divided at its edge and the dissection continued more deeply (ZUCKERKANDL, WÖLFLER). A better view is got when the coccyx is excised according to the method of VERNEUIL for imperforate anus, and according to the plan introduced by KOCHER for excision of the rectum. When necessary, a portion of the sacrum is also resected, be it only the left edge, or a piece extending up to the fourth, the third, or even the second sacral foramen (KRASKE). We may go up, on one side at any rate, as far as the second sacral foramen without permanent injury, and this in spite of the fact that the nerves to the bladder and rectum proceed from the fourth and fifth sacral nerves, and the pubic from the third sacral.

If no bone is resected, then the greater and lesser sacro-sciatic

ligaments are detached from the left edge of the sacrum, and from both edges of the coccyx; and the following muscular attachments are divided from above downwards, viz. the pyriformis, the coccygeus, and (below the apex of the coccyx) the levator ani and external sphincter. When the coccyx is to be removed, its apex is seized by a sharp hook and disarticulated with a resection knife; when a portion of the sacrum is to be resected, it is divided with a hammer and chisel, and the lower part dissected out in one piece along with the coccyx. Active bleeding often occurs at this stage, not only from the divided bone, but more especially from the middle and lateral sacral arteries, the former arising from the aorta, the latter from the internal iliac. As these vessels lie close to the sacrum they are sometimes difficult to secure and ligature, and temporary plugging may have to be resorted to. When the anal portion of the rectum is to be shelled out, the external and internal sphincters and the levator ani are divided by a vertical mesial incision at the lower end of the rectum, and dissected off to either side with a blunt instrument, whereby spurting takes place from the inferior hæmorrhoidal arteries.

To expose the rectum higher up, the most essential point, in the first place, is to thoroughly separate its connections with the anterior surface of the sacrum and the sacro-coccygeal muscles and ligaments; and secondly, to thoroughly divide the peritoneum in the region of the fold of DOUGLAS, which in the male reaches down to the upper border of the prostate, in the female as far as the fornix vaginæ. After division of the peritoneum, the rectum can be so far drawn down that a part situated 20 to 25 cm. (8 to 10 in.) above the anus can be stitched to the margin of the latter without any force having to be applied. In separating the rectum farther upwards, branches of the middle hæmorrhoidal artery (from the internal iliac) and of the superior hæmorrhoidal (from the inferior mesenteric) are to be ligatured; the former are situated lower down, the latter higher up, the larger branches lying laterally. When the pre-sacral fascia has been divided and the lateral and posterior vessels have been ligatured, the rectum can be drawn out of the wound with a large blunt hook; and after dividing the pre-rectal layers of fascia, the upper part of the prostate, the vesiculæ seminales, and the lower ends of the vasa deferentia together with the base of the bladder can be distinctly seen. The lower end of the ureter can be exposed a little to the outside of the upper end of the vesiculus seminalis.

In cases of movable carcinomata of the rectum which are within the reach of the finger, the skin and fatty subcutaneous tissue and the muscular fibres of the levator ani and external sphincter are divided from the anus up to the sacrum. The finger is then passed along either side of the rectum so as to free it laterally, the firmer (vascular) strands being hooked up with the index finger and cut across between two ligatures. The rectum is then drawn as far downwards as possible by pulling upon it

above the anus; the more its connections with the sacrum are divided, the easier can this be done.

In this way the bowel is freed without appreciable loss of blood, and the indurated carcinomatous portion which has been exposed from the outside is drawn downwards. The muscular coat is now divided 3 to 4 cm. higher up, and the vessels ligatured. In order to shut off the lumen of the bowel above, a silk ligature is tied round it above the level at which the muscular coat has been divided. Below this point the mucous membrane is divided with the thermo-cautery and the upper and lower cut edges disinfected with the same instrument. The cancerous portion, together with the mucous membrane, is separated from its surroundings downwards as far as the anus. The tied part of the rectum above the tumour is sutured to the freshly-pared muscular margin of the anus; the suture is allowed to remain until it cuts its way out.

In this way—provided the intestine was thoroughly emptied and disinfected—the wound can be safely protected from any infection with intestinal contents both during and for the first few days after the operation.

By way of supplementing the above, we shall now give the steps of an operation as dictated during its performance for a typical case of carcinoma, situated at some distance within the rectum.

Excision of the Rectum by Parasacral Incision

The incision is begun 2 cm. behind the posterior margin of the anus, and extends to the upper end of the gluteal cleft, and from thence upwards and to the left as far as the posterior inferior iliac spine. The incision is carried through the skin and thick layer of subcutaneous fat down to the posterior surface of the coccyx and lower part of the sacrum. The gluteus maximus, which appears 4 cm. ($1\frac{1}{2}$ in.) above the coccyx, is separated from the sacrum. At the lower part of the wound (4 cm. above the margin of the anus) are the posterior fibres of the external sphincter, which are divided downwards as far as the lower angle of the wound, and beneath its lower part is the pale internal sphincter, which is also divided, whilst in the fatty tissue above it one or two vessels must be secured. On separating the fibrous tissue at the tip of the coccyx the terminal portion of the middle sacral artery is divided.

The left edge of the coccyx is exposed by dividing the fibrous and fatty tissue which covers it. Below the tip of the coccyx a thick layer of muscle (origin of the external sphincter ani) must be divided until the wall of the rectum itself appears. The finger is now carried upwards at the edge of the coccyx between the rectum and the muscles and ligaments

attached to it, and these are then divided, the coccygeus muscle being first encountered. Numerous vessels running transversely at the edge of the coccyx and others farther up at the edge of the sacrum are secured, and the gluteus maximus is exposed at its sacral origin. Beneath the lowest part of the gluteus maximus is the great sacro-sciatic ligament, and beneath it the lesser sacro-sciatic ligament, both of which are divided. After dividing these ligaments and the coccygeus muscle, the rectum, which appears as a smooth projection, is to be completely freed from the coccyx with the fingers. Some vessels which lie in the fatty tissue on either side bleed freely and require to be ligatured. The finger can now be passed without difficulty round the rectum, which is drawn out in the form of a loop, around the lower end of which a strip of iodoform gauze is tied for purposes of traction. The lower end of the rectum is now thoroughly cleaned out from the anus and stuffed with iodoform gauze. The fatty and fibrous tissues which lie on either side of the rectum are tied in successive portions between two ligatures and divided. The strong fatty connective tissue connecting the posterior surface of the rectum to the anterior aspect of the sacrum is ligatured and divided in the same way, otherwise free bleeding occurs. In this way the posterior surface of the rectum can be isolated high up until the entire tumour is felt and the healthy rectum above it can be freed all round without injuring the peritoneum.

In separating the rectum on its anterior aspect the fold of peritoneum is opened on the left side. In order to get more space the coccyx must be dislocated to the right side. From the opening in the peritoneum the rectum is now separated from the bottom of the pouch of DOUGLAS, and having thus become movable it is drawn farther downwards, when the vessels embedded in the fat on its posterior surface come into view and are ligatured. When the peritoneum has been completely separated, the rectum can be drawn down so that the bowel may be closed by tying a silk ligature around it *above* the tumour; the ligatured part is then pulled down as far as the tip of the coccyx. The peritoneal cavity is now shut off by stuffing the opening with gauze, and the lower end of the rectum is divided in the following manner. The muscular coat is separated from the rectal wall and pushed back as far as the anus, so that the sphincters are retained and preserved as far as possible, the mucous membrane alone being shelled out, as it were, down to the anal margin, and there divided. And now, as the posterior part of the sphincter has not been completely divided, the lower part of the rectum, still closed with iodoform gauze, is drawn downwards through the sphincter, and the part above the ligature (which was tied round the rectum above the tumour) is stitched by a ring of interrupted sutures to the anal margin. Lastly, the drawn-out part of the rectum is removed by cutting it across transversely with the thermo-cautery *below* the silk ligature, which is left tied round the rectum and allowed to cut its way out. The mucous

membrane which projects from the anus below the silk ligature is disinfected by the thermo-cautery so as to prevent the intestinal contents from contaminating the wound for the first few days.

A strip of iodoform gauze is placed against the opening in the peritoneum, the end being brought out at the upper angle of the wound. The remainder of the wound is stuffed with two other strips of gauze brought out at its lower angle. The edges of the wound are then brought together by interrupted sutures, and an iodoform gauze dressing is applied so as to cover the anus as well as the wound.

R. UPPER EXTREMITY

(a) Region of the Shoulder

101. Ligature of the Axillary Artery (Figs. 76 and 77).

By a transverse incision below the clavicle (Fig. 76). The incision is made 1 cm. below the middle third of the clavicle, dividing the fibres of the platysma together with the sensory *clavicular nerves*. In dividing the fascia, the *cephalic vein* at the anterior edge of the deltoid is to be avoided. The clavicular fibres of the pectoralis major are now divided, and the cephalic vein, together with the branches of the acromio-thoracic artery and the anterior thoracic nerves, is drawn upwards. The nerves are small; they appear below the clavicle, and cross the vessels to supply the pectoral muscles. The costo-coracoid membrane is divided below the clavicle, and the upper edge of the pectoralis minor is exposed. The *axillary vein* now appears, and externally the *cords of the brachial plexus*. The most superficial of the larger nerve trunks alongside the vein is the outer head of the median. After freeing it along its inner edge, the artery comes into view underneath it in the angle between the clavicle and the upper border of the pectoralis minor, lying upon the serratus magnus muscle.

By a longitudinal incision (Fig. 77). The surface guide to the vessel is afforded in this situation by the visible and palpable hollow between the deltoid and pectoralis major muscles. The incision is begun over the junction of the outer and middle thirds of the clavicle, and passes downwards over the coracoid process along the groove between the deltoid and the clavicular portion of the pectoralis major as far as the junction of the anterior fold of the axilla with the upper arm. The cephalic vein appears at the edge of the deltoid. The muscles are separated as far down as the upper edge of the tendon of the pectoralis major. On drawing the arm downwards the short head of the biceps appears from beneath the deltoid, and under the inner edge of the

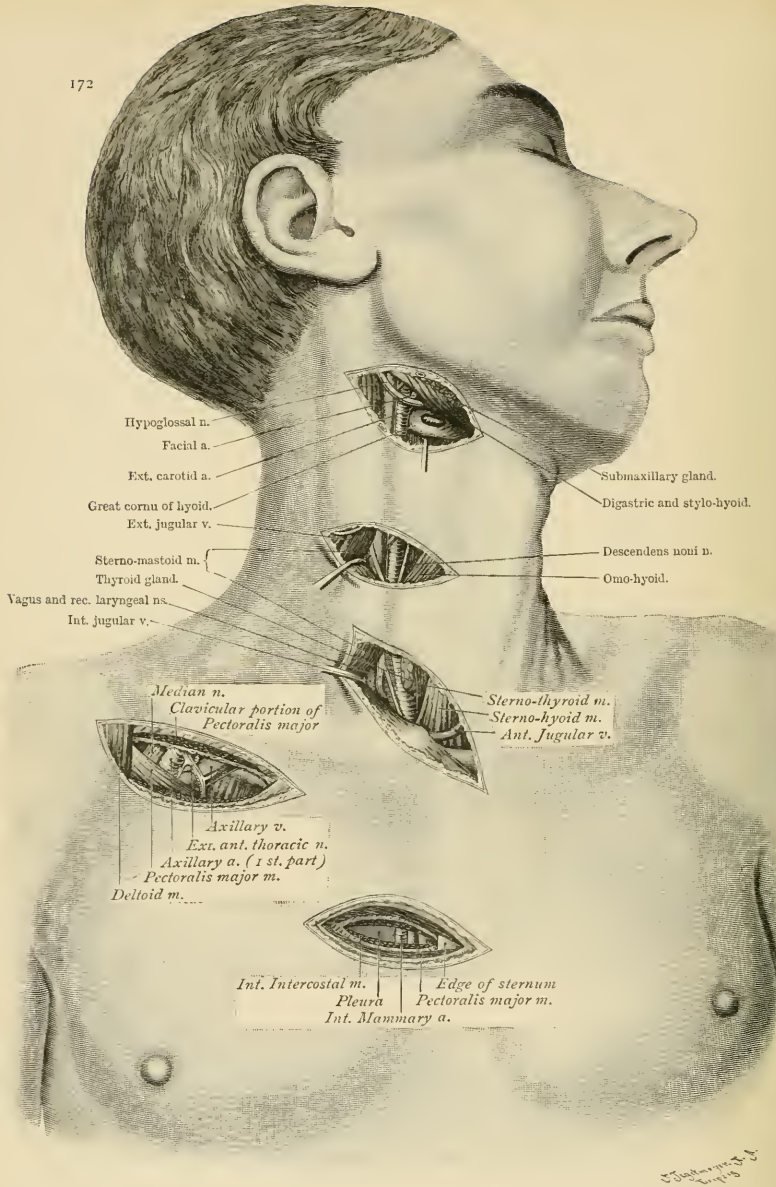

FIG. 76.—Ligature of the lingual artery above the greater cornu of the hyoid. Ligature of the common carotid at the level of the cricoid cartilage. Ligature of the innominate artery. Ligature of the first part of the axillary artery. Ligature of the internal mammary artery.

former is the coraco-brachialis muscle, pierced by the musculo-cutaneous nerve.

The lower border of the pectoralis minor is exposed from the coracoid process towards the thorax; between it and the coraco-brachialis lie the vessels and nerves, the large vein being internal. The axillary vein and the median nerve [inner head] are now drawn inwards, when the axillary artery will be seen lying beneath and external to them. External to the artery is a smaller collateral vein.

The operation is rendered easier by separating the pectoralis major muscle from the clavicle for a short distance.

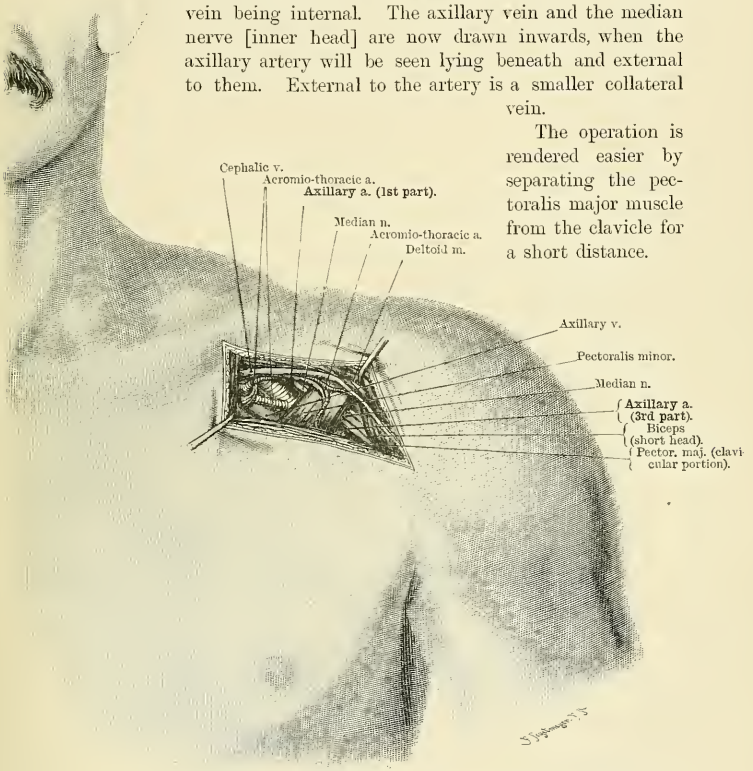

FIG. 77.—Ligature of the axillary artery, above or immediately below the pectoralis minor.

102. The Superior Thoracic Artery passes forwards from the main trunk below the subclavius muscle (Fig. 76). In this situation also the axillary artery is embraced by the *anterior thoracic nerves* going to supply the pectoral muscles.

103. The Acromio-Thoracic Artery arises from the axillary at the

upper border of the pectoralis minor, and can be ligatured by the above incision (Fig. 77).

104. The Long Thoracic Artery. With the arm abducted, an incision is made along the anterior fold of the axilla, extending as far as the lateral wall of the thorax. After dividing the fascia the artery is found descending in the line of the axilla immediately behind the edge of the pectoralis major; it lies on the wall of the thorax in contact with the serratus magnus muscle.

(b) Axilla

105. The 3rd part of the Axillary Artery (Fig. 78). The line of the vessel is from the middle of the clavicle to the middle of the anterior fold of the axilla. The artery is in contact with the outer wall of the triangular prismatic space between the thorax internally, the pectoralis major and minor anteriorly, and the scapula covered by the subscapularis muscle posteriorly. With the arm fully abducted, an incision is made through the skin and fascia along the line of the internal bicipital groove over the inner edge of the prominence of the coraco-brachialis. The muscular fibres of the coraco-brachialis are exposed, with the large nerves of the axilla—which may be felt through the skin upon the prominence of the head of the humerus—lying along its inner border. The dissection is now to be continued between the musculo-cutaneous and median nerves, otherwise a collateral vein running alongside the coraco-brachialis may easily be taken for the artery. The smaller external nerve is the *musculo-cutaneous;* the larger internal one is the *median,* which is single below, but higher up consists of two cords, the external of which unites above with the musculo-cutaneous. The artery lies in the fork between the two heads of the nerve. The *ulnar* and *internal cutaneous nerves* lie internal to the artery, the *musculo-spiral* and *circumflex* behind it. The main *vein* is quite internal to the artery, and a smaller collateral vein lies external to it.

106. Anterior Circumflex Artery (Fig. 79). Incision along the anterior border of the deltoid opposite the surgical neck of the humerus. The cephalic vein lies upon the fascia. It is important to define the groove between the deltoid and pectoralis major, and after dividing the fascia the muscles are separated from one another, the deltoid being drawn outwards and the pectoralis major inwards. The outer borders of the short head of the biceps and the coraco-brachialis muscles which descend under the pectoralis major are exposed and drawn inwards. The artery is seen between the two heads of the biceps, running transversely in some fat immediately below the head of the humerus and above the insertion of the pectoralis major.

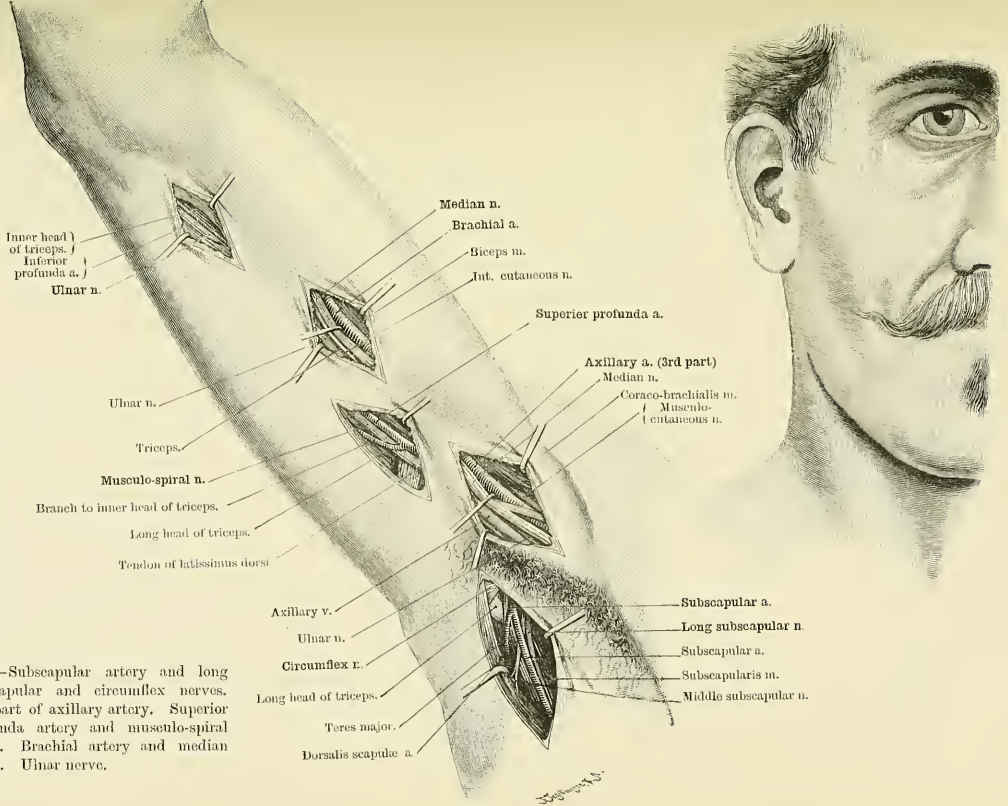

FIG. 78.—Subscapular artery and long subscapular and circumflex nerves. 3rd part of axillary artery. Superior profunda artery and musculo-spiral nerve. Brachial artery and median nerve. Ulnar nerve.

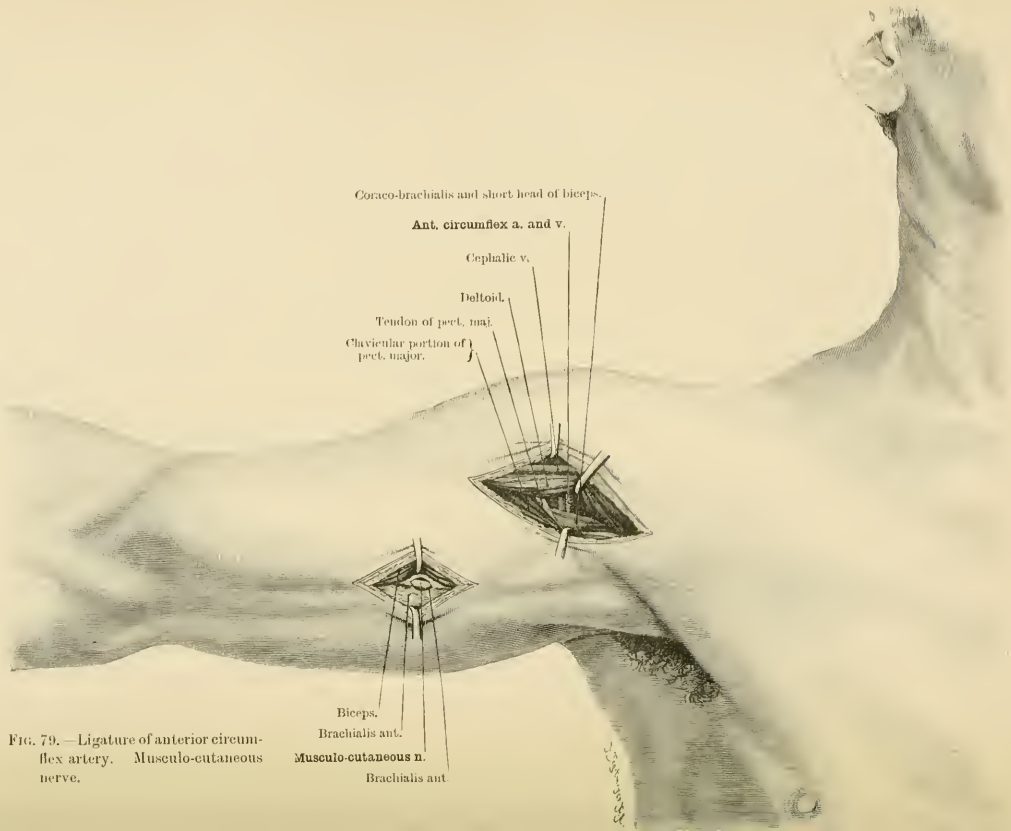

FIG. 79.—Ligature of anterior circumflex artery. Musculo-cutaneous nerve.

107. Posterior Circumflex Artery and Circumflex Nerve (Fig. 80). For the exposure of the circumflex nerve in the axilla, see *ligature of the subscapular artery.*

If, with the arm abducted, the posterior border of the deltoid muscle be pressed towards the surgical neck of the humerus, the angle which this muscle forms with the posterior scapular muscles may be distinctly felt. The skin and the fascia (which is adherent to the deltoid) are divided longitudinally over the above-mentioned situation. The posterior border of the deltoid having been exposed and drawn forwards, the lower edge of the teres minor and, in front of it, the tendon of the long head of the triceps, are brought into view. In the angle between the teres minor and the upper border of the long head of the triceps the posterior circumflex artery, along with the circumflex nerve which is above it, comes out from before backwards. The latter curves round the posterior surface of the humerus in order to enter the under surface of the deltoid after having given off a branch which runs downwards along its posterior border. Below the nerve the posterior circumflex artery curves forwards out of the interspace between the teres minor above and the teres major below, and divides into ascending and descending branches. The main trunk surrounds the neck of the humerus. Below the posterior circumflex, and separated from it only by the long head of the triceps, the *dorsalis scapulæ artery* will be seen winding round the axillary border of the scapula.

108. Subscapular Artery and Subscapular Nerves (Fig. 78). The limb being fully abducted, an incision beginning at the arm is carried along the anterior surface of the posterior axillary fold. Intercosto-humeral branches going to join the lesser internal cutaneous nerve may appear upon the fascia. After dividing the fascia the artery is found lying in loose cellular tissue at the upper edge of the insertions of the latissimus dorsi and teres major muscles, which form the posterior axillary fold. About an inch from its origin it gives off the dorsalis scapulæ artery, which passes backwards. At the upper angle of the incision the circumflex nerve may be seen upon the projection caused by the head of the humerus.

109. The continuation of the trunk towards the thorax is accompanied by the *long subscapular nerve* to the latissimus dorsi.

110. The Dorsalis Scapulæ Artery passes backwards through the triangular interval between the latissimus dorsi (with teres major), the subscapularis, and the long head of the triceps. Accompanying it is a branch of the middle subscapular nerve to the teres major. For its ligature from behind see paragraph 107.

(c) Upper Arm

The *brachial artery* can be felt in the internal bicipital sulcus along the entire length of the upper arm, from the head of the humerus in the axilla, to the middle of the bend of the elbow. The median nerve

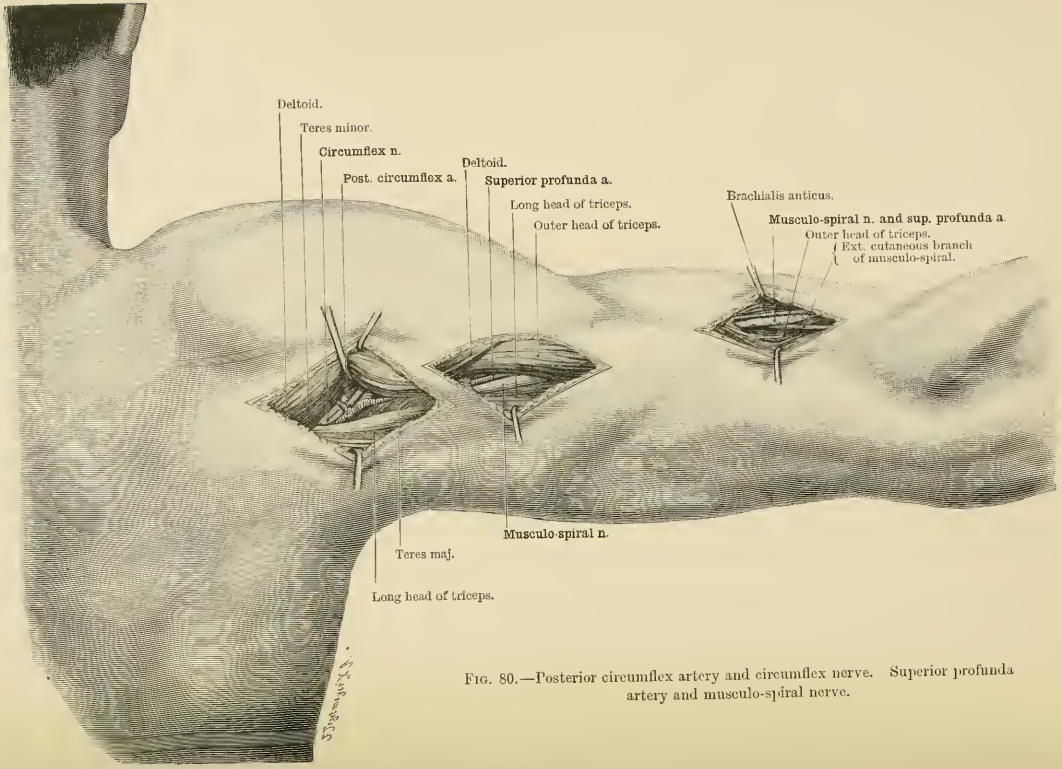

FIG. 80.—Posterior circumflex artery and circumflex nerve. Superior profunda artery and musculo-spiral nerve.

which crosses the artery at its middle from without inwards can be equally well felt. The artery may be compressed against the humerus in its entire length.

111. The Brachial Artery in its Middle Third (Fig. 78). An incision is made along the line of the median nerve, which is very distinctly felt in the internal bicipital sulcus when the arm is abducted. Upon the fascia is the slender *lesser internal cutaneous nerve.* The fascia having been divided, the inner border of the biceps is exposed and drawn outwards. The median nerve is then completely exposed, freed, and drawn inwards. Immediately under it is the brachial artery (with its two venæ comites) lying in front of the intermuscular septum. Internal to it is the internal cutaneous nerve. The ulnar nerve lies under the fascia covering the inner head of the triceps at the hinder part of the internal bicipital sulcus.

Below the middle of the upper arm the *basilic vein* and the *internal cutaneous nerve* will be seen at the place where they pierce the fascia. They may be exposed by the same incision as for ligature of the brachial artery.

112. Superior Profunda Artery. *Upon the inner aspect of the arm in its upper third*—at the lower border of the latissimus dorsi muscle (Fig. 78). An incision commencing at the level of the posterior axillary fold is carried downwards along the internal bicipital sulcus. The lesser internal cutaneous nerve is met with upon the fascia. The fascia is divided over the prominence of the long head of the triceps behind the white line of the internal intermuscular septum, and the dissection is continued towards the bone upon the anterior surface of the long head and above the origin of the inner head of the triceps. By following up the large branch to the inner head of the triceps, one comes upon the trunk of the superior profunda artery lying against the bone.

Behind the artery lies the musculo-spiral nerve, which descends from above over the tendon of the latissimus and passes towards the posterior surface of the humerus between the inner and the long heads of the triceps. One must be careful not to go too far backwards, otherwise one would pass behind the nerve and artery which are situated close to the bone in the internal bicipital groove. The musculo-spiral nerve is identified by its resting upon the latissimus.

Upon the posterior surface of the arm above the middle (Fig. 80). See exposure of the *musculo-spiral nerve,* page 181.

Upon the outer aspect of the upper arm in the lower third (Fig. 80). An incision is made at the outer border of the outer head of the triceps (the limits of which can easily be made out by grasping it from behind), extending vertically upwards from the external condyle of the humerus to a point midway between it and the insertion of the deltoid. The muscular fibres of the triceps are exposed by continuing the dissection

along the external intermuscular septum, and separating the brachialis anticus muscle from it as far as the bone. The artery passes obliquely from behind forwards, accompanied by the musculo-spiral nerve, which lies close to the bone.

The terminal branch of the superior profunda artery may be tied opposite the base of the external epicondyle in the interval between the brachialis anticus and the supinator longus; it lies behind the musculo-spiral nerve.

113. The Inferior Profunda Artery accompanies the ulnar nerve. In the *upper third* of the arm it lies along with the nerve posterior to the large vessels, and is to be ligatured by the same incision as for the brachial artery, with this difference, that the median nerve is drawn outwards, and one passes internal and posterior to the main vessels.

From the middle of the arm downwards the artery lies behind the internal intermuscular septum. The incision (Fig. 78) is the same as for exposure of the ulnar nerve, the fascia being divided behind the intermuscular septum. The artery lies beside the nerve upon the muscular fibres of the inner head of the triceps.

At its *lower end* the artery can be felt upon the posterior surface of the internal epicondyle, and is to be looked for accompanying the ulnar nerve behind the internal intermuscular septum.

114. Anastomotic Artery. The artery lies upon the base of the internal epicondyle above the origin of the pronator radii teres. It can be felt there. It is found after dividing the strong fascia upon which lie the anterior branch of the internal cutaneous nerve and the junction of the median basilic with the basilic vein.

115. The Median Nerve (Fig. 78) may be exposed by the same incisions as for ligature of the brachial artery, to which it is closely related throughout the upper arm, lying upon its outer aspect in the upper half, and crossing it at the middle to lie upon its inner aspect at the lower half.

116. Ulnar Nerve in the Lower Half of the Upper Arm (Fig. 78). Incision over the inner head of the triceps along a line ascending vertically from the internal epicondyle. The strong fascia is divided behind the white line corresponding to the internal intermuscular septum. This exposes the muscular substance of the inner head of the triceps, in the most superficial fibres of which lie the ulnar nerve and the inferior profunda artery.

117. Musculo-spiral Nerve. *In the upper third upon the inner aspect* (Fig. 78). The operation is the same as that for ligature of the superior profunda artery in the internal bicipital sulcus.

Above the middle of the posterior surface (Fig. 80). As a guide to the incision, a line is drawn along the posterior surface of the upper arm from a point a finger-breadth behind the posterior border of the deltoid and close to the long head of the triceps down to the tip of the olecranon.

The incision begins below the level of the posterior axillary fold, and passes downwards along this line in the interval between the long and outer heads of the triceps, which are separated from one another down to the bone. The nerve lies between the inner and outer heads of the triceps after having passed under the long head at the lower border of the latissimus dorsi. Parallel to and in front of the nerve lies the superior profunda artery, which is also in contact with the inner surface of the humerus.

Below the middle of the arm at its outer surface (Fig. 80). The incision ascends vertically from the external epicondyle along the outer border of the triceps towards the insertion of the deltoid. Expose the tendinous outer head of the triceps, and pass in at its border towards the outer surface of the humerus by separating the fibres of the brachialis anticus muscle, which here project laterally for some distance beyond the biceps. The nerve lies upon the bone, accompanied by the superior profunda artery, which runs along its outer side; behind it is the *external cutaneous branch of the musculo-spiral*, which supplies the outer aspect of the posterior surface of the forearm. At the junction of the middle and lower thirds of the humerus the nerve passes through the external intermuscular septum to its anterior surface.

118. Musculo-cutaneous Nerve. *Above the middle of the upper arm* (Fig. 79). The incision descends along the internal bicipital sulcus from the lower part of the prominence of the coraco-brachialis. The muscular fibres of the biceps are exposed, and the muscle drawn outwards. The nerve lies, covered by the biceps, upon the outer border of the coraco-brachialis muscle, through which it penetrates in order to reach the anterior surface of the brachialis muscle.

Higher up, the nerve may be found by making an incision over the prominence of the coraco-brachialis, and passing between this muscle and the short head of the biceps.

Below the middle of the upper arm. An incision is made along the outer edge of the biceps a finger-breadth in front of the external bicipital sulcus; it is carried through the fascia down to the muscular fibres. The cephalic vein is avoided. After raising the biceps from the brachialis anticus, the finger is introduced between them and the nerve found towards the middle of the brachialis anticus lying under the thin fascia covering it. Care must be taken that the outer border of the brachialis anticus is not exposed instead of the biceps.

(d) Region of the Bend of the Elbow

119. Brachial Artery at the Bend of the Elbow (Fig. 81). Incision in the direction of the axis of the forearm beginning internal to the biceps tendon a little to the ulnar side of a point midway between

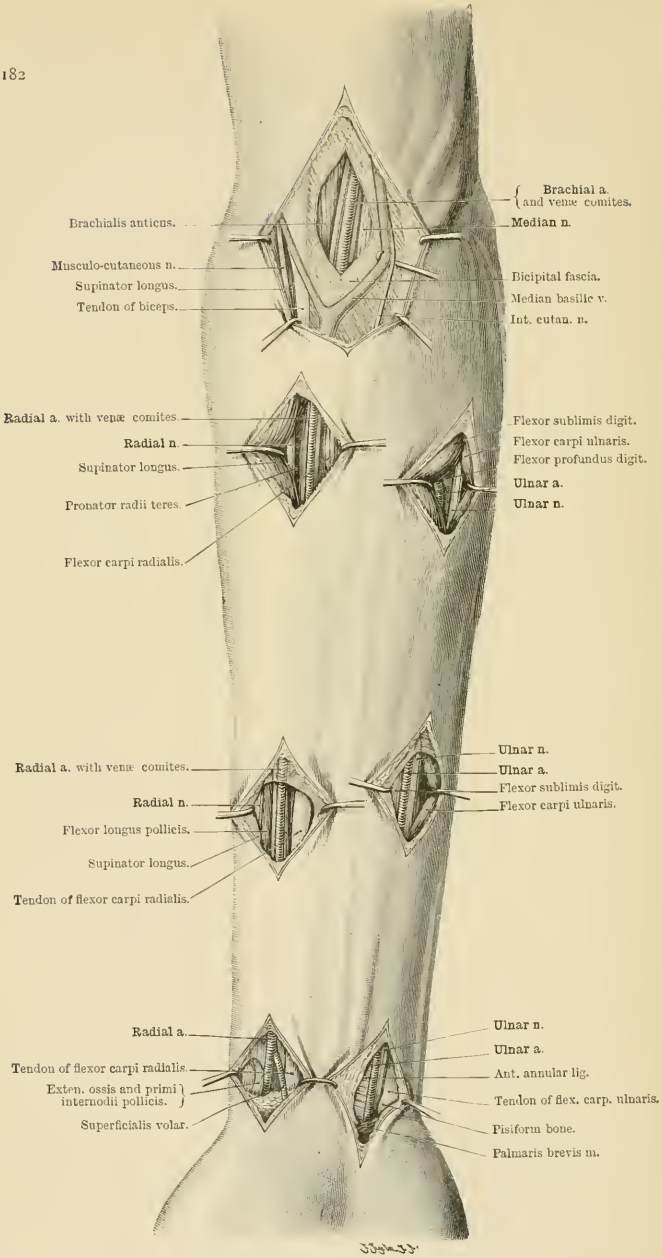

FIG. 81.—Brachial, radial, and ulnar arteries.

the condyles of the humerus. The oblique median basilic vein and the main branches of the internal cutaneous nerve are seen lying upon the fascia. Under the superficial fascia is the aponeurotic bicipital fascia, the fibres of which run in a characteristic manner downwards and inwards. Immediately under it, or covered by a thin layer of fat, lies the brachial artery, with its two venæ comites. Externally is the biceps tendon. The division of the brachial artery into radial and ulnar takes place a finger-breadth below the level of the joint.

120. The Median Nerve (Fig. 81) lies half a centimetre internal to the brachial artery at the outer edge of the pronator teres muscle. The vessels and nerve are supported posteriorly by the brachialis anticus

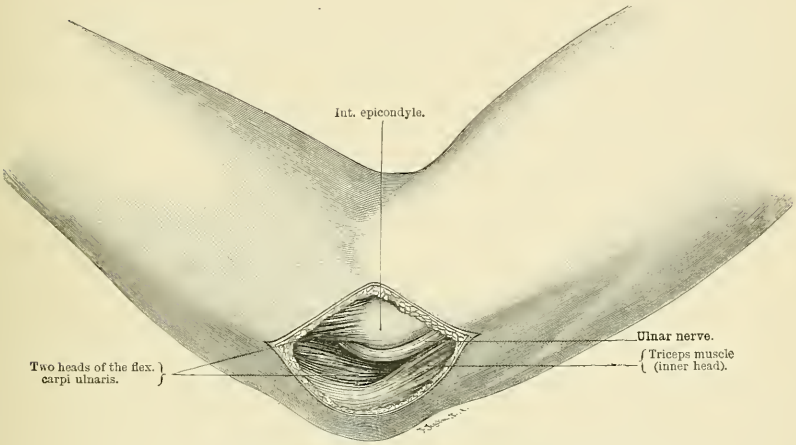

FIG. 82.—Ulnar nerve at the internal epicondyle.

muscle. In this operation it is to be borne in mind that the artery and nerve descend from the internal bicipital sulcus, and therefore one must not pass to the outer side of the biceps tendon. The *musculo-cutaneous nerve* pierces the fascia external to the biceps tendon in the groove between it and the supinator longus.

121. The Ulnar Nerve (Fig. 82). Incision through skin and fascia upon the posterior surface of the base of the internal epicondyle. The nerve lies close to the bone along the inner edge of the triceps, disappears below between the two heads of origin of the flexor carpi ulnaris which spring from the epicondyle and the olecranon respectively, and rests upon the flexor profundus digitorum.

The terminal branch of the inferior profunda artery lies alongside the nerve.

122. Musculo-spiral Nerve at its Bifurcation. At the bend of the elbow the musculo-spiral nerve, together with its bifurcation into radial and posterior interosseous nerves, lies in the interval between the supinator longus and brachialis anticus muscles.

An incision is made at the bend of the elbow in a line prolonged from the external bicipital sulcus along the anterior edge of the supinator longus muscle. The median cephalic vein is drawn aside, and after dividing the fascia, the musculo-cutaneous nerve appears at the lower part of the incision beside the biceps tendon (Fig. 81). The latter nerve pierces the fascia to supply the skin upon the radial side of the anterior aspect of the forearm. By passing towards the bone at the outer border of the brachialis anticus muscle the radial and posterior interosseous nerves are found, the one in front of the other, and beneath them the terminal branch of the superior profunda artery.

(e) Forearm—Anterior Surface

123. The Radial Artery (Fig. 81). This vessel, the direct continuation of the brachial artery, is easily felt in two-thirds of its length. It is nowhere covered by muscles, except in the upper third, where it is slightly overlapped by the supinator longus muscle. The direction of the artery is indicated by a line from the middle of the bend of the elbow, down the front of the forearm, and along the "pulse" to the projection of the os trapezium.

In the upper third the artery lies more deeply upon the supinator brevis and the pronator teres, between the projecting supinator longus and the flexor carpi radialis muscles. An incision is made along the interval which may be distinctly felt between the two latter muscles. The median vein and a large branch of the musculo-cutaneous nerve appear upon the fascia. The fascia is divided, and the supinator longus muscle is drawn well outwards. The artery is found lying deeply upon the insertion of the pronator radii teres. To the radial side of the artery, and at some distance from it, is the radial nerve covered by the supinator longus.

In the middle third. Incision in the interval (in which the radius may be felt) between the flexor carpi radialis and supinator longus muscles. In this interval the artery lies upon the radial origins of the flexor longus pollicis and flexor sublimis digitorum muscles. The *radial nerve* lies at a little distance to its radial side, more under cover of the supinator longus, beneath which it passes backwards.

Above the wrist. The hand being dorsiflexed, an incision is made

between the prominent tendon of the flexor carpi radialis and the edge of the radius. The skin and fascia are divided. At the lower border of the pronator quadratus the artery passes deeply towards the radial aspect of the wrist-joint and sends merely the small superficial volar branch downwards to the palm over the projection of the os trapezium. The tendons of the extensor ossis metacarpi and extensor primi internodii pollicis lie enveloped in their sheaths external to the artery at the edge of the radius. The radial nerve is no longer to be seen, as it passes backwards under the tendon of the supinator longus at the lower third of the forearm.

124. The Ulnar Artery (Fig. 81) can be felt in the lower third, being for the most part uncovered by muscles. After arising at an angle from the brachial artery, it passes between the flexor sublimis and flexor profundus digitorum muscles. Incisions for ligaturing the artery are made along a line extending from the internal condyle of the humerus to the projection of the pisiform bone. This line does not correspond to the course of the artery, which in its upper part lies much more towards the middle line. To ligature it at its origin, the directions already given for ligature of the brachial at the bend of the elbow suffice, except that the incision is prolonged somewhat more downwards.

In the upper half. With the arm held abducted, an incision is made in a line descending vertically from the posterior edge of the internal epicondyle of the humerus. The incision must not be begun higher than four finger-breadths below the epicondyle (*i.e.* at the junction of the upper and middle thirds of the forearm), and must not fall in front of the above line; it strikes the radial edge of the flexor carpi ulnaris, which is indicated by a distinct intermuscular septum. Occasionally the ulnar nerve can be felt through the skin. After dividing the skin, the anterior ulnar vein along with a branch of the internal cutaneous nerve comes into view. In the fascia is the intermuscular septum between the flexor carpi ulnaris and the subjacent flexor sublimis; it is indicated by a distinct white line. After dividing the fascia along this line, the finger is passed deeply at the outer border of the flexor carpi ulnaris and somewhat outwards upon the anterior surface of the flexor profundus digitorum, the flexor sublimis being drawn aside. If the right intermuscular space has been struck, the ulnar nerve will first be met with. By passing external and somewhat anterior to the nerve, the artery will be found lying $\frac{1}{2}$ to $1\frac{1}{2}$ cm. (according to the height) to its outer side. Higher up, the artery is still further external to the nerve.

In the lower half. An incision is made down to the flexor sublimis in the interval between the flexor carpi ulnaris and the palmaris longus. This interval is definitely marked out by projecting a line vertically upwards from the radial border of the pisiform bone. After dividing the skin and fascia the dissection is carried down upon the flexor

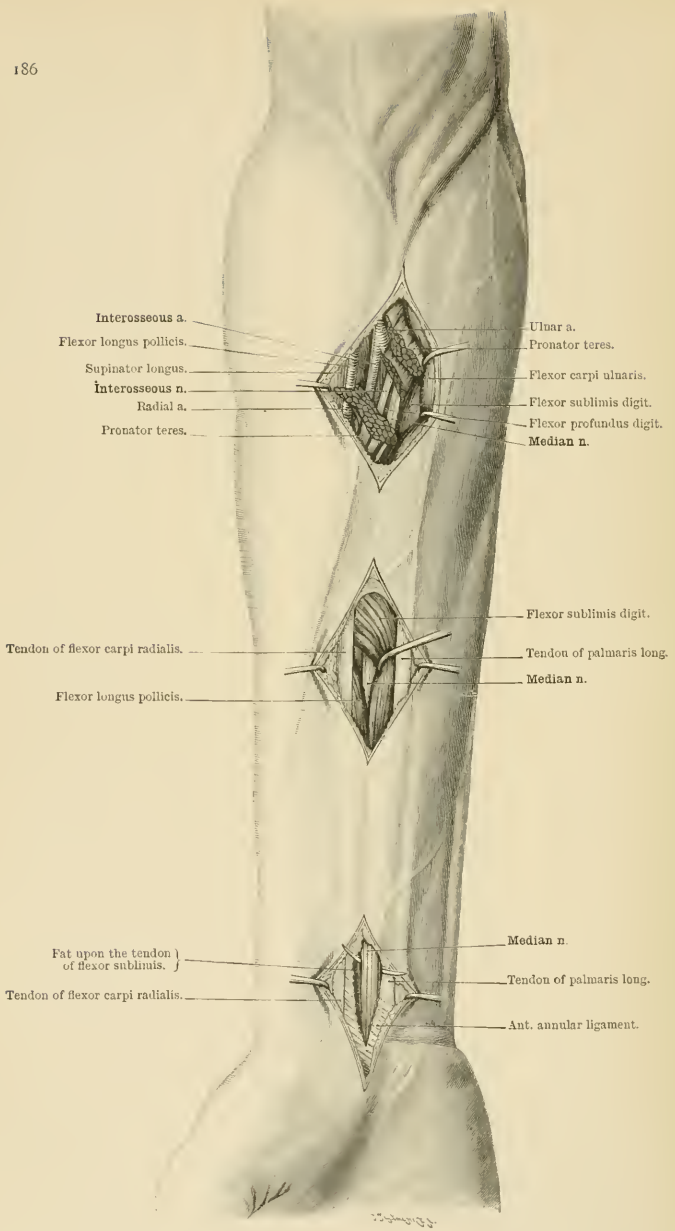

FIG. 83.—Median nerve, anterior interosseous nerve, and interosseous artery. Median nerve at middle third ; at lower third of forearm.

sublimis and *not under* the flexor carpi ulnaris. The artery lies between two venæ comites. The ulnar nerve is close to its ulnar side.

125. Interosseous Artery (Figs. 81 and 83). This branch of the ulnar artery may be exposed by the same incision as that for the ulnar artery in its upper third, by passing down upon the flexor profundus digitorum until the median nerve with its branches is met with. The interosseous artery passes under the nerve towards the interosseous membrane between the flexor profundus digitorum and the flexor longus pollicis. The interosseous branch of the median nerve lies upon the artery. The interosseous artery may also be exposed by the same incision as that for the median nerve in the upper third (Fig. 83). The ulnar artery here lies deeply towards the supinator brevis and above the tendinous arch of the flexor sublimis digitorum, beneath which, close to the radius, the interosseous artery is given off.

126. Median Nerve (Fig. 83). *In the upper third.* Incision in the interval between the supinator longus and flexors, as in ligature of the radial artery. The pronator radii teres, which here covers the nerve, is divided internal to the above vessel. In the upper third of the incision the tendinous arch of the flexor sublimis digitorum is seen with the nerve descending behind it; it must be divided when the nerve is to be exposed farther down. At first the ulnar artery lies to the radial side of the nerve, and then passes almost at once under it as it arches downwards and inwards towards the ulnar side of the forearm. The interosseous artery passes directly downwards to lie deeply upon the interosseous membrane.

Below the middle. Incision in the middle of the forearm between the flexor carpi radialis and the palmaris longus. The muscular fibres of the flexor sublimis appear in the interval between these tendons, and its radial border having been exposed, the muscle is drawn inwards. The large nerve lies upon the flexor profundus digitorum muscle, accompanied by the median artery.

Above the wrist-joint. Incision through the skin and fascia along the radial side of the palmaris longus tendon.

127. Palmar Cutaneous Nerve (Fig. 83). The palmar cutaneous branch of the median nerve may be exposed by the same incision as that for the median itself above the wrist-joint; there it pierces the fascia and descends to the palm.

128. The Anterior Interosseous Branch of the Median Nerve (Fig. 83) is seen passing outwards from the median in exposing the latter in its upper third. The anterior interosseous nerve (with the artery) is exposed in exactly the same manner as the median nerve in the middle third of the forearm. After exposing the median, the anterior interosseous branch may be seen upon its outer side passing deeply between the flexor longus pollicis and the flexor profundus digitorum to reach the interosseous membrane.

Deep Incisions upon the Anterior Aspect of the Forearm. Deep abscesses necessitating free and deep incisions are not unfrequently found upon the interosseous membrane as the result of extension upwards of an inflammation connected with the tendon sheaths of the hand.

By keeping in mind the position of the radial artery and nerve on the one side, the median and anterior interosseous nerves (with their companion arteries) on the other, one may incise without danger down to the interosseous membrane and radius between the supinator longus and the flexors, without producing any serious nerve injury, as the incision lies in the interval between the two nerves. When necessary, after dividing the pronator teres and flexor sublimis digitorum muscles in the upper half of the forearm it is best at first to expose the median nerve in its whole extent, and to pass deeply to its outer side as if searching for the anterior interosseous nerve. In passing in this way down to the radius and interosseous membrane the division of the nerve to the flexor longus pollicis is the worst injury that can happen.

(f) Forearm—Posterior Surface

129. Posterior Interosseous Nerve (Fig. 84). An incision is carried vertically downwards from the head of the radius, along the radial aspect of the posterior surface of the forearm, in the interval between the radial extensors and the tendinous extensor communis digitorum. The fascia is divided between the glistening tendinous origin of the extensor communis digitorum and the muscular fibres of the radial extensors, the latter being drawn forwards with blunt hooks. The supinator brevis muscle now appears, the fibres of which pass in a characteristic manner obliquely downwards and forwards. The nerve issues from the muscle about 5 cm. (2 in.) below the head of the radius, and at once breaks up into several branches. To expose the trunk of the nerve for a greater extent, the supinator brevis muscle is divided in an upward direction. The forearm is flexed and held in a position midway between pronation and supination. Longer branches of the nerve pass between the extensor communis and radial extensors to the extensors of the thumb and index finger, which lie upon the posterior surface of the radius. In the lower third of the arm the terminal branch passes on to the interosseous membrane and ends upon the ligaments of the wrist-joint.

The *posterior interosseous artery* passes backwards above the upper border of the interosseous membrane, appears upon the posterior aspect of the forearm at the lower border of the supinator brevis muscle, and descends between the superficial and deep layers of extensor muscles.

Incisions upon the Posterior Surface of the Forearm. As the posterior muscles are supplied by the posterior interosseous nerve, incisions may be made along the entire length of the ulna, and also along the radial edge of the extensor carpi ulnaris, because the nerves supplying this muscle enter it high up. Towards the radial side incisions may be made along a line from the head of the radius to its styloid process, that is to say, from where the posterior interosseous nerve pierces the supinator brevis downwards between the radial and common extensor muscles. After drawing the radial extensors outwards and the common extensor inwards, the muscles of the thumb are exposed, and the posterior interosseous nerve accompanied by the small artery of the same name is found in the interval between the extensor ossis metacarpi and the extensor secundi internodii pollicis. In the *lower half* of the forearm, where the radial extensors pass beneath the obliquely-directed

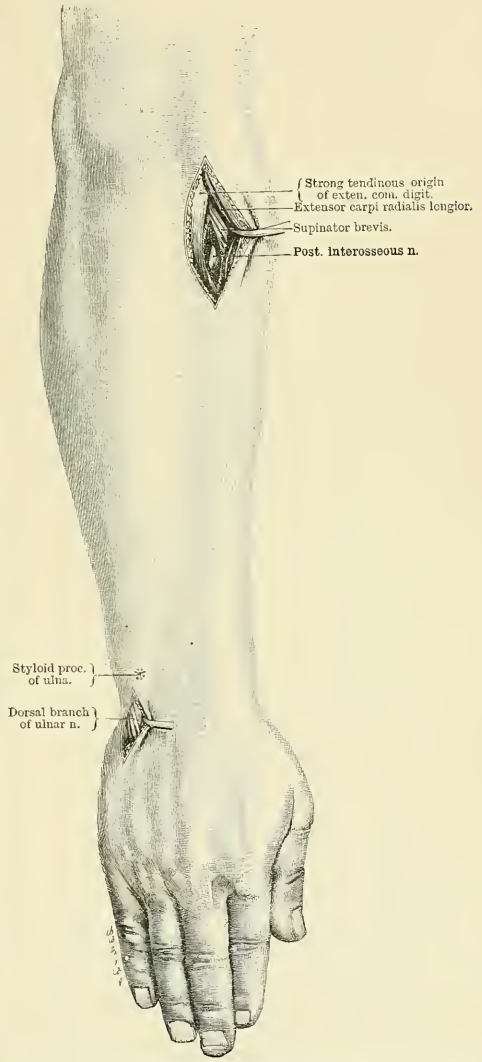

FIG. 84.—Posterior interosseous nerve below the head of the radius. Dorsal branch of the ulnar nerve.

extensors of the thumb, the radius may be cut down upon between the latter and the tendon of the supinator longus. In the *lower third*, towards the ulnar side of the extensors of the thumb, incisions may be made between any of the tendons on the posterior surface, as no large vessels or nerves are encountered.

(g) Palmar Aspect of the Wrist Joint

130. Ulnar Artery at the Pisiform Bone (Fig. 81). Its pulsation can here be distinctly felt. As the ulnar artery becomes the superficial palmar arch, it must be ligatured in bleeding from the arch which cannot be otherwise arrested. An incision is made through the skin and fascia half a centimetre to the radial side of the projection of the pisiform bone. After dividing the fascia close to the pisiform bone, a cushion of fat protrudes and should be cut away. The artery lies under a considerable amount of fat upon the annular ligament, the large ulnar nerve being nearer the bone. The tendon of the flexor carpi ulnaris is seen descending to its insertion into the pisiform, and the muscles of the ball of the little finger are seen passing downwards with the transverse fibres of the palmaris brevis muscle lying upon them.

131. Median Nerve. An incision is carried through the skin and the strong anterior annular ligament at the junction of the thenar and hypo-thenar eminences. The large nerve lies upon the common flexor sheath and divides into two divisions, the outer supplying the thenar muscles (with the exception of the adductor), both sides of the thumb, and the outer side of the index finger; the inner supplying the two outer lumbricals, the ulnar side of the index, both sides of the middle and the radial side of the ring finger.

(h) Dorsal Aspect of the Hand

The frontier between the areas of distribution of the radial and the dorsal branch of the ulnar nerve is indicated by a line drawn along the centre of the middle finger upwards to the wrist-joint. The dorsal carpal arch and its dorsal interosseous branches are relatively small vessels. It is the tendons, therefore, which are chiefly to be borne in mind in making incisions. The extensor tendons at the wrist-joint possess for the most part separate synovial sheaths which extend downwards to the middle of the metacarpal bones.

132. Radial Artery at the Back of the Hand (Fig. 85). This vessel goes to form the main part of the deep palmar arch.

Incision from the upper end of the first interosseous space along the

ulnar side of the tendon of the extensor secundi internodii pollicis. The vessel can be felt here. The branches of the radial nerve and vein which lie upon the fascia are to be avoided. The dissection is continued between the bases of the 1st and 2nd metacarpal bones, upon which the artery lies just before it passes towards the palm, under the tendinous arch joining the two heads of origin of the 1st dorsal interosseous muscle (abductor indicis). The broad tendon of the extensor carpi radialis longior, which is inserted into the 2nd metacarpal bone, appears upon the ulnar side. The artery has previously given off the common digital branch for the forefinger and thumb, which may readily be mistaken for the main trunk.

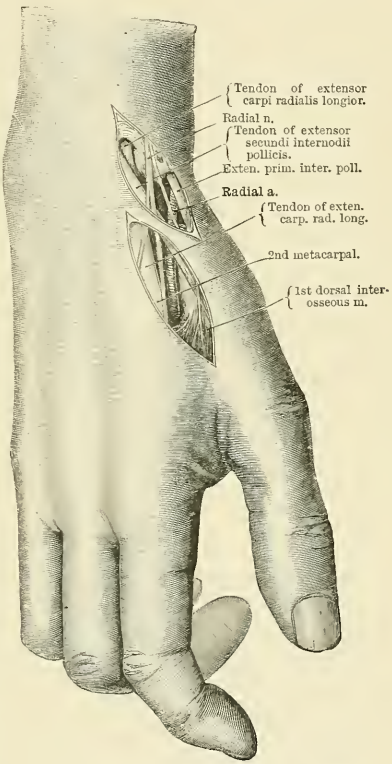

FIG. 85.—Radial artery at the back of the wrist.

133. Radial Artery upon Trapezium (Fig. 85). Longitudinal incision from the lower end of the radius to the base of the 1st metacarpal bone between the prominent tendons of the extensor primi and extensor secundi internodii pollicis. The vessel can here be felt through the skin. In the subcutaneous tissue parallel to the tendons are the radial vein and nerve, which are to be avoided; the latter can be felt upon the outer side of the radius. The artery courses obliquely beneath the above-mentioned structures upon the scaphoid and external lateral ligament.

134. Dorsal Branch of the Ulnar Nerve (Fig. 84). The nerve may be distinctly felt upon the ulnar side of the unciform bone. It is exposed by a longitudinal incision extending from the lower end of the ulna downwards along the ulnar edge of the carpus. It lies either upon or in the fascia, after having passed backwards from the forearm under the flexor carpi ulnaris.

135. Radial Nerve (Fig. 85). This nerve may be exposed by the same incision as that for ligature of the radial artery upon the trapezium. It can be felt through the skin upon the outer aspect of the lower end of the radius, after having passed backwards beneath the tendon of the supinator longus at the lower third of the forearm.

(i) Palm of the Hand

In the palm the vessels and nerves run in the intervals between the metacarpal bones, while the tendons are placed over them; all lie under the strong palmar fascia which gives off processes to join the tendon sheaths upon the fingers. Between the processes the fascia ends in concave arches which, by means of the septa passing from them to be attached to the deep transverse ligament, serve to separate the flexor tendons and lumbrical muscles from the digital vessels and nerves.

Under the palmar fascia is the bundle of flexor tendons with the lumbrical muscles, surrounded by a synovial sheath which reaches from the ends of the bones of the forearm downwards to the middle of the metacarpus. The flexor longus pollicis possesses a sheath of its own. Under the tendons is a thin deep fascia which covers the interosseous muscles and the bones.

As landmarks for incisions in the region of the wrist, the following are to be mentioned; the *pisiform bone*, with the insertion of the flexor carpi ulnaris, and the ulnar vessels and nerve, which may be felt in contact with its radial aspect; upon the ulnar side of the wrist-joint below the pisiform bone the projecting body of the *unciform bone*, upon which the dorsal branch of the ulnar nerve can be felt; a thumb's breadth below and somewhat to the radial side of the pisiform bone, at the radial edge of the hypo-thenar eminence is the *hook of the unciform*, below which the deep branch of the ulnar artery and nerve curves round; the superficial sensory division of the ulnar nerve can be felt through the skin and rolled from side to side over the hook of the unciform; lastly, immediately above the ball of the thumb is the projection of the *os trapezium*, over which the superficial volar branch of the radial artery, which may be felt through the skin, descends to complete the superficial palmar arch. Two fascial envelopes surround the wrist, one a part of the general fascial envelope thickened by transverse fibres, the other situated deeply around the ligaments of the wrist-joint; besides these, upon the palmar aspect is the strong anterior annular ligament which bridges over the tendons occupying the hollow of the carpal bones, and gives origin to some of the muscles of the thumb.

136. Superficial Palmar Arch (Fig. 86). Longitudinal incision from the junction of the thenar eminences towards the ring finger, the

middle of the incision being opposite a line drawn across the palm at the level of the web of the abducted thumb. The superficial arch may be felt pulsating at the point where these two lines intersect. After dividing the skin, the superficial fascia (which is often of considerable thickness), and the strong aponeurotic palmar fascia, the arch is at once exposed embedded in fat beneath the smooth under surface of the latter. The arch is the continuation of the ulnar artery, and at this point it curves outwards towards the thumb. Passing downwards from the arch are the common digital arteries. The arch lies upon the digital branches of the median and ulnar nerves, the latter being exposed. If the artery cannot be found here, the ulnar artery may be ligatured at the pisiform bone.

The *ulnar nerve* may be exposed by the same incision. Its superficial division descends over the hook of the unciform bone, which can be felt through the skin. The deep division passes between the abductor and flexor brevis minimi digiti at the ulnar side of the hook of the unciform, and supplies the flexor brevis and opponens minimi digiti, the two inner lumbricals, and all the interossei together with the adductor pollicis.

137. Deep Palmar Arch (Fig. 86). In contrast to the superficial arch, the deep arch is formed mainly by the radial artery. It gives off large branches to the radial side of the hand, whilst its interosseous branches are small. It does not reach so far downwards as the superficial arch. To expose it, an incision is made from the junction of the two thenar eminences along the opponens crease towards the index finger, the middle of the incision corresponding to the middle of the ball of the thumb. After dividing the skin and palmar fascia the superficial arch is ligatured. The superficial muscular layer of the thumb (opponens pollicis) is exposed, and together with the anterior annular ligament is slightly incised at the upper end of the wound. At a deeper plane is the slender 1st lumbrical muscle with the white flexor tendon of the index finger to its ulnar side. The dissection is continued along the radial side of the lumbrical between it and the thumb muscles. This exposes the

138. Outer Division of the Median Nerve, which divides into branches for the forefinger and thumb. These nerves, together with the superficial muscles of the thumb (flexor brevis and abductor), are drawn to the radial side. The transverse fibres of the broad adductor pollicis now appear at the bottom of the wound. After dividing this muscle, the deep arch will be exposed immediately under it, running transversely upon the deep fascia above the origins of the interossei muscles, a little nearer the wrist joint than the superficial arch. The best means for defining exactly the seat of ligature is to feel for the proximal end of the first interosseous space on the dorsum of the hand.

139. The Common Digital Arteries are exposed by dividing the

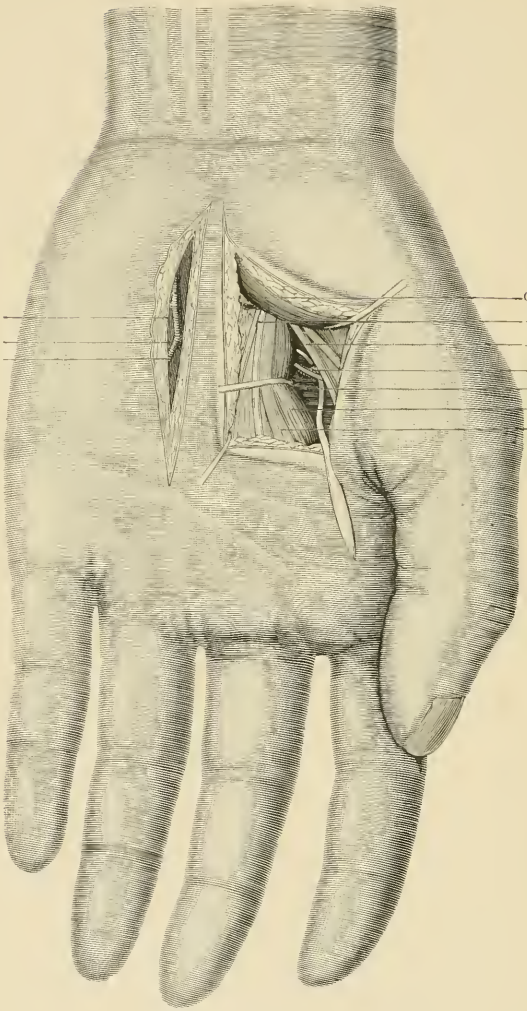

FIG. 86.—Superficial palmar arch. Deep palmar arch and branches of the median nerve.

skin and fascia from the superficial arch downwards towards the web of the fingers. In addition to the vessels, which gradually become more superficial as they descend, are the large digital branches of the median and ulnar nerves.

The Fingers

140. The chief mass of the subcutaneous soft parts of the fingers is made up of the tendons, which are absent upon the smaller lateral surfaces. The *flexor tendons* lie upon the periosteum. Opposite the middle phalanx the deep flexor tendons pass through those of the superficial flexors. The latter are crescentic in transverse section, with the convexity towards the bone, the former being cylindrical.

The two divisions of the flexor sublimis tendon, after embracing the tendon of the flexor profundus, are inserted into the lateral surfaces of the middle phalanx. The flexor profundus tendon, after passing through the slit in the flexor sublimis tendon, is inserted into the base of the terminal phalanx. As far as the bases of the terminal phalanges the tendons are enclosed in a fibrous tube continuous with the palmar fascia, and from the heads of the metacarpal bones downwards they are surrounded in addition by closed synovial sheaths, which in the case of the thumb and little finger approach and often communicate with the common flexor sheath in the palm. Vincula tendinum pass from the bones and the capsules of the joints to the under surface of the tendons.

The *extensor tendons* of the fingers are attached by some of their fibres to the bases of the first phalanges, upon which they divide into three divisions. The tendons of the lumbrical muscles and interossei (flexors of the first and extensors of the second and third phalanges) pass under the lateral divisions to join the middle portion and to be inserted along with it into the base of the middle phalanx. The lateral portions, after extending laterally over the first interphalangeal joints, unite again upon the dorsum of the second phalanx and are inserted into the base of the terminal phalanx. All the extensor tendons are flat and fascia-like.

The extensor primi internodii pollicis is inserted into the base of the first phalanx of the thumb; the extensor secundi, placed somewhat dorso-ulnawards, is attached by all three divisions to the base of the terminal phalanx.

As the *terminal phalanges* have tendinous insertions only at their bases, incisions may be made anywhere according to the indications; that is to say, they may be placed either mesially or laterally.

The *digital arteries and nerves* give off branches which pass towards the dorsal aspect of the second and third phalanges. Lateral incisions over the middle phalanges are to be made nearer the dorsum, as the

digital vessels and nerves come more into relation with the flexor tendons.

The palmar and dorsal digital vessels and nerves are of considerable size opposite the first phalanges, and here again the palmar vessels lie more towards the flexor tendons (the nerves being anterior to the vessels), so that incisions made be made laterally. Towards the base of the first phalanges, however, after dividing the skin, the deeper incisions are to be curved towards the palmar aspect of the finger in order to avoid the broad tendinous insertions of the lumbrical and interosseous muscles. When a choice is possible, it is better to make an incision upon the ulnar rather than the radial aspect, because the lumbrical muscles (flexors of the first phalanges) wind towards the radial aspect of the finger.

S. THE LOWER EXTREMITY

Region of the Buttock

Branches of the Internal Iliac Artery

141. Gluteal Artery (Fig. 87). The place where the artery is ligatured may be made out through the skin by feeling for the upper edge of the great sacro-sciatic foramen, at the level of the upper end of the gluteal fissure and of the upper edge of the gluteus maximus muscle.

The incision corresponds to the upper two-thirds of a line extending from the posterior superior iliac spine to the upper border of the great trochanter. The skin, fascia, and thick gluteus maximus—the fibres of which run parallel to the incision—are divided. After dividing the fascia over the lower border of the gluteus medius, the muscle itself is exposed and drawn upwards. On passing the finger under it the upper margin of the great sacro-sciatic foramen is felt. Here, above the upper border of the pyriformis, the large gluteal artery passes directly backwards out of the pelvis and at once gives off large branches, the largest passing outwards. The *superior gluteal nerve* passes out of the pelvis along with the artery, and runs outwards between the gluteus medius and minimus, to end in the tensor fasciæ femoris muscle.

142. Sciatic Artery. Incision corresponding to the middle two-thirds of a line extending from the posterior inferior iliac spine to the base of the great trochanter. The incision is below and parallel to that for ligature of the gluteal artery. The skin, the thick subcutaneous fat, the fascia, and the fibres of the thick gluteus maximus are divided. The lower border of the pyriformis muscle is visible under the gluteus maximus, and is clearly exposed with the finger. The artery, accompanied by the small sciatic nerve, appears from under the proximal end of the

pyriformis. The nerve, after giving off large branches to the gluteus maximus, is continued vertically downwards under the fascia of the back of the thigh. The spine of the ischium and the lesser sacro-sciatic ligament which is attached to it serve as a guide to the place of exit of the artery from the pelvis.

143. The Small Sciatic Nerve accompanies the continuation of the sciatic artery under the deep fascia along the middle of the posterior aspect of the thigh.

144. The Great Sciatic Nerve lies directly upon the bone, deeper and external to the small sciatic. It forms a very large and broad trunk, which may readily be felt lying upon the base of the spine of the ischium and descending upon the obturator internus muscle.

145. Internal Pudic Artery (Fig. 87). Incision the same as for ligature of the sciatic artery.

The artery lies upon the posterior surface of the ischial spine, below and external to the sciatic artery, and accompanied by the *internal pudic nerve*. It is recognised by its re-entering the pelvis below the spine.

Iliac Region

146. The Common Iliac Artery (and Abdominal Aorta) (Figs. 88 and 89). The aorta divides into the two common iliac arteries at the umbilicus (at the level of a horizontal line joining the anterior superior iliac spines).

The common and external iliac arteries descend along the inner border of the psoas muscle to a point midway between the anterior superior iliac spine and the symphysis pubis. The upper third of this line corresponds to the common iliac, the lower two-thirds to the external iliac.

Incision from the 11th rib, descending at first vertically downwards to a point two finger-breadths internal to the anterior superior iliac spine, and then obliquely downwards and inwards to a point two finger-breadths above the middle of POUPART'S ligament. The skin, the superficial fascia, and the strong muscular layers of the abdominal wall, namely, the external oblique, the internal oblique, and the thinner tranversalis muscle, each with its fibres running in a characteristic direction, are divided. The main branches of the lumbar arteries and nerves lie between the two latter muscles. Next, the well-developed fascia transversalis and the extra-peritoneal fat are divided. The peritoneum is separated from the iliac fascia (which covers the iliacus muscle with glistening transverse fibres), at first downwards, and then backwards as far as the inner edge of the psoas muscle, and from here upwards as far as the sacral promontory. The *external cutaneous nerve*

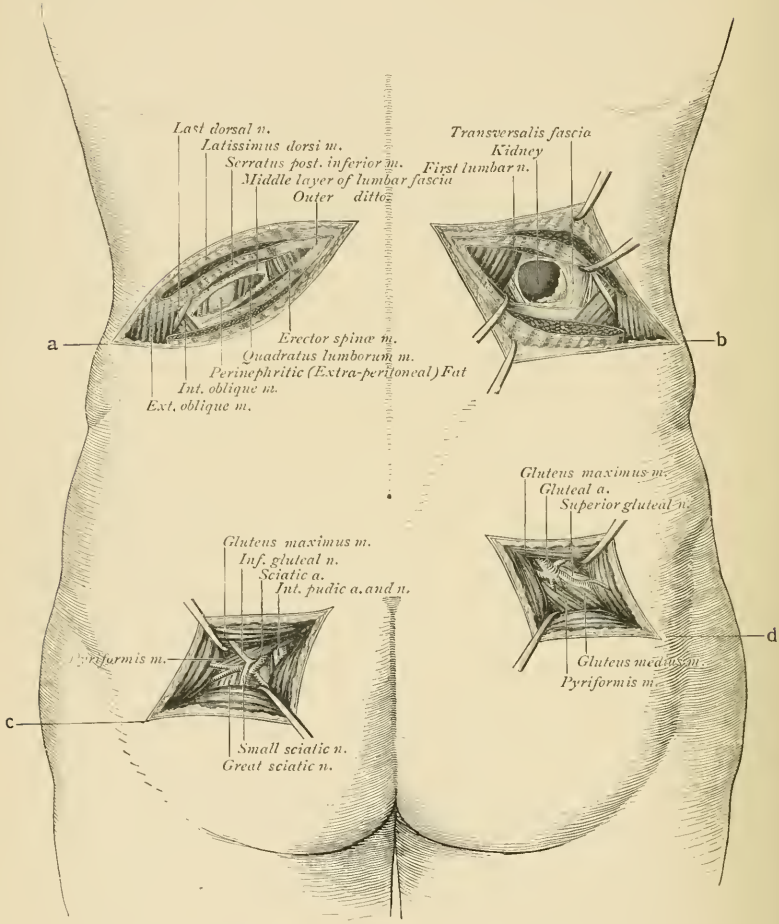

FIG. 87.—(*a*) and (*b*) Nephrotomy. (*c*) Ligature of the sciatic and internal pudic arteries, and exposure of the great sciatic, small sciatic, and internal pudic nerves. (*d*) Ligature of the gluteal artery and exposure of the superior gluteal nerve.

appears from beneath the psoas, and runs obliquely downwards and outwards upon the iliac fascia. Running transversely above the nerve is the iliac branch of the *ilio-lumbar artery.*

147. The next step in the dissection is to raise the **Spermatic Artery** and the *genito-crural nerve,* along with the peritoneum, from the surface of the psoas. The nerve descends upon the psoas, and its genital branch accompanies the spermatic artery into the inguinal canal to form one of the constituents of the cord.

The *genito-crural nerve* has been resected by HEINLEIN in Nürnberg, in a case of spermatic neuralgia with severe testicular pains spreading out over the inferior abdominal and upper femoral regions. After dividing the abdominal wall and stripping off the peritoneum, the common iliac artery was exposed as far as the point where the ureter crosses it. Both the genital and crural branches of the nerve were distinctly visible, the former lying upon and the latter close to the artery.

148. The Ureter, which descends almost vertically in front of the bifurcation of the common iliac artery, is also stripped off somewhat farther towards the middle line, above the place where it crosses the bifurcation of the common iliac to enter the true pelvis. The *genito-crural nerve* passes downwards close to the common iliac artery, and its crural division crosses over (lies upon) the anterior surface of the external iliac artery. In front of the vertebral column is the bifurcation of the aorta.

149. The Inferior Mesenteric Artery passes vertically downwards upon the aorta; it may also be lifted off along with the peritoneum. About 3 cm. above the bifurcation of the aorta, a lumbar artery is seen passing outwards.

The common iliac artery can, as proposed by MITCHELL BANKS, MARMADUKE SHEILD, and others, be more easily ligatured, under certain conditions, *by opening the peritoneal cavity.*

150. External Iliac Artery (Fig. 88). Incision close above and parallel to the middle third of POUPART'S ligament. Division of the skin and well-developed superficial fascia; the superficial epigastric artery which ascends vertically in the fascia must be divided. After dividing the tendon of the external oblique, the internal oblique and transversalis muscles are detached upwards from out of the groove of POUPART'S ligament with the handle of the scalpel, and the dense transversalis fascia is divided. The artery, together with some lymphatic glands, lies beneath some fatty tissue under POUPART'S ligament; internal to it is the vein, and external to it the fascia of the psoas muscle. The *anterior crural nerve* lies deeply between this muscle and the edge of the iliacus, about 2 cm. ($\frac{3}{4}$ in.) external to the artery. Upon the artery is the slender crural branch of the genito-crural nerve, which supplies the skin of the inner half of the front of the thigh in its upper third.

The branches of the external iliac artery, namely, the *deep epigastric*

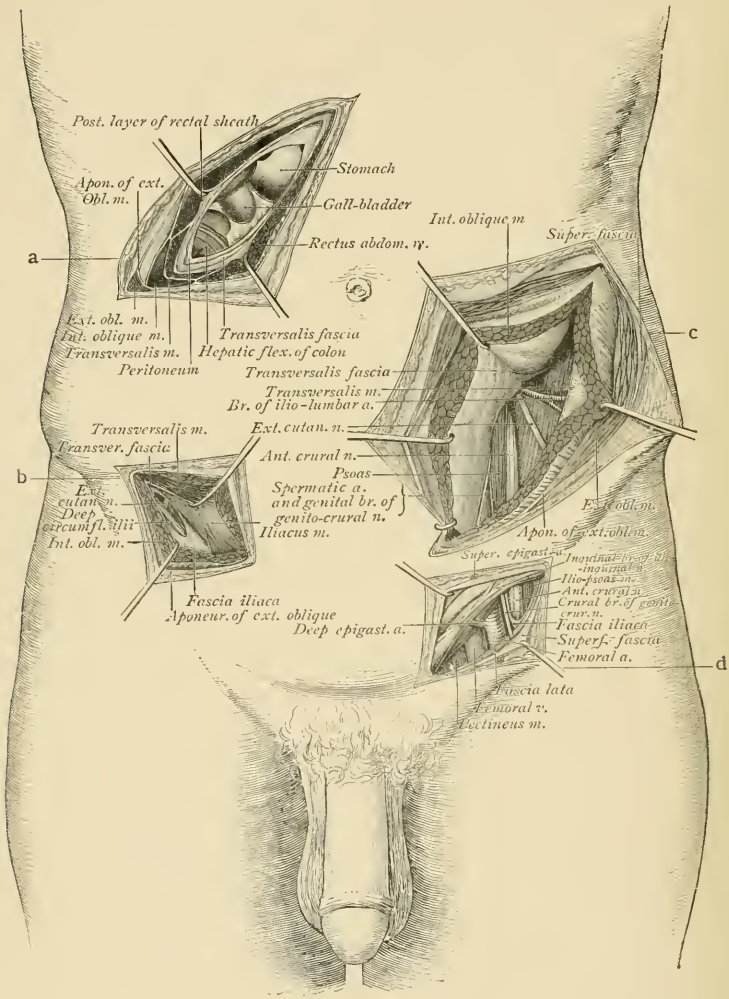

FIG. 88.— (*a*) Cholecystotomy. (*b*) Ligature of the deep circumflex iliac artery. (*c*) Ligature of the common iliac artery. (*d*) Ligature of the common femoral artery.

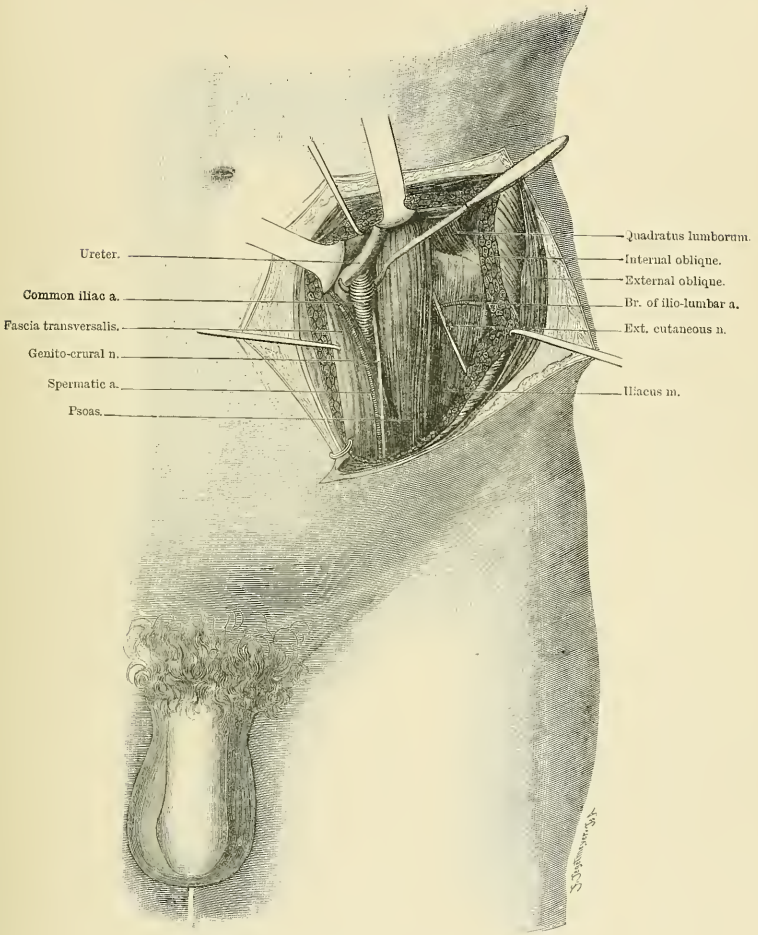

FIG. 89.—Ligature of the common iliac artery.

and the *deep circumflex iliac* arteries, may be exposed at their origin above POUPART'S ligament, below the abdominal muscles and the fascia transversalis, by the same incision as that for the external iliac artery.

151. Deep Epigastric Artery in the Anterior Abdominal Wall (Fig. 90). Incision three finger-breadths above and parallel to the inner half of POUPART's ligament, dividing skin, superficial fascia, the strong oblique fibres of the aponeurosis of the external oblique, and

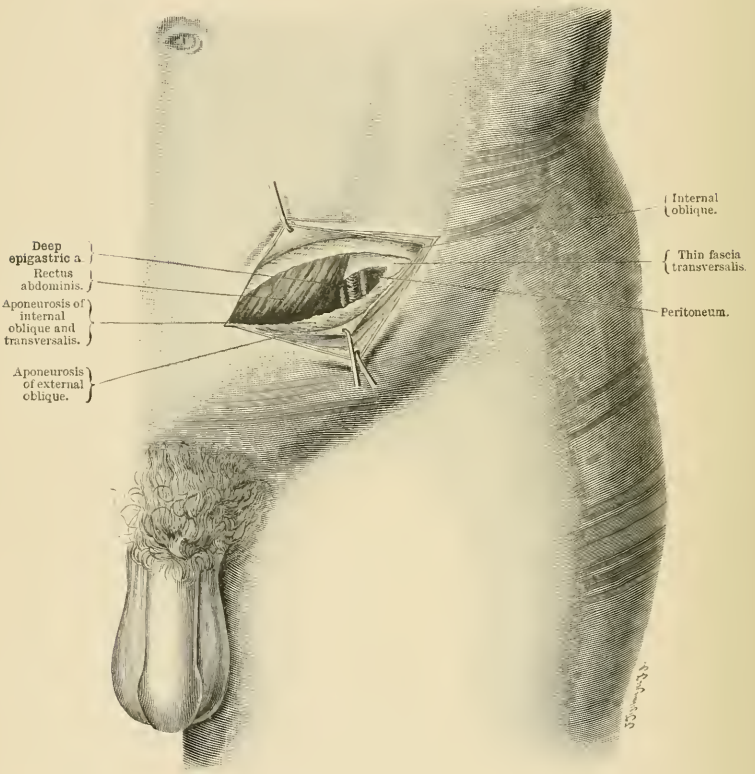

FIG. 90.—Ligature of the deep epigastric artery.

the transverse fibres of the aponeurosis of the internal oblique and transversalis muscles, which fuse together to form the anterior layer of the sheath of the rectus. The outer edge of the rectus is exposed and drawn inwards. Beneath it, and covered by a very thin layer of connective tissue (fascia transversalis), is the extra-peritoneal fat, and upon it the

artery, ascending obliquely from below upwards and inwards under the edge of the rectus. After reaching the under surface of the rectus, the artery ascends over the semilunar fold of DOUGLAS to enter the sheath of the muscle.

152. Deep Circumflex Iliac Artery (Fig. 88). Incision above the outer third of POUPART'S ligament. Division of the skin, the superficial fascia, the strong oblique fibres of the external oblique, the thick ascending fibres of the internal oblique, and the transversalis muscle. Between the two latter muscles are some vessels and branches of the ilio-inguinal nerve. The transversalis fascia is now divided, and the peritoneum is carefully raised from the iliac fascia. After dividing the iliac fascia the artery is found lying parallel to POUPART'S ligament upon the iliacus muscle. The external cutaneous nerve passes obliquely downwards behind it. It is important to know the relation of parts along this incision, as it is often employed in opening psoas abscesses.

153. Internal Iliac Artery. Same incision as for the common iliac artery. The artery passes forwards from the bifurcation of the common iliac, upon the inner aspect of the psoas muscle, and in front of the sacro-iliac articulation. It then turns downwards into the true pelvis. The *ureter* which descends in front of the artery is raised up along with the peritoneum.

For the posterior division of the internal iliac artery, see the region of the buttock.

154. Obturator Artery and Nerve (Fig. 91). The artery is a branch of the anterior division of the internal iliac.

The incision—the same as for ligature of the internal circumflex branch of the profunda femoris—descends vertically from a point a finger-breadth internal to the middle of POUPART'S ligament. The skin, superficial fascia, and superficial layer of the fascia lata are divided. The internal saphenous vein which lies upon the fascia is drawn outwards. The strong pectineal fascia is divided just internal to the femoral vein. After defining the outer border of the pectineus muscle, the latter is separated from the os pubis and fascia over the obturator externus, and is drawn well inwards. The strong transversely striated fascia over the obturator externus muscle is now divided, and the finger, passed above the upper border of the muscle, feels for the under surface of the horizontal ramus of the pubis, below which the artery leaves the obturator foramen accompanied by the

155. Obturator Nerve which lies above it.

Thigh—Anterior Surface

156. Femoral Artery. It courses in a line from the middle of POUPART'S ligament directly downwards towards the middle of the posterior

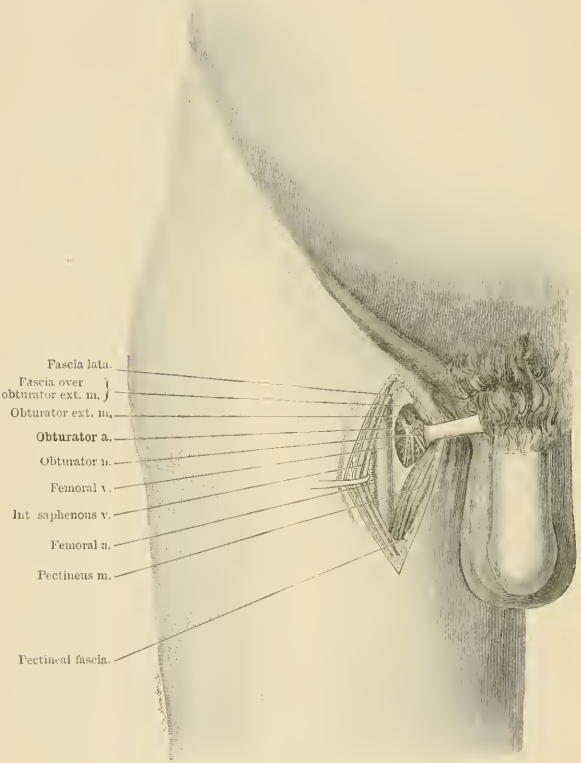

FIG. 91.—Ligature of the obturator artery.

aspect of the knee-joint, and passes from the inner towards the posterior surface of the femur at the junction of the middle and lower thirds of the bone. The incisions for ligaturing the artery, however, are made along a line extending from the middle of POUPART'S ligament to the

adductor tubercle, because in the lower part the artery is reached not from the front but from the inner aspect.

Common femoral artery (Fig. 92). Incision parallel to and below the middle third of POUPART'S ligament. Ligature of the superficial epigastric artery in the subcutaneous tissue. Division of the superficial layer of the fascia lata below POUPART'S ligament. The artery, along with the origins of the deep epigastric and deep circumflex iliac arteries, appears below the middle of the ligament lying upon the pubic bone, where it may be distinctly felt. The crural branch of the genito-crural nerve lies upon the sheath of the vessel. Internal to the artery is the femoral vein; external to it the fascia covering the ilio-psoas, and beneath the fascia the trunk of the anterior crural nerve at the outer edge of the psoas.

In the upper third, at the apex of Scarpa's triangle (Fig. 93). The skin and fascia lata are divided along the line already mentioned. The sartorius is drawn outwards. Under this muscle are the sheath of the vessel and branches of the anterior crural nerve, the large internal saphenous nerve being external to the artery. The femoral vein is to its inner side. Upon the fascia, external to the incision, is the middle cutaneous nerve, while the internal saphenous vein lies internal to the incision.

Above the opening in the adductor magnus (at the lower part of HUNTER'S canal). Longitudinal incision at the junction of the middle and lower thirds of the thigh (reckoned from the anterior superior iliac spine to the lower end of the femur), along the groove which can be felt between the adductor and extensor muscles. The internal saphenous vein is avoided, and after dividing the fascia, the sartorius muscle, which is recognised by its longitudinal fibres, is drawn inwards and backwards. The dissection is continued down to the fibres of the fascia covering the vastus internus, which are directed obliquely forwards. This fascia is divided at the anterior edge of the white glistening tendon of the adductor magnus, to which it is adherent. The artery lies very near the bone. Posterior and external to it is the vein, whilst the long saphenous nerve lies in front of the sheath. One must take care not to pass too far backwards, that is to say, behind the adductor tendon.

Upper Part of Popliteal Artery (Fig. 93). Incision behind the prominent cord-like tendon of the adductor magnus, which is inserted into the adductor tubercle. Posteriorly lie the sartorius, the tendons of the gracilis, and semi-tendinosus, and under the latter the muscular substance of the semi-membranosus. The long saphenous vein is found in the subcutaneous tissue. After dividing the fascia the muscular fibres of the sartorius appear. On continuing the dissection deeply between it and the tendon of the adductor magnus, the artery will be found upon the bone, behind the tendon, embedded in fat. The popliteal vein lies

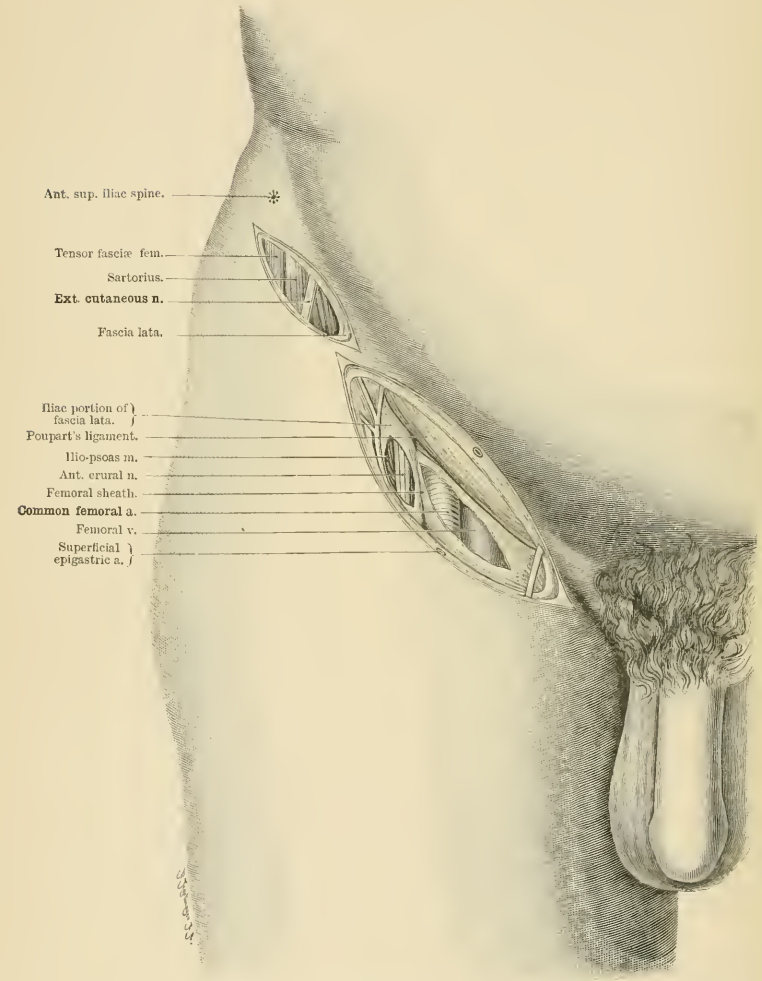

FIG. 92.—Ligature of the common femoral artery. Exposure of the external cutaneous nerve.

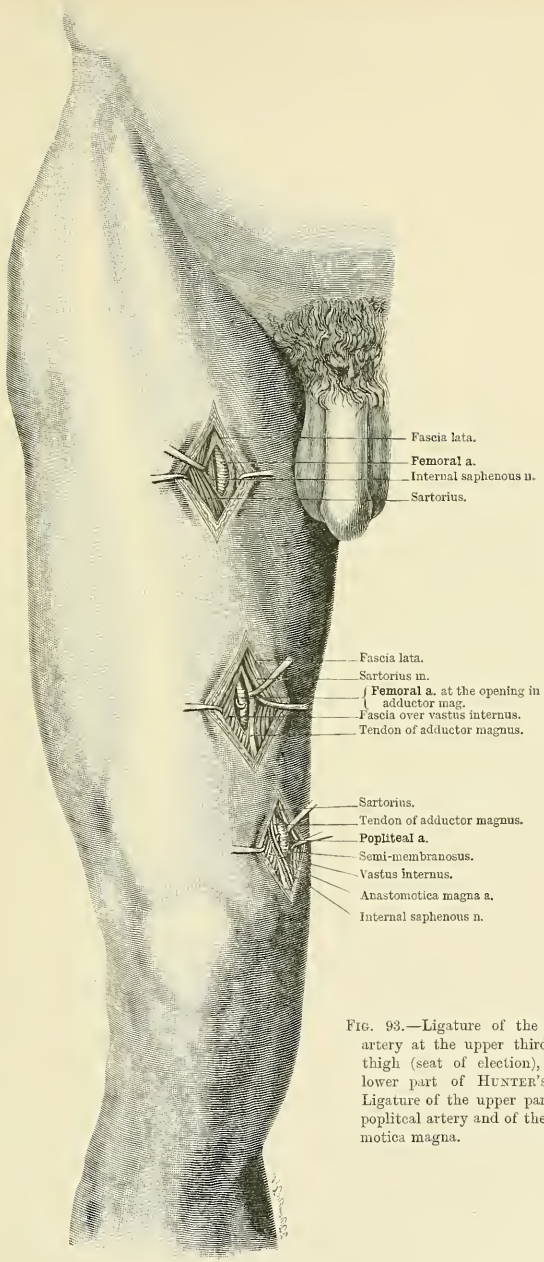

FIG. 93.—Ligature of the femoral artery at the upper third of the thigh (seat of election), at the lower part of HUNTER'S canal. Ligature of the upper part of the popliteal artery and of the anastomotica magna.

posteriorly, and between it and the integuments is the internal popliteal nerve. On drawing the sartorius muscle backwards, the *internal saphenous nerve* is exposed, accompanied by the superficial branch of the

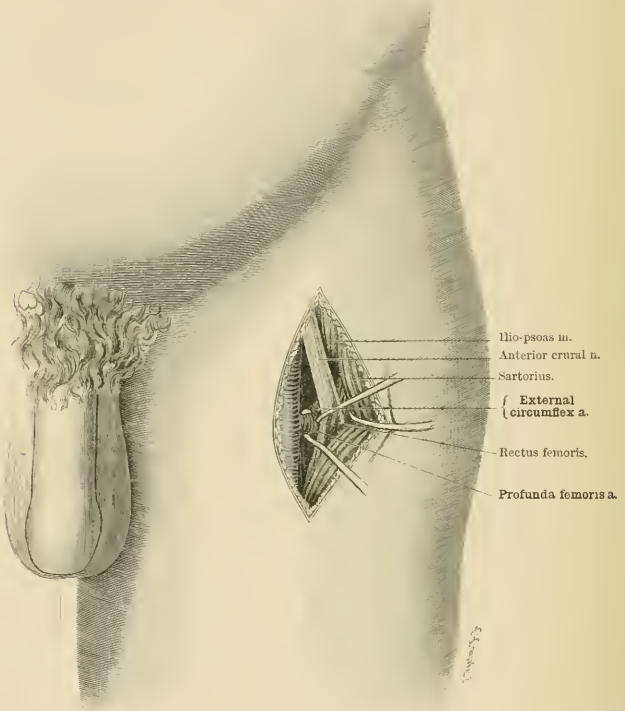

FIG. 94.—Ligature of the external circumflex and of the origin of the profunda artery.

anastomotica magna artery; they both pass backwards across the inner edge of the tendon of the adductor magnus.

Branches of the Femoral Artery

157. (a) Profunda Artery at its Origin, together with its External Circumflex Branch (Fig. 94). An incision is carried vertically downwards from a point two finger-breadths below and 1 cm.

external to the middle of POUPART'S ligament. The centre of the incision is to be opposite the level of the base of the great trochanter.

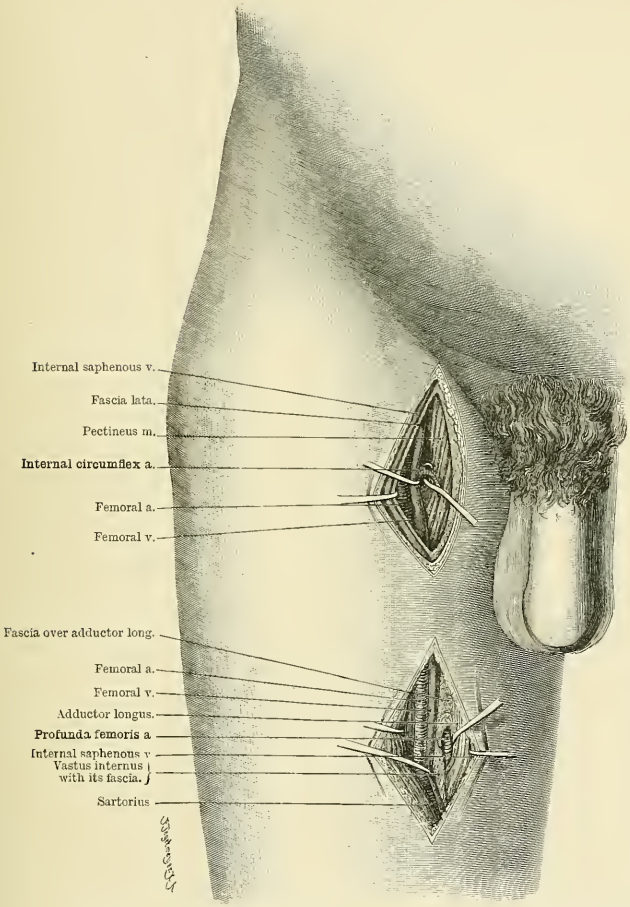

FIG. 95.—Ligature of the internal circumflex artery. Ligature of the profunda artery.

After dividing the skin and the strong fascia lata, the inner edge of the sartorius is exposed and drawn outwards. Under it is the inner edge of

the rectus, close to which, embedded in fat, are the branches of the anterior crural nerve, which descend in front of the ilio-psoas muscle near its insertion. On drawing the nerves outwards, the outer surface of the femoral artery appears, with the profunda artery passing outwards and downwards from it; whilst arising from the latter is the external circumflex artery, which passes transversely outwards beneath the rectus. The point of origin of the vessel corresponds to the lower part of the palpable projection of the ilio-psoas muscle.

(b). The Terminal Branch of the External Circumflex Artery lies upon the bone a finger-breadth below the most outwardly projecting part of the great trochanter. It may be exposed by a transverse incision dividing the skin, the strong fascia lata, the tendon of the gluteus maximus, and the glistening tendinous covering and muscular fibres of the vastus externus.

(c). Profunda Artery at the Upper Edge of the Insertion of the Adductor Longus (Fig. 95). An incision is made through the skin and fascia at the junction of the upper and middle thirds of the femur a hand-breadth below the fold of the groin, in the same line as for ligature of the femoral artery, that is, in the groove where the bone can be felt between the adductors and extensors. The sartorius is drawn outwards, but instead of dividing the deep fascia over the vessels (sheath of the vessels), as is done in ligaturing the femoral artery, the fascia over the adductor longus is divided internal to the femoral vessels, and the dissection is continued deeply along the fibres of the adductor longus towards the bone, as far as the inner aspect of the vastus internus, the fibres of which pass obliquely downwards and forwards. The artery will be found at the posterior attached edge of the vastus internus immediately above the upper end of the insertion of the adductor longus, under which it is continued downwards.

158. The Internal Circumflex Artery (Fig. 95) arises as a rule from the common femoral; in many cases, however, from the profunda femoris. An incision is carried vertically downwards from a point a finger-breadth internal to the middle of POUPART'S ligament. The long saphenous vein, which is met with upon the fascia, is drawn outwards. The pectineal fascia is divided internal to the saphenous opening, so as to expose distinctly the muscular fibres of the pectineus. The artery passes above the outer border of this muscle above its insertion into the femur, and thence along the lower border of the obturator externus directly downwards and backwards to the inner aspect of the femur, where it gives off a large branch which passes inwards.

The artery is freed from the fatty tissue at the inner aspect of the femoral vein. When arising from the profunda artery it passes inwards behind the femoral vein; but when from the common femoral it occasionally passes in front of the vein.

159. Anastomotica Magna Artery (Fig. 93). Incision through the skin and strong fascia along a line extending vertically upwards from

the adductor tubercle of the femur. The sartorius muscle is drawn backwards. Under it, embedded in fat, is the long saphenous nerve accompanied by the superficial branch of the anastomotica magna artery. To find the deep branch, pass in front of the prominent glistening tendon of the adductor magnus towards the bone in the substance of the vastus internus. The artery arises from the femoral in front of the opening in the adductor magnus, so that it may be ligatured by the same method as that for the femoral itself. The superior internal articular branch of the popliteal artery is seen lying transversely upon the bone above the internal condyle.

160. Anterior Crural Nerve (Figs. 92 and 94). This nerve may be exposed by the same dissection as for ligature of the external circumflex artery (p. 208); or it may be exposed by making a transverse incision below the middle third of POUPART'S ligament as if for ligature of the common femoral artery. The incision through the fascia lata is prolonged outwards through the sheath of the ilio-psoas muscle; immediately under which, along the inner aspect of the muscle, is the large nerve breaking up into several branches.

161. The Internal Saphenous Nerve (Fig. 96) accompanies the femoral artery as far as the opening in the adductor magnus, lying at first external to and then in front of the sheath of the vessels.

To expose the nerve *above the internal condyle of the femur* an incision is made in front of the sartorius, under which the nerve passes downwards and backwards; the nerve lies at the edge of the tendon of the adductor magnus. See ligature of the anastomotica magna artery.

162. External Cutaneous Nerve of the Thigh (Fig. 92). Incision through skin and fascia parallel to POUPART'S ligament a finger-breadth below the anterior superior iliac spine. The nerve lies under the fascia, 2 cm. ($\frac{3}{4}$ in.) below the spine, and descends obliquely downwards and outwards either at the outer edge of the origin of the sartorius, or over its anterior surface.

Thigh—Posterior Surface

163. Great Sciatic Nerve (Fig. 97). For its exposure *where it enters the buttock*, see p. 197.

To expose it at the *upper part of the thigh*, a vertical incision is made descending from the fold of the buttock from a point midway between the tuber ischii and the posterior border of the great trochanter.[1] After dividing the skin and fascia, the lower border of the gluteus maximus is exposed and drawn upwards so as to expose the outer edge of the biceps, which runs obliquely downwards and outwards. Between the fascia lata and the biceps is the small sciatic nerve. The large trunk of the great sciatic nerve lies deeper under the outer edge of the biceps,

[1] Or a transverse incision may be employed, as shown in Fig. 97.

which is to be drawn inwards. In the same region, but deeper and more internal, is a branch of the sciatic artery, which may be ligatured where it lies upon the adductor magnus muscle.

Below the middle of the thigh. Incision upon the posterior aspect of

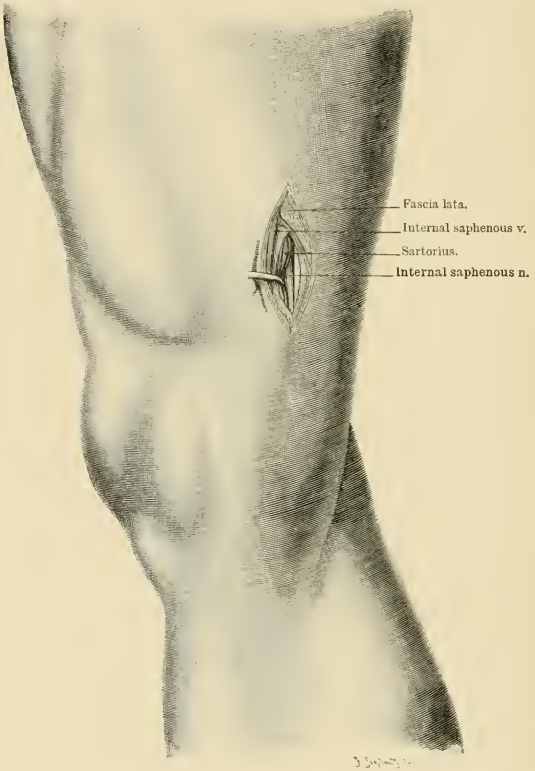

FIG. 96.—Exposure of the internal saphenous nerve at the internal condyle of the femur.

the thigh midway between the semi-tendinosus and semi-membranosus internally and the biceps externally. After dividing the skin, the small sciatic nerve appears either upon or under the fascia. On passing deeply between the above muscles, the great sciatic nerve will be found lying upon the posterior surfaces of the bone, having already frequently divided into its two main branches.

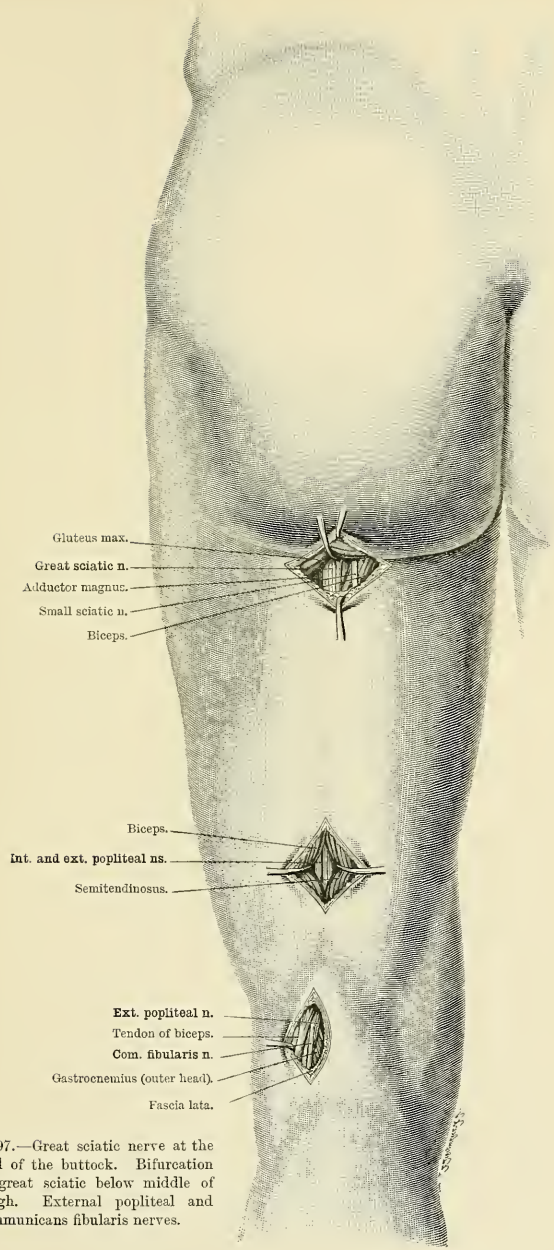

FIG. 97.—Great sciatic nerve at the fold of the buttock. Bifurcation of great sciatic below middle of thigh. External popliteal and communicans fibularis nerves.

Popliteal Space

164. Popliteal Artery (Fig. 98). A vertical incision is made over the middle of the popliteal space opposite the knee-joint. The short saphenous vein is to be avoided at the lower part of the incision; it ascends between the two heads of the gastrocnemius and opens into the

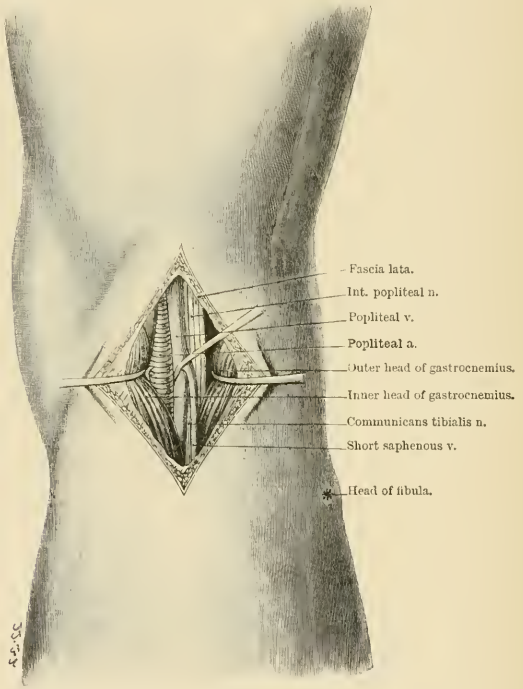

FIG. 98.—Ligature of the popliteal artery.

popliteal vein; to its outer side is the communicans fibularis nerve. The dissection is continued through the fat to the inner side of these structures and between the heads of the gastrocnemius. The internal popliteal nerve is the first structure to appear; on drawing it outwards the popliteal vein comes into view, closely bound down by a strong sheath to the subjacent popliteal artery, which lies above upon the fat covering the femoral trigone, and below upon the popliteus muscle.

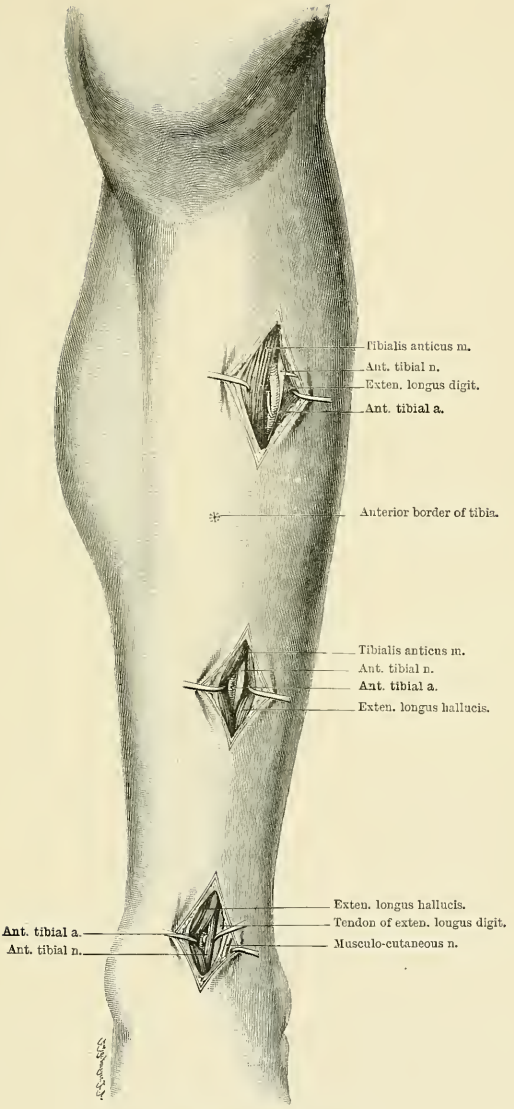

FIG. 99.—Anterior tibial artery and nerve.

165. The External Popliteal Nerve (Fig. 97) may be distinctly felt (and even seen) behind the head of the fibula, and still more distinctly upon the posterior surface of the external condyle of the femur.

An incision is made along the posterior edge of the tendon of the biceps, superiorly over the palpable prominence of the external condyle, inferiorly along a line extending upwards from the posterior border of the head of the fibula. The nerve lies immediately under the deep fascia at the outer edge of the gastrocnemius, and pierces the peroneus long muscle below the head of the fibula.

166. The communicating Peroneal Nerve is given off from the external popliteal (Fig. 97) above the head of the fibula. This nerve may also be felt through the skin upon the external condyle of the femur.

Leg—Anterior and External Surfaces

167. Anterior Tibial Artery (Fig. 99). The course of the anterior tibial artery is indicated by a line extending from the projection at the anterior aspect of the outer tuberosity of the tibia (= midway between the tubercle of the tibia and the head of the fibula) to the mid-point between the two malleoli.

At its upper end. An incision is carried downwards from a point midway between the tubercle of the tibia and the head of the fibula beginning a thumb's breadth below the outer tuberosity of the tibia. After dividing the skin and fascia, the outer edge of the tendinous origin of the tibialis anticus, which arises from the outer tuberosity, is seen ; it corresponds to the intermuscular space between the tibialis anticus and the extensor longus digitorum. This space is now opened up with the finger down to the interosseous membrane, through which the artery passes from behind forwards, about a finger-breadth below the head of the fibula. The anterior tibial nerve reaches the artery somewhat farther downwards, coming from the outer side under the extensor communis digitorum muscle. The transverse branches of the nerve to the tibialis anticus are given off very high up.

In the middle third. An incision is made 3 cm. (rather more than an inch) external to the anterior edge of the tibia along the palpable and often visible furrow at the outer border of the tibialis anticus muscle. The fascia is divided along the white line corresponding to the above furrow (a second white line somewhat farther outwards corresponds to the intermuscular septum between the extensor longus hallucis and the extensor longus digitorum), and the finger is passed down to the interosseous membrane, upon which is the artery, under cover of the muscular fibres of the tibialis anticus, between it and the extensor longus hallucis. The anterior tibial nerve lies upon the outer side of the artery.

In the lower third. Incision at the outer edge of the tendon of the tibialis anticus (the first large projecting tendon which lies external to

the anterior border of the tibia), between it and the tendon of the extensor longus hallucis. After dividing the skin and the strong fascia, the last-named tendon is clearly exposed and drawn outwards. The finger is now passed down towards the outer surface of the tibia. The first structure to appear external to the muscular fibres of the tibialis anticus muscle is the anterior tibial nerve, beneath which is the artery.

168. The Anterior Tibial Nerve close to its Origin (Fig. 100). The incision extends downwards through skin and fascia from a point opposite the outermost part of the outer tuberosity of the tibia, a finger-breadth in front of the head of the fibula. The intermuscular septum is indicated by a white line extending obliquely downwards and forwards, and the dissection is continued along it between the tendinous extensor longus digitorum and the peroneus longus. The anterior tibial nerve lies deeply in the above-mentioned septum, and passes obliquely downwards and inwards below the head of the fibula under cover of the extensor longus digitorum, whilst the musculo-cutaneous nerve extends vertically downwards along the same interval.

In its further course the anterior tibial nerve accompanies the anterior tibial artery in its entire length, and can be exposed by the same incisions. It lies to the outer side of the artery, except below, where it lies upon its anterior and inner aspect.

169. The Musculo-cutaneous Nerve (Fig. 100) *in the upper third of the leg* is exposed in the same wound as that just made for the anterior tibial nerve below the head of the fibula.

In the middle third of the leg. Divide the skin and fascia along the anterior edge of the prominence of the peronei muscles (longus superiorly, brevis inferiorly), and pass in between these muscles and the extensor longus digitorum. On drawing the peroneal muscles outwards, the nerve will be found at the bottom of the interspace, becoming more superficial as it descends.

The nerve pierces the fascia *at the junction of the middle and lower thirds of the leg*, where it may be exposed by an incision midway between the anterior border of the tibia and the posterior border of the fibula. The nerve can occasionally be felt through the skin in this situation.

Leg—Posterior and Inner Surfaces

170. Posterior Tibial Artery above the Origin of its Peroneal Branch (Fig. 101). Incision downwards along the middle line, beginning at the level of the head of the fibula three finger-breadths below the popliteal crease. In dividing the fascia, the short saphenous vein and communicans tibialis nerve are avoided and drawn outwards. The line of junction of the two heads of the gastrocnemius is sought for and the tendinous raphe is freely divided. The large vessels and nerves

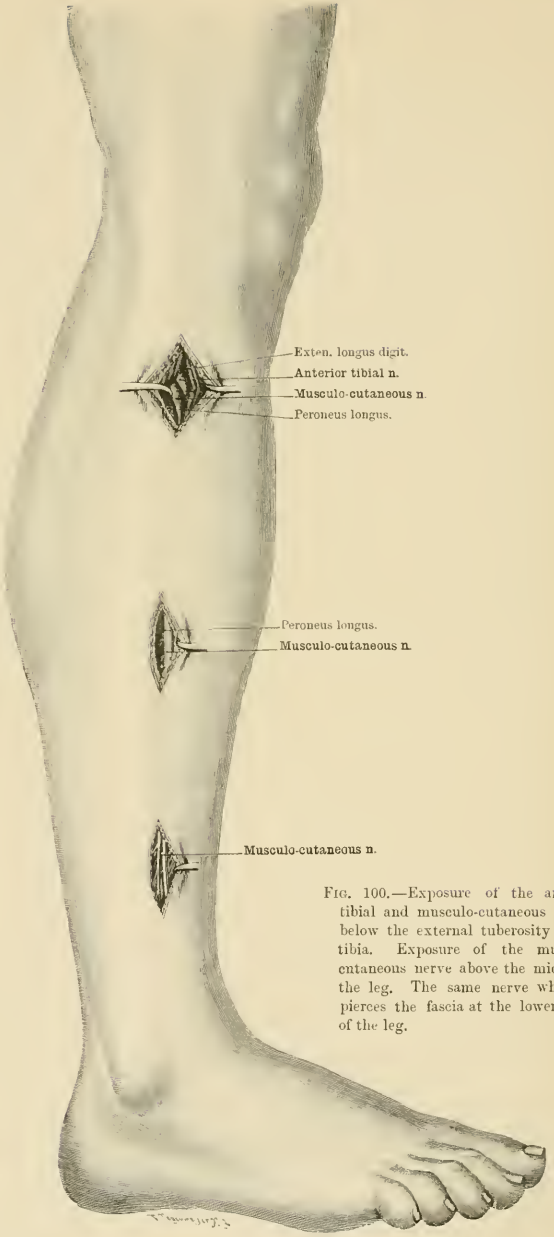

FIG. 100.—Exposure of the anterior tibial and musculo-cutaneous nerves below the external tuberosity of the tibia. Exposure of the musculo-cutaneous nerve above the middle of the leg. The same nerve where it pierces the fascia at the lower third of the leg.

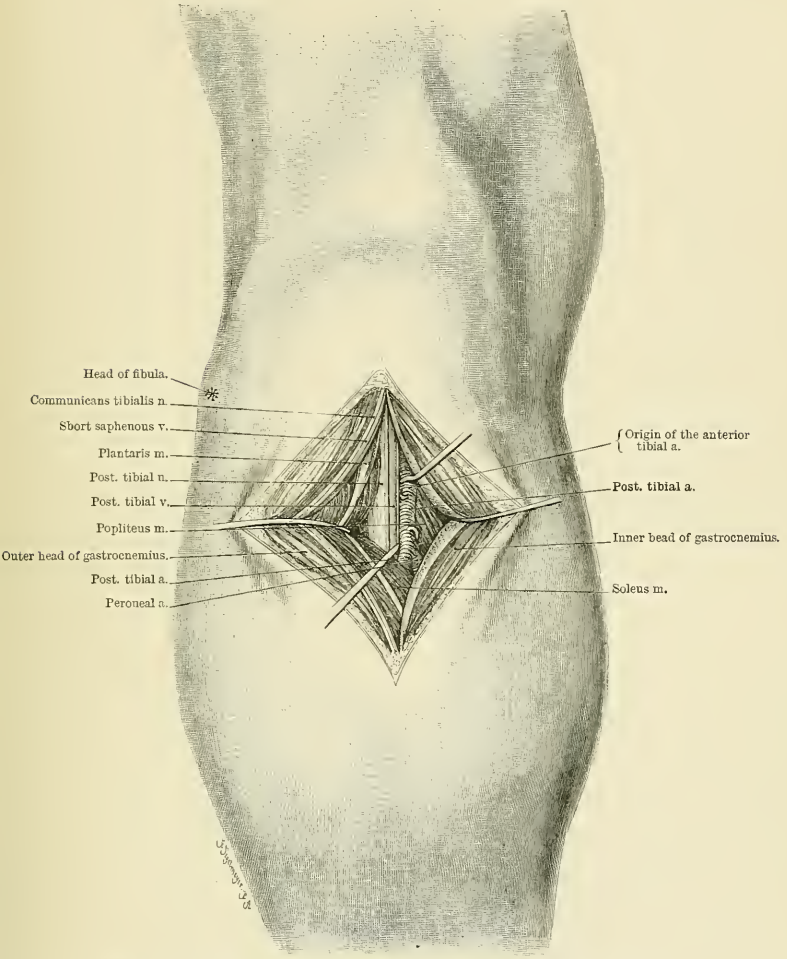

FIG. 101.—Ligature of the posterior tibial artery above the origin of the peroneal.

to the heads of the gastrocnemius are drawn aside. Beneath the outer head of the gastrocnemius is the upper border of the soleus extending

obliquely from above downwards and inwards; and upon it, also passing downwards and inwards, is the slender tendon of the plantaris muscle. The posterior tibial artery begins at the bifurcation of the popliteal, opposite the lower border of the popliteus and upper border of the soleus muscles. The edge of the latter muscle must be drawn downwards, or better nicked, in order to reach the posterior tibial artery, the corresponding vein and nerve being drawn outwards. The anterior tibial artery passes to the front through the interosseous membrane about $2\frac{1}{2}$ inches below the line of the knee-joint (a finger-breadth below the lowest part of the head of the fibula). The tendinous surface of the soleus can be distinctly seen descending obliquely inwards towards the inner border of the tibia, under the inner head of the gastrocnemius.

171. Posterior Tibial Artery below the Origin of its Peroneal Branch (Fig. 102). The incisions are made upon the inner aspect of the leg in the direction of a line extending from the lower edge of the internal tuberosity of the tibia to a point midway between the internal malleolus and the tendo Achillis.

In the upper half. The incision lies half an inch behind the inner border of the tibia. The long saphenous nerve and vein (the latter in front) run in the line of the incision, and care must therefore be taken to avoid them. After dividing the fascia, the inner border of the gastrocnemius appears, and is drawn aside with a blunt hook. The oblique fibres of the subjacent soleus are now seen arising by a broad attachment from the tibia. They are to be divided until the strong obliquely striated deep fascia which is attached to the posterior surface of the tibia is exposed, on dividing which the muscular fibres of the flexor longus digitorum come into view. The finger is now introduced into the wound and directed outwards between this muscle and the fascia covering it; the artery will be felt lying upon the tibialis posticus muscle $1\frac{1}{4}$ inch beyond the inner border of the tibia. The large posterior tibial nerve is beyond the artery, that is to say, to its outer side. The tibialis posticus muscle lies upon the interosseous membrane. One must be careful not to pass between the tibia and the flexor longus digitorum. The mistake which is most frequently made is to pass in between the gastrocnemius and the soleus, instead of dividing the whole thickness of the latter.

In the lower third. An incision is carried downwards from the angle at the upper end of the visible and palpable furrow between the inner border of the soleus and the deep flexors (the flexor longus digitorum lying next the inner border of the tibia).

The long saphenous vein and nerve are to be avoided in dividing the skin and fascia. The free inner border of the soleus is then exposed and drawn backwards, when the tendon of the flexor longus digitorum (with its muscular fibres behind it) will be seen lying upon the tibia. On dividing the thin fascia covering the deep flexors, the artery will be

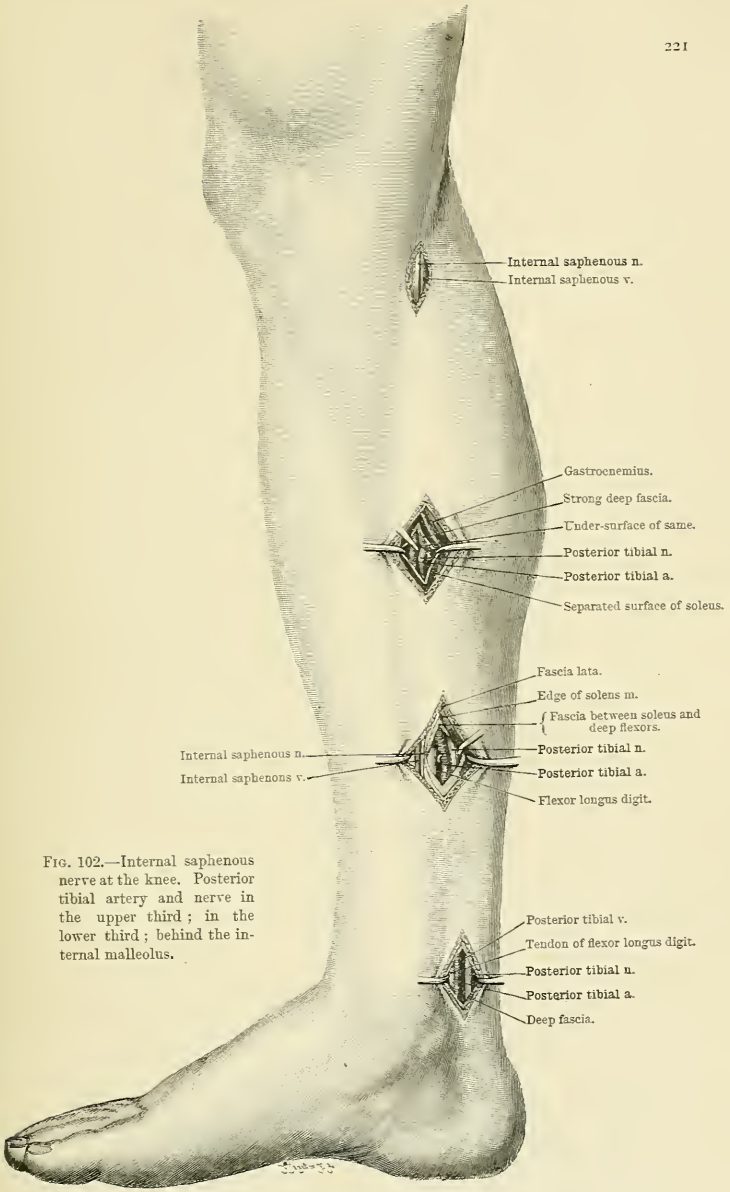

FIG. 102.—Internal saphenous nerve at the knee. Posterior tibial artery and nerve in the upper third; in the lower third; behind the internal malleolus.

found immediately under it to the outer side of the flexor longus digitorum. The posterior tibial nerve lies still more external.

Behind the internal malleolus. Incision midway between the posterior border of the internal malleolus and the tendo Achillis, dividing the skin, superficial fascia, and the strong transversely striated deep fascia. Between the internal malleolus and the artery are the tendons of the tibialis posticus and flexor longus digitorum, which lie in the order mentioned from before backwards. Behind the artery is the large posterior tibial nerve, and behind it again the tendon of the flexor longus hallucis. In this operation care must be taken not to pass in amongst the fat lying in front of the tendo Achillis.

172. Internal Saphenous Nerve (Fig. 102). *At the knee.* An incision is made immediately behind the inner tuberosity of the tibia at the posterior edge of the sartorius, beneath which the nerve descends, in the groove between it and the tendon of the gracilis. The internal saphenous vein, which can be felt through the skin, lies upon the fascia in front of the nerve.

In the leg. The nerve, accompanied by the internal saphenous vein, runs for its whole length along the inner border of the tibia, and in the line of the incisions for ligaturing the posterior tibial artery.

At the ankle-joint. The nerve along with the internal saphenous vein can be felt at the anterior border of the internal malleolus.

173. Peroneal Artery (Fig. 103). The peroneal artery arises from the posterior tibial in the upper third of the leg. The course of the vessel is indicated by a line continued from the popliteal artery down along the inner part of the posterior surface of the fibula. The posterior surface of the fibula may be felt through the skin along the whole length of the leg. The incisions for ligaturing the artery are made along a line drawn from the posterior border of the head of the fibula to a point midway between the exterior malleolus and the tendo Achillis.

In the upper part of the leg. Incision at the posterior surface of the fibular behind the peroneal muscles. The communicans fibularis nerve is exposed, and the deep fascia is divided behind the peronei. The origin of the soleus is detached from the fibula and from the glistening tendinous fascia covering the flexor longus hallucis, which lies upon the posterior surface of the bone. After dividing this fascia the dissection is continued deeply between it and the flexor longus hallucis, until the oblique inner border of the latter is reached, above which the artery will be found previous to its entering the substance of the muscle. The posterior tibial nerve lies still deeper, that is to say, internal to the artery.

In the lower half. Incision again at the posterior surface of the fibula. After dividing the fascia the thick outer border of the soleus is exposed and drawn inwards, exposing beneath it the fibres of the flexor longus hallucis, covered by a tendinous-looking fascia. On separating the flexor longus hallucis from the posterior surface of the fibula, the

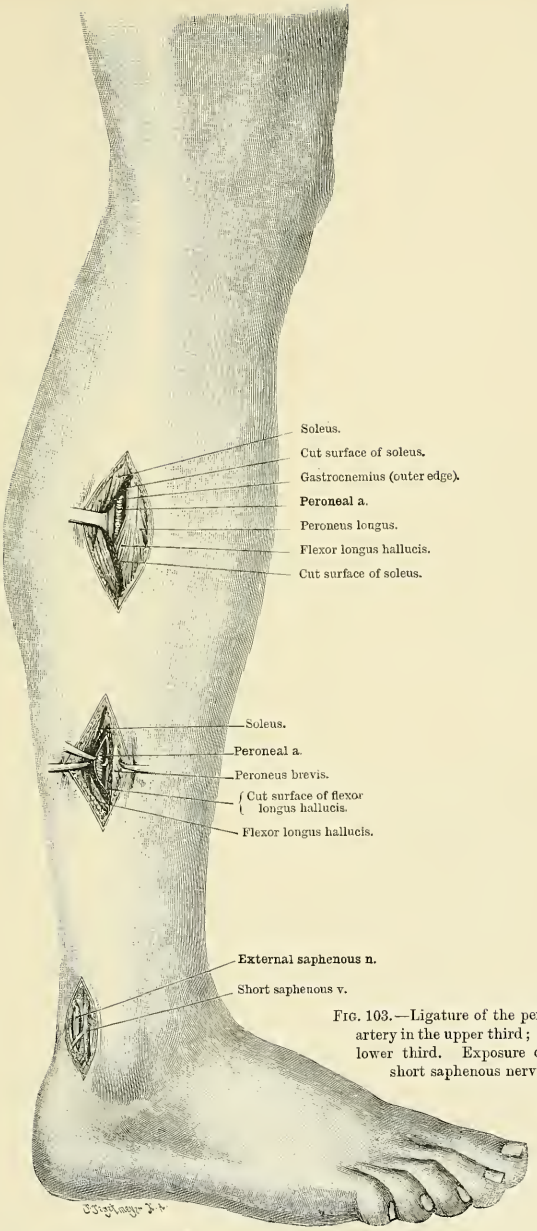

FIG. 103.—Ligature of the peroneal artery in the upper third; in the lower third. Exposure of the short saphenous nerve.

artery will be found at the outer border of the tibialis posticus muscle which lies upon the interosseous membrane.

174. Cutaneous Branch of the External Popliteal Nerve. This nerve arises from the external popliteal in common with the communicans fibularis. The latter descends upon the posterior surface of the limb to unite with the communicans tibialis in the lower half of the leg to form the external saphenous nerve; the former pierces the fascia at the outer aspect of the upper third of the leg and supplies the skin upon its outer surface. (In sciatica the pain is often particularly severe along the area of distribution of these branches.) The branch of the external popliteal from which these two cutaneous nerves spring is exposed by the same incision as that for the external popliteal nerve itself, namely, along the edge of the biceps tendon behind the external condyle of the femur.

The External Saphenous Nerve (Fig. 103) is exposed by making an incision midway between the external malleolus and the tendo Achillis; the nerve lies either upon or under the fascia. In front of it is the external saphenous vein.

175. Communicans Tibialis Nerve (Fig. 101). This nerve has already been exposed in ligaturing the popliteal and the upper part of the posterior tibial arteries. It accompanies the external saphenous vein, descends vertically upon the fascia along the middle of the upper two-thirds of the calf, and unites with the communicans fibularis to form the external saphenous nerve.

176. The Posterior Tibial Nerve (Fig. 102) accompanies the posterior tibial artery, which it crosses from within outwards at its upper part.

Foot

Plantar Vessels and Nerves. The deeper structures which lie along the middle of the sole of the foot are covered by the flexor brevis digitorum, so that to expose them we pass in (analogous to the palm of the hand) at one or other side of this muscle, between it and the two lateral masses of muscles, the superficial ones being the abductors of the great and little toes.

177. Plantar Arteries at their Origin from the Posterior Tibial (Fig. 104). An incision beginning a finger-breadth below and in front of the sustentaculum tali is carried horizontally backwards along the inner border of the foot above the prominence of the abductor hallucis muscle. After dividing the skin and fascia the abductor hallucis is exposed, and separated downwards from the subjacent deep fascia. On dividing the latter the plantar vessels will be found opposite a line continued downwards from the posterior border of the internal malleolus. The posterior tibial nerve lies immediately below the artery.

178. Internal Plantar Artery and Nerve (Fig. 105). Incision in

a line from the point of the heel to the great toe, beginning in front of the ball of the heel and extending forwards. The skin, a thick layer of fat, and the dense longitudinal fibres of the plantar fascia are divided. The muscular substance of the abductor hallucis is exposed, and the artery is found passing under it into the sole. The flexor brevis digitorum lies external to the artery.

179. The Internal Plantar Nerve lies beside the corresponding artery, which is much smaller. Both structures are covered by a thick layer of fat; beneath them (deeper) is the tendon of the flexor longus hallucis.

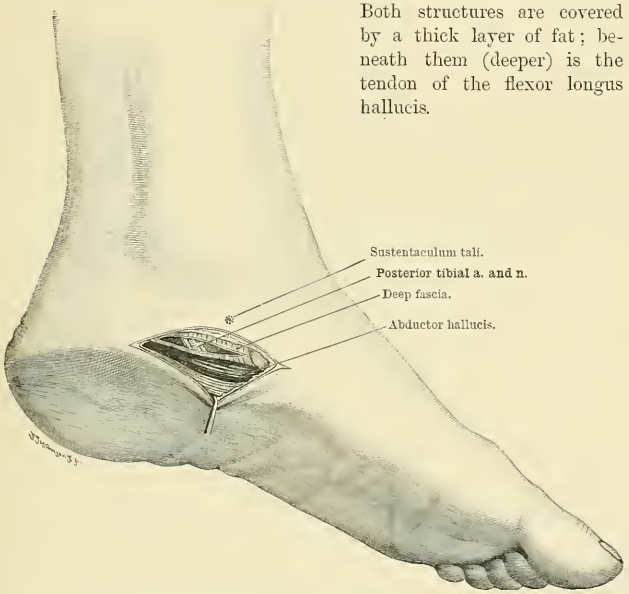

FIG. 104.—Plantar arteries at their origin from the posterior tibial artery. Posteriorly, the posterior tibial nerve.

180. External Plantar Artery (Fig. 105). Incision from immediately in front of the ball of the heel forwards in the direction of a line from the point of the heel to the fourth toe. After dividing the skin, abundant fat, and the strong plantar fascia, the muscular fibres of the adjacent edges of the flexor brevis digitorum and abductor minimi digiti are exposed, and the artery is found lying between them.

181. The External Plantar Nerve lies beside the corresponding artery, the former being relatively much smaller than the latter.

182. The Plantar Arch at the 1st Interosseous Space (Fig. 106).

Incision backwards in the hollow outside the ball of the great toe, in the direction of a line from the second toe to the point of the heel, through skin, abundant fat, and the strong plantar fascia. Upon the inner side of the wound is the tendon of the flexor longus hallucis along with posteriorly the muscular fibres of the abductor hallucis, and anteriorly those of the flexor brevis hallucis; these structures are drawn inwards. Upon the outer side of the wound

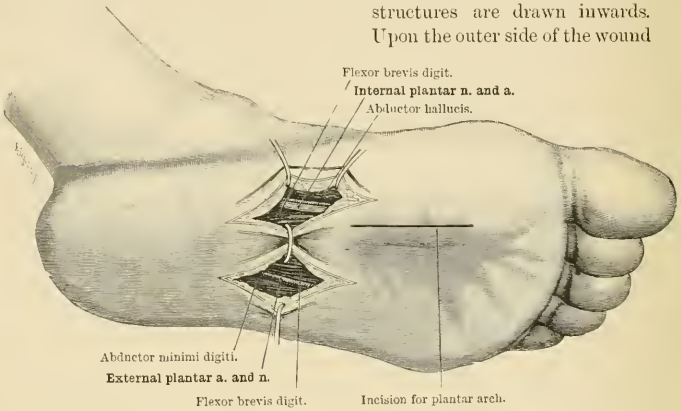

FIG. 105.—Internal and external plantar arteries and nerves.

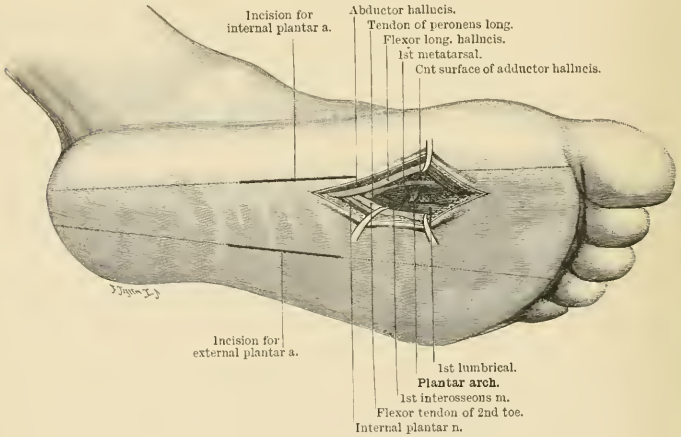

FIG. 106.—Plantar arch.

is the large internal plantar nerve with its branches to the second and third toes; these are drawn towards the little toe. The nerve to the great toe does not come into view. The short flexor tendon of the

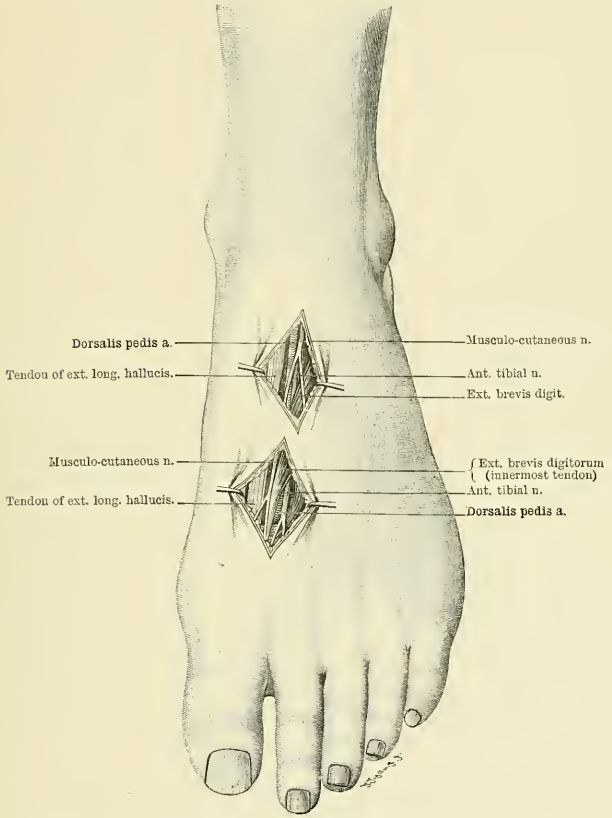

FIG. 107.—Dorsalis pedis artery, and anterior tibial and musculo-cutaneous nerves.

second toe and the subjacent long flexor tendon with the 1st lumbrical muscle are exposed and drawn outwards, the powerful adductor hallucis muscle which lies still deeper being then exposed. After cutting through this muscle the artery will be found deeply at the 1st interosseous

space where it joins the dorsalis pedis artery. The artery lies upon the interosseous muscles. To the inner side of its termination is the projecting border of the 1st metatarsal bone, to the base of which is inserted the tendon of the peroneus longus muscle.

183. Dorsalis Pedis Artery (Fig. 107). The course of the vessel is indicated by a line extending from midway between the two malleoli to the hinder end of the 1st interosseous space.

At the ankle-joint. The skin is divided longitudinally midway between the two malleoli. The internal branch of the musculo-cutaneous nerve is seen running in the direction of the incision, and is drawn outwards. The fascia along with fibres of the anterior annular ligament is divided over the tendon of the extensor longus hallucis (here partly muscular), which is drawn inwards. The artery is now exposed, the anterior tibial nerve lying upon its outer aspect.

Below the ankle. Incision along the line already mentioned. The inner branch of the musculo-cutaneous nerve which lies upon the fascia is drawn outwards. Under the fascia lies internally the tendon of the extensor longus hallucis, and externally the innermost tendon and the muscular fibres of the extensor brevis digitorum, which on being drawn downwards and outwards exposes the artery which lies beneath it upon the tarsal ligaments. The anterior tibial nerve is upon the outer side of the artery.

Where it dips down into the 1st interosseous space. An incision is made through the skin and fascia between the bases of the 1st and 2nd metatarsal bones. The internal branch of the musculo-cutaneous nerve is avoided and drawn outwards along with the internal saphenous vein. Internally is the innermost tendon of the extensor brevis digitorum, and still further inwards the broad tendon of the extensor longus hallucis. The artery, with the cutaneous termination of the anterior tibial nerve lying upon it, appears from beneath the outer edge of the extensor brevis tendon, and gives off the large 1st dorsal interosseous branch.

PART III

EXCISIONS AND RESECTIONS

I. GENERAL CONSIDERATIONS

If instead of simply making an incised wound it is our intention to remove a healthy or diseased portion of the body from its connections with the surrounding tissues, the term *excision* is used, an expression which it would be better to employ instead of the customary term *resection* when speaking of the bones and joints. Here again the main point is to make the first incision in such a way that the part to be removed is freely exposed with the least possible amount of injury. In the case of the joints, therefore, the first question to be considered is: What is the best incision for opening the joint?

The incision into the joint (arthrotomy) is the basis of every resection. Whether it be made large or small, that is, whether the usual incision is employed in its full length or not, depends upon the indication for operating. Whether after performing arthrotomy one is to proceed to arthrectomy, to partial or complete excision of the joint, capsule, synovial membrane, articular extremities, interarticular cartilage, and ligaments, will depend upon the conditions found when the joint is opened.

As regards technique, excisions are among the simplest of operations. When once the affected part is exposed, the next step is to free it from its surroundings as cleanly as possible, by separating the adjacent soft parts with sharp or blunt instruments close to the affected osseous structures. The more completely the bone is laid bare and freed from soft parts, the more orthodox is the resection. This simple rule is often broken by beginners.

Ollier's subcapsular and subperiosteal methods, which are so important in amputations, are equally important in resections. Recently

the *subcapsulo-periosteal method of resection* has been further developed (Vogt, König, Bergmann, Riedel, Tiling), and instead of separating the ligaments (especially the lateral ligaments) from the bone, the bony processes (tubercles, trochanters, epicondyles, malleoli) have been chiselled off along with the ligaments and preserved—a kind of *osteoplastic resection*. Both König and Tiling chisel off the bony processes in place of cutting through the ligaments, but employ different incisions. The processes are fixed again in position with ivory pegs. This might be termed the *subcortical method of resection*, as it consists essentially in raising up the outermost layer of the bone together with the periosteum. The advantage of this plan is that the osteoblastic layer of the periosteum is much better preserved than by separating the periosteum alone, and further that the chiselling off of ligamentous and capsular attachments from processes (apophyses) of any kind (condyles, epicondyles, tubercles, etc.) much more readily admits of the ligaments of the joint being retained in continuity with the periosteum of the articular ends. In the face of these advantages, this method deserves the widest employment. Separation of the periosteum and ligaments with a *sharp* elevator (raspatorium) close to the bone is a step towards it.

The choice of the incision is determined by the stipulation that no unnecessary injury is to be done to the vessels, tendons, muscles, and especially to the large and small nerve branches. The further steps will depend upon whether we have to deal with the mere opening of the joint (arthrotomy), as is done for the removal of effusions, loose bodies, circumscribed diseases of the capsule or bone; or with excision of the joint (arthrectomy), in which the capsule and the articular extremities are removed. The following are the differences which have to be made in the technique in the two cases.

In *arthrotomy* the capsule is divided down to the cavity of the joint in the same direction and to the same extent as the skin incision, and the cut edges of the capsule are seized with strong toothed forceps in order that they may be loosened from the bones in *undisturbed connection* with the overlying soft parts. It is here, therefore, that the subcapsulo-subperiosteal and subcortical methods find their full value.

In complete *arthrectomy*, on the other hand, the cavity of the joint remains unopened, and the soft parts are separated from the synovial membrane as far as its place of attachment or reflection on to the bone. The synovial sac is not opened until its outer surface is so thoroughly exposed as to admit of its complete excision. In this case also, the usual technique for arthrotomy—in which the capsule, ligaments, and periosteum are retained in uninterrupted connection, and injured as little as possible—may be employed in certain cases.

In cases in which all the diseased tissue has been completely extirpated, healing by first intention is to be aimed at, and may be obtained in a few days; in incomplete operations, stuffing with iodoform

gauze, with a possible secondary suturing some days later, is more certain.

The performance of resections and amputations, as well as of conservative operations on the extremities, has been rendered very much easier by the introduction of ESMARCH'S prophylactic method of preventing hæmorrhage. Before applying it, the limb is held up vertically for some time (P. BRUNS has showed that in this way the limb is rendered practically just as bloodless as by the application of an elastic bandage), then a gauze bandage is wound loosely round the limb above the seat of operation to protect the skin, and, lastly, a strong india-rubber tube is wound round the limb over the bandage, and fastened by a simple loop without making a knot, so that it may be loosened with rapidity. In the case of the upper extremity this is best done at the upper third of the upper arm, and in the lower extremity at the lower third of the thigh, because the muscular tissue is less abundant at these places, and no nerves are exposed to direct pressure.

U. LOWER EXTREMITY

184. Excision of the Phalanges and Metatarsal Bones (Fig. 108). From the rules given in making incisions in the fingers and toes, it is evident that only lateral incisions placed somewhat towards the dorsum are permissible, in order to avoid the nerves and tendons. In the case of the phalanges and their joints, the operation does less injury and the cicatricial contraction is less marked if two small lateral incisions are made. For the metatarsal bones it is sufficient to make a dorsal incision along the extensor tendons parallel to the branches of the musculo-cutaneous nerve. In order to obtain sufficient access the incision must extend over the adjacent joints. The head of the bone should always be exposed first, because its ligamentous connections are easier to separate than those at the base.

185. Resection of the Tarso-Metatarsus and Anterior Tarsus (Fig. 109). This is a very important operation in infective diseases (especially tubercle) of the anterior tarsal joints, because the cavities of the majority of the joints are in communication with one another. Separate synovial cavities are most frequently found at the joint between the 1st metacarpal and internal cuneiform, at the anterior and posterior surfaces of the cuboid, between the head of the astragalus and the scaphoid, and lastly between the astragalus and os calcis. In tubercular ostitis, which frequently begins in the bases of the metatarsal bones, resection of the bases and of the articular surfaces of the adjacent cuneiforms and cuboid is occasionally sufficient (tarso-metatarsal resection). When, however, the tarso-metatarsal joints are involved, it is safer to excise the scaphoid

as well as the bones above mentioned. If the disease is still more diffuse, the articular surfaces of the astragalus and os calcis must also be removed.

The resection is performed by means of two dorso-lateral incisions. The internal incision extends from the posterior third of the 1st metatarsal backwards as far as the inner aspect of the head of the astragalus, which is brought into view by abducting the foot; the posterior part of the incision divides the skin only, so as to avoid opening the part of the ankle-joint which projects forwards on to the

FIG. 108.—Resection of the phalanges. Resection of the 1st and 5th metatarsal bones.

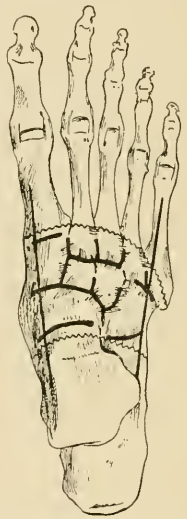

FIG. 109.—Resection of the anterior tarsus (usual arrangement of the synovial cavities).

neck of the astragalus. Beginning internal to the extensor tendons of the great toe, the incision divides the attachment of the tibialis anticus to the 1st metatarsal and internal cuneiform, and exposes the dorsal surfaces of the cuneiform and scaphoid bones. The under surfaces of those bones are now laid bare; the tendon of the tibialis posticus lies posteriorly and inferiorly.

The external incision, which is placed external to the extensor tendons, extends from the posterior third of the 5th metatarsal to the upper surface of the os calcis in front of the external malleolus. The tendon of the peroneus tertius is separated from its insertion into the base of the 5th metatarsal, and the dorsal aspect of the cuboid and outer

metatarsals are exposed. To lay bare the under surfaces of these bones, the tendons of the peroneus brevis and longus must be separated and drawn backwards, the latter from the groove upon the outer and under surfaces of the cuboid.

The bases of the metatarsal bones and the articular surfaces of the astragalus and os calcis are now removed.

The shortened foot is exceedingly useful both for support and locomotion.

186. Resection of the Mid-Tarsus (Figs. 110, 111, 112). This operation is most frequently performed in the form of a cuneiform excision in talipes varus. This wedge-shaped excision gives excellent results, especially in old-standing club-foot; indeed, if the resection is

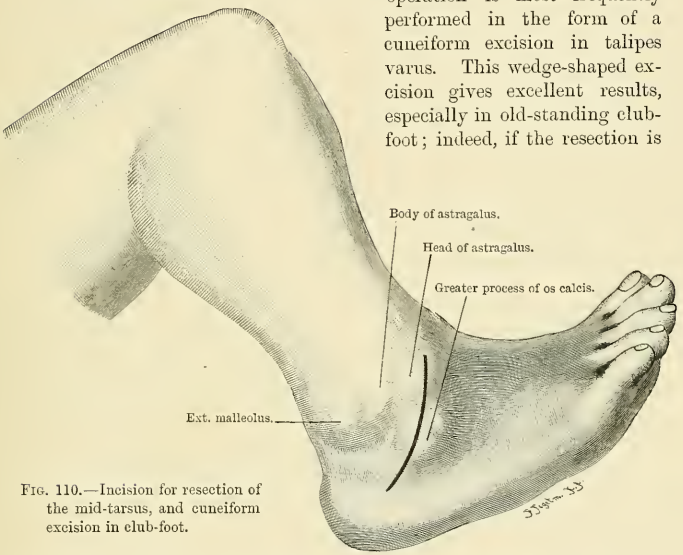

FIG. 110.—Incision for resection of the mid-tarsus, and cuneiform excision in club-foot.

sufficiently extensive, the results are better than by any other method of operation.

The incision is begun over the dorsal aspect of the astragalo-scaphoid joint, and passes obliquely downwards and backwards towards the outer border of the heel. The musculo-cutaneous nerve is seen lying upon the fascia at the upper angle of the wound, while the short saphenous nerve appears at its lower angle; these nerves are drawn aside, and one or two veins are seized and twisted. After dividing the fascia, the tendon of the peroneus tertius appears at the upper end of the wound, while at its lower part are the peroneal tendons in contact with the outer surface of the os calcis. After slitting up their sheaths, the tendons are

drawn aside with blunt hooks. The capsule is divided over the head of the astragalus, and the joint opened. The attachment of the capsule is then separated from the neck of the astragalus as far as the groove on its under surface. After exposing and drawing downwards the upper border of the extensor brevis digitorum, the calcaneo-cuboid joint is opened. The neck of the astragalus and the greater process of the os calcis are now divided with a chisel, and drawn well out of the wound with a sharp double hook, so that they may be completely freed from their ligamentous connections, and removed. In order that the foot may be dorsiflexed to less than a right angle by firmly pressing together the osseous surfaces, it is necessary, in aggravated cases of club-foot, to shell out the whole of the scaphoid and to chisel off a portion of the cuboid. The

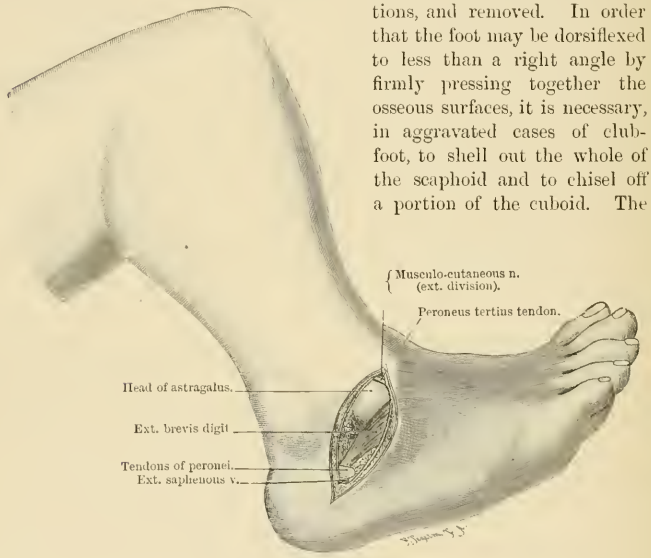

FIG. 111.—Excision of an osseous wedge in club-foot. First stage: exposure of the head of the astragalus by dividing the capsule, the tendons and muscles being avoided.

introduction of a drainage-tube is not necessary, as no cavity remains, and no secondary hæmorrhage is to be anticipated. The wound is closed by a continuous suture. The foot is kept dorsiflexed and the knee bent by means of a plaster of Paris bandage, which extends upwards beyond the knee. To make sure of a good result, it is generally necessary to divide the tendo Achillis.

The important points to be attended to in order to obtain a good result, are, to ensure primary healing, to see that the foot is capable of being flexed to less than a right angle, and to prevent any tendency to equinus by tenotomy of the tendo Achillis.

187. Excision of the Astragalus (Fig. 113). It is unnecessary to give a special description of excision of each of the smaller tarsal bones, as these are operations which are seldom called for. Excision of the astragalus and os calcis, however, is often necessary in tuberculosis, in injury, and in club-foot, the two latter conditions calling especially for excision of the astragalus.

It suffices as a rule to make a free longitudinal incision upon the antero-external aspect of the ankle, as described by VOGT for resection of the ankle-joint. This incision begins a hand-breadth above the ankle at the anterior surface of the fibula, and extends downwards to the outer side of the extensor tendons (peroneus tertius) and the branches of the musculo-cutaneous nerve, over

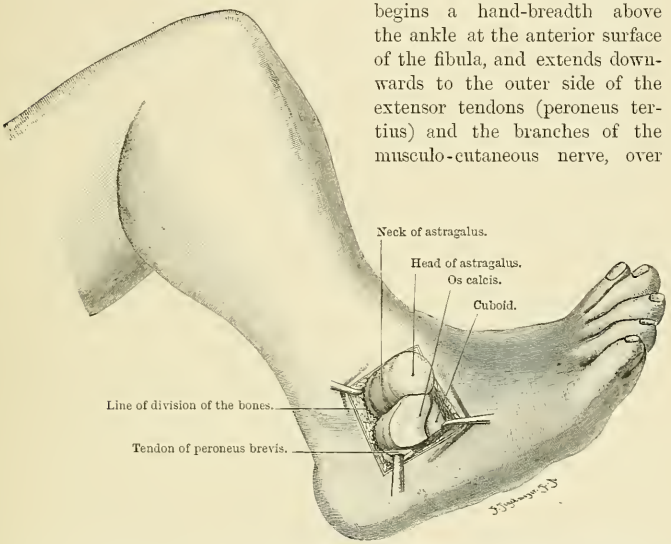

FIG. 112.—Excision of an osseous wedge in club-foot. Second stage: joint surfaces of head of astragalus and greater process of os calcis exposed. The place at which the bones are divided is indicated by a serrated line.

the outer surface of the astragalus to the tuberosity at the base of the 5th metatarsal bone. The incision enters the ankle and mid-tarsal (CHOPART'S) joints, exposing the body and head of the astragalus. The capsule of the joint is thoroughly separated from the neck of the astragalus, and the strong interosseous calcaneo-astragaloid ligament is divided. The capsule is also separated along the anterior borders of the lower ends of the tibia and fibula, and the anterior and posterior bands of the external lateral ligament of the ankle-joint are divided at the anterior and posterior surfaces of the body of the astragalus.

The ligamentous connection with the os calcis is detached externally and along the posterior border of the astragalus. By forcibly inverting the foot, the astragalus is now raised to such an extent that an elevator can be introduced under it so as to divide the ligamentous attachments upon the inner aspect.

188. Excision of the Os Calcis (Figs. 114 and 115). A longitudinal incision is made descending along the inner aspect of the tendo Achillis to the lower and hindermost part of the greater tuberosity of the os calcis, and from thence transversely around the heel, and forwards along its outer aspect to the tuberosity at the base of the 5th metatarsal bone. This gives sufficient room when the soft parts are flexible.

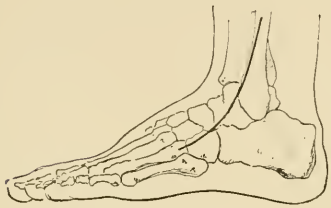

FIG. 113.—Excision of the astragalus (external incision).

The tendo Achillis is detached from the posterior surface of the tuberosity; and the joint capsule at the posterior and outer aspect of the os calcis, together with the calcaneo-fibular band of the external lateral

FIG. 114.—Excision of os calcis.

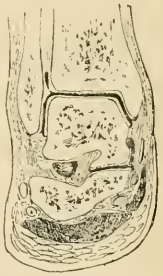

FIG. 115.—Coronal section through the ankle-joint (HENLE).

ligament, is divided. After drawing upwards the peroneal tendons, the interosseous calcaneo-astragaloid ligament is cut across, and the dorsal and plantar calcaneo-cuboid ligaments are detached from the external and plantar aspects of the os calcis. The point of the heel is now well drawn over to the inner side so as to expose the tendon of the tibialis posticus, which is then displaced upwards over the sustentaculum tali. Lastly, the os calcis is seized with a strong pair of forceps, and the internal lateral ligament of the ankle-joint, the subjacent calcaneo-astragaloid capsule,

and (anteriorly) the ligaments connecting the tibia with the scaphoid and os calcis are detached.

189. Resection of the Calcaneo-Astragaloid Joint, and Resection of the Posterior Tarsus (Fig. 116). Resection of the joint between the astragalus and os calcis is performed by ANNANDALE by two lateral curved incisions. It can also be done by the method above described for excising the os calcis, or by a modified method of that for resection of the posterior tarsus now about to be described.

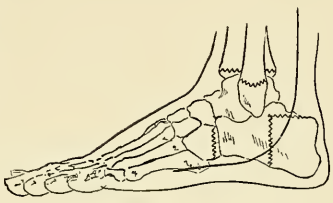

FIG. 116.—Resection of the posterior tarsus.

Resection of the posterior tarsus, that is to say, the simultaneous removal of the astragalus and os calcis, and sometimes also of the adjacent articular surfaces, gives good results with the foot maintained in its normal position, because the leg passes down into the defect (KOCHER, KUMMER).

In the method about to be described, it is a necessary condition that there should be a possibility of preserving the tendons and muscles (peronei, tibialis anticus and posticus) which move the foot.

The incision, beginning upon the outer aspect of the tendo Achillis a hand-breadth above the ankle-joint, is continued downwards behind the external malleolus and the peroneal tendons, and thence forwards to the tuberosity at the base of the 5th metatarsal bone. After opening the sheaths of the peroneal tendons and displacing the latter forwards, as has been described in excising the astragalus and os calcis, these two bones are removed, and the articular surfaces of the bones of the leg and of the cuboid and scaphoid are sawn off. It is desirable to retain some of the external malleolus, so that the peroneal tendons may hook round behind it. If the posterior part of the os calcis can be retained, it may be utilised osteoplastically in the same way as in PIROGOFF'S amputation of the foot, as indicated by the serrated lines (Fig. 116).

190. Resection of the Ankle-Joint (Figs. 117 and 118). Resections of this joint do not always give satisfactory results, on account of the complexity of the joint, and of the presence of disease in the adjacent astragalo-tarsal joints, together with their bones, especially the os calcis. Hence the constant endeavours to improve the technique of the operation. The incisions have been made upon all aspects of the joint, and in every direction.

VOGT makes an antero-lateral longitudinal incision; KÖNIG and RIEDEL, bilateral incisions with chiselling off of the malleoli; MEINHARDT SCHMIDT, the same together with a posterior incision; HÜTER, an anterior transverse incision, which had been previously employed by SABATIER,

Heyfelder, and Hancock; Liebrecht, a posterior transverse incision; Wackley, the same combined with a posterior longitudinal incision; Textor, Busch, Hahn, Ssabanejew, an inferior stirrup-shaped incision with separation of the tuberoses of the os calcis; Moreau, Langenbeck, Ollier, Chauvel, Girard, lateral incisions sometimes along with transverse incisions.

We recommend a *transversely curved external incision* (Reverdin and Kocher). Lauenstein has added some improvements to this method. According to Catterina, Albanese had already employed the luxation method with an external incision. The incision (Fig. 117) begins opposite the line of the ankle, just at the outer border of the extensor tendons, that is to say, over the muscular fibres of the peroneus tertius, and is carried in a curved direction below and beyond the tip of the

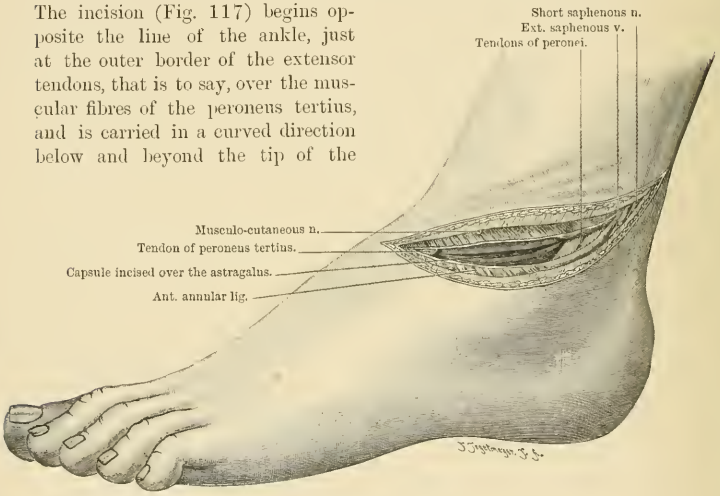

Fig. 117.—External transverse (curved) incision for arthrotomy and resection of the ankle-joint.

external malleolus, and from thence upwards along the tendo Achillis, but without injuring it. The skin and fascia are divided, the musculo-cutaneous nerve being avoided anteriorly and drawn inwards along with the extensor tendons. The short saphenous vein and nerve which lie behind the peroneal tendons are left undisturbed at the posterior extremity of the wound. The incision is extended down between the extensors and the fibula to the outer surface of the astragalus, and divides the capsule as far as the external malleolus, from the edge and inner surface of which the three strong bands of the external lateral ligament of the ankle-joint are separated. The sheaths of the peronei are now slit upwards behind the fibula, and the tendons

are drawn backwards. The deep layer of the tendon sheaths and the periosteum are now divided along the fibula, and the periosteum is separated forwards from the outer surface of the fibula as far as the tibia, and by drawing the extensor tendons well upwards also from the anterior surface of the tibia. For this purpose a sharp periosteum detacher (raspatorium) is employed, so as to detach the most superficial layers of the bone along with the periosteum and the attachment of the anterior part of the capsule. The posterior ligament and the periosteum are raised in the same way from the posterior surface of the tibia as far as the internal malleolus. If there is any difficulty in drawing aside the peroneal tendons, they should be divided and subsequently sutured.

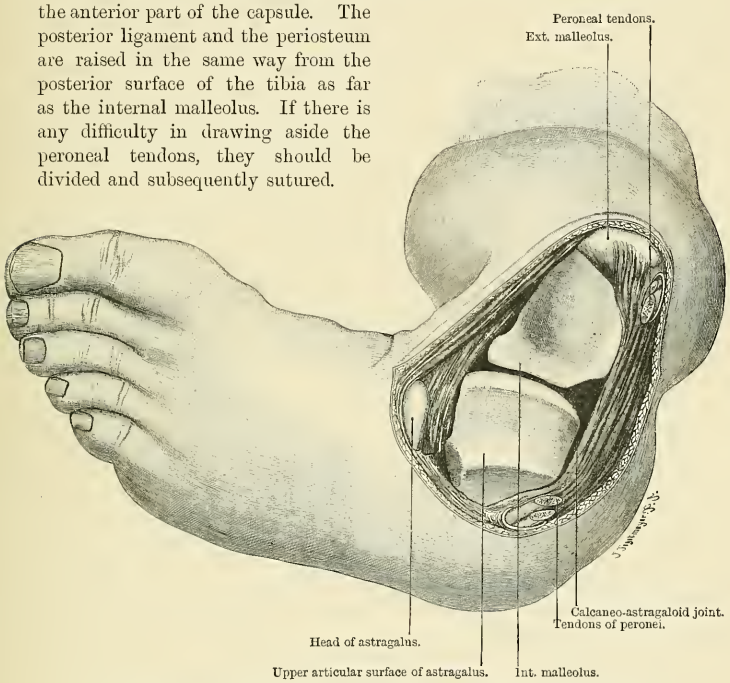

FIG. 118.—Resection of the ankle-joint by the transversely-curved external incision. Second step: dislocation of the foot inwards. Peroneal tendons cut across.

After the foot has been freed from its ligamentous connections with the fibula, and from the outer anterior and posterior aspects of the tibia, the next step consists in twisting the foot forcibly inwards over the internal malleolus, and dislocating it so completely that the sole looks upwards towards the inner surface of the leg, and the inner surface of the foot touches the inner border of the tibia in the manner illustrated in Fig. 118.

In this way a complete view into the joint is obtained. The strong internal lateral ligament at the apex of the internal malleolus is if possible preserved, and is only to be divided if the disease demands it. In this case the separation must be made close to the bone, and preferably by taking away a piece from the surface of the bone, because the flexor tendons descend close behind the malleolus. It is now an easy matter to clear out the joint and resect the astragalus. If the astragalus is to be retained, the calcaneo-astragaloid joint must not be opened unnecessarily; this is avoided by preserving the attachments of the capsule to the posterior and lateral aspects of the astragalus.

The method above described preserves intact the ligamentous apparatus upon the inner aspect of the joint, as well as the support of the external malleolus upon the outer aspect, and thus provides as far as possible against lateral displacements of the foot.

191. Total Resection of the Tarsus (Figs. 119 and 120). WLADIMIROFF and MIKULICZ have added to our means of preserving the foot when extensively diseased, by a method of operation which they have employed for disease of the posterior tarsus. We regard their method as superfluous for disease of the posterior tarsus when the soft parts of the sole and heel can be retained. The method, however, is especially valuable in disease affecting all the bones and joints of the tarsus. It affords the possibility of obtaining a useful foot. After excising the entire tarsus, the sawn bases of the metatarsal bones are applied to the sawn surfaces of the bones of the leg, the foot being brought into a vertical position continuous with the axis of the leg. The patient walks upon the anterior surfaces of the heads of the metatarsal bones, the toes being forcibly dorsiflexed. If the scaphoid and cuboid, or the latter and the three cuneiforms, can be sawn through, a broader and firmer surface is obtained.

The same principle is applied here as in PIROGOFF'S amputation, in which the posterior part of the foot is rotated 90° so as to elongate the leg.

As, however, MIKULICZ'S method presupposes a defect of the skin of the heel, which is an exceptional condition, and in the presence of which the management of the incisions is self-evident, we prefer to describe the method of operation in a typical case, namely, when the disease affects the entire tarsus and leaves an available skin covering.

The incision is just the same as that for resection of the posterior tarsus, namely, a postero-lateral curved incision (Fig. 119), beginning a hand-breadth above the ankle-joint, and extending downwards behind the external malleolus and peroneal tendons, and then forwards to the 5th metatarsal bone. As in the method already described, the bones and joints between the leg and the metatarsus are laid bare by separating the tendo Achillis and periosteum from the os calcis, and by freeing the peroneal tendons from their sheaths and drawing them forwards. The

insertions of all the long tendons of the foot (peroneus tertius, brevis, and longus) are detached from the upper, outer, and under surfaces of the tarsus respectively, as also are the insertions of the tibialis anticus and posticus from their upper, inner, and under surfaces. In doing this, the blood-vessels and nerves are to be preserved.

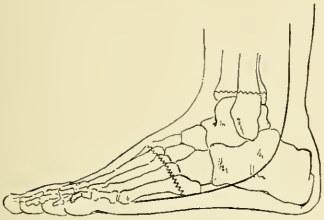

FIG. 119.—Resection of the entire tarsus (WLADIMIROFF, MIKULICZ).

FIG. 121.—Resection of the lower third of the leg.

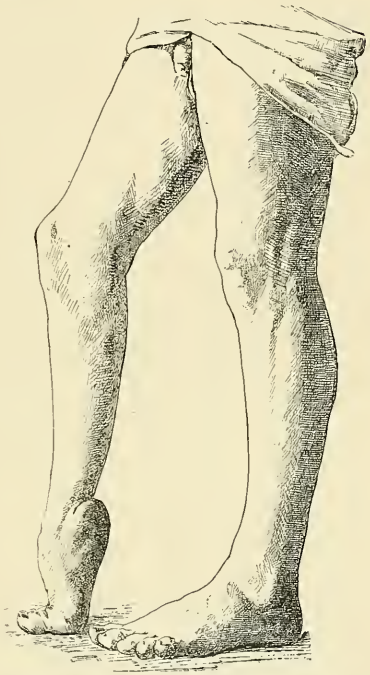

FIG. 120 shows the result after complete resection of the tarsus (from a photograph of a case operated on by the author).

192. Resection of the Lower Third of the Leg (Fig. 121). In the case of extensive disease of the lower third of the bones of the leg, it is to be tested, if it is admissible, by means of a very long postero-external incision to expose and remove a slice of bone from the posterior surface of the os calcis, and to apply its raw surface to the sawn surface of the tibial diaphysis.

193. Resection of the Tibia. In a case in which the middle third

of the diaphysis of the tibia had to be resected on account of necrosis, we removed the diaphysis of the fibula from the other leg and inserted it into the hollowed-out remains of the tibia.

194. Resection of the Fibula. The diaphysis, and indeed the entire fibula, may be removed by an incision behind the whole length of the peroneal muscles, without interfering with the supporting power and activity of the limb, or with the movements of the foot in all directions. The external popliteal nerve is to be avoided as it winds round the neck of the fibula, and the peroneal artery is to be borne in mind as it runs down behind the lower half of the fibula.

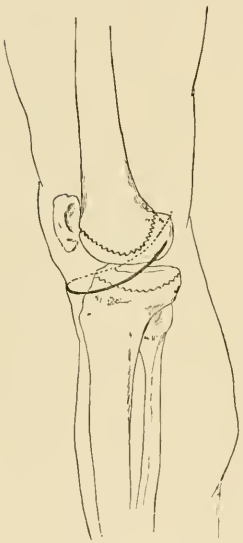

FIG. 122.—Resection of the knee.

195. Arthrotomy and Resection of the Knee (Figs. 122, 123, and 124). We have tested the many methods which have been proposed for freely opening the knee-joint. None of them, however, gives sufficiently free access in so simple a manner as the transverse curved incision with its convexity below; it must, however, be carried as far backwards as to include at least two-thirds of the circumference of the knee. It is not quite clear which surgeon has the merit of introducing it, as PARK appears to have first made the suggestion, and TEXTOR is mentioned as the father of the method. ERICHSEN, however, has contributed to popularise the method. After division of the skin by means of a transverse incision, the further steps in the operation are carried out in very different ways, and these latter are the main considerations as regards the result.

The method to be employed in arthrotomy and arthrectomy differs from that employed in resection, because in the former one aims at a movable joint, while in the latter the object (contrary to all other joints) is to obtain anchylosis in the extended position.

Resection of the knee. If it be decided in the case of an affection of the knee-joint to perform complete resection, the skin and the strong fascia lata are divided by a transverse curved incision (Fig. 122) and dissected upwards to above the patella. The tendinous attachment of the quadriceps is divided in a curved direction around the patella. The fibrous capsule of the joint is divided from the upper edge of the patella obliquely downwards to the epicondyles (attachment of the lateral ligaments) so as to expose the synovial membrane along the entire upper

edge of the wound. The outer surface of the synovial membrane is now followed upwards, outwards, and backwards as far as its reflection on to the femur, and, along with the visceral serous layer, is dissected off the bone as far as the edge of the femoral cartilage along the whole of its anterior extent. The fibrous capsule is dissected downwards in a similar manner until the attachment of the synovial membrane to the tibia is completely exposed from without. The ligamentum patellæ and the lower and upper attachments of the lateral ligaments are cut through. The capsule is then detached along the edge of the tibia up to the cartilaginous surfaces, thus detaching also the semilunar cartilages. In this way the whole of the anterior and lateral aspects of the capsule, together with the overlying patella and the ligamentum patellæ, are dissected out like a tumour in one continuous mass without it being necessary to cut into diseased tissue.

With most surgeons it is the rule to carry the transverse incision at once into the joint by cutting through the ligamentum patellæ. That this is not an advantage in infective, and especially in tubercular deposits, is evident; moreover, by this procedure the patella and the quadriceps retract upwards, so that the excision of the synovial pouch under the quadriceps is—what is not the case with our method—rendered difficult.

Not only do we always remove the patella, but after cutting through the crucial ligaments we excise also the semilunar cartilages and the ligaments. The subcapsulo-periosteal method of OLLIER has no justification in the eyes of all those surgeons who regard it as desirable to produce anchylosis of the knee-joint. The patella and ligamentum patellæ, as well as the other ligaments, play a comparatively unimportant part in giving rigidity to the joint, and everything depends upon the production of firm union of the bones in obtaining a thoroughly useful extremity. If this does not take place, the result is imperfect in spite of the patella and ligaments. This is evident also from the fact that in the event of anchylosis occurring, young individuals in whom a single arthrectomy has been performed, and in whom the whole extensor apparatus has been preserved, are just as likely to have the knee markedly flexed as those in whom the whole joint along with the patella has been removed. Neither do we employ VOLKMANN'S method of dividing the patella transversely, and the less so because we agree with BÖCKEL that the patella itself is too often diseased.

Contrary to OLLIER, therefore, we altogether avoid the subperiosteal operation, and make as simple a wound as possible, in order to bring nothing but skin and fascia over the cleanly exposed and divided bones, because, as already mentioned, we have learnt to rely entirely upon osseous anchylosis. We are quite aware that the action of the quadriceps is retained; but with the knee anchylosed the vasti are not required, and the rectus femoris changes its action, and acts merely upon the thigh as a flexor at the hip-joint.

After excising the whole of the anterior and lateral walls of the joint, plenty of space is got, so that by fully flexing the joint its posterior wall is easily extirpated. For this purpose the crucial ligaments must be detached from the intercondyloid fossa close to the bone. The posterior surface of the femoral condyles and of the tibia can now be got at, and the macroscopically diseased tissue can be removed with precision along with the bursæ in the popliteal space, especially that connected with the popliteus muscle. The clean wound-surface which is now left is to be thoroughly disinfected before the bones are sawn, and in tuberculosis iodoform is to be rubbed in to prevent the further development of any remaining infective material.

In order to further firm anchylosis by accurate apposition of the bones, the way in which the ends of the bones are sawn off is a most important matter. In order to avoid forward displacement of the femur upon the tibia, the saw has been directed at all kinds of angles, and every variety of means of fixing the sawn surfaces has been employed. Nails and sutures have been used to fix the bones. As, however, these often tear out and do not fulfil their object, ALBERT in Vienna and others have bevelled the surfaces during the sawing. We have got by far the best results by sawing the femur so as to leave a convex surface, and the tibia so as to produce a corresponding concave surface. This method has been recommended by METZGER, and by FENWICK, first in 1871 and later in another publication, where he reports 28 cases in which the functional results were very good. If the operator thoroughly understands how to estimate the direction of the saw, the bony surfaces may be brought into such accurate contact and so firmly pressed together that all further artificial means of fixation is quite superfluous, provided, of course, that the limb is firmly fixed to a splint in the fully-extended position. Sawing the femur in a curved direction has the further advantage of more certainly avoiding the epiphyseal line, a matter of great importance as regards the future growth of the femur. After adapting the two sawn surfaces to one another, all that is required is to introduce a suture which penetrates deeply through the skin and fascia, drainage-tubes being introduced through special openings. By this plan we have of late years obtained complete union by first intention in numerous cases, just as in simple wounds of the soft parts, so that after eight to fourteen days a permanent water-glass bandage is applied as if it were a subcutaneous fracture. The patient is able to stand on the leg six weeks after the operation. In those cases in which, on account of suppuration or other local infection, open-wound treatment must be employed, the ends of the bones cannot be fixed together by making curved sawn surfaces. In such cases it is well to retain the extensor apparatus.

Arthrotomy and arthrectomy of the knee. As resection of the knee-joint differs from the type described for resections in general, we must make special mention of that method which is to be used when one has

not fully made up one's mind to bring about anchylosis. The intention may be either simply to open the joint (arthrotomy), to excise the capsule and interarticular cartilages (arthrectomy), or lastly to resect portions of the bones. In all cases where there is still a possibility of retaining a movable joint, we have come to the conclusion after various experiments that any solution of continuity to the extensor apparatus of the knee is a mistake. No matter how accurately the ligamentum patellæ, the patella, or the tendon of the quadriceps is sutured, or how uninterrupted is the healing of the wound, it is never afterwards possible to attain such rapid and vigorous contraction of the quadriceps as when that muscle with its tendinous apparatus is preserved completely intact up to the tubercle of the tibia. This can be done even in extensive disease without adding materially to the difficulty of the operation, and without leaving any doubt as to whether the whole of the diseased soft parts of the joint have been removed. We perform the operation as follows.

An anterior transverse curved incision is made, just as for resection, extending from the posterior part of the outer aspect of one condyle across the line of the joint to the other condyle. The skin and fascia are divided, and dissected up in the form of a flap from off the ligamentum patellæ and the patella as in resection. The fascia is fairly strong upon the inner side, thin over the ligamentum patellæ and the patella, and very strong upon the outer side. The capsule is now exposed laterally as far as the vastus internus and externus, the ligamentum patellæ and the patella being exposed in the middle line. The capsule is divided in an upward direction on both sides close to the edge of the patella, and the tendinous attachments of the vasti are divided in the same direction at a little distance from the patella and the tendon of the rectus. The line of reflection of the capsule at the outer surfaces of the femoral condyles is followed round, and the parietal layer is separated downwards from the periosteum as far as the external and internal epicondyles. The epicondyles along with the upper attachment of the lateral ligaments are detached with the chisel in a backward direction, so that the latter can be drawn backwards whilst still retaining their continuity with the periosteum of the femur.

If the capsule has been divided at both sides of the ligamentum patellæ down to the tubercle of the tibia, the patella may be readily dislocated, first externally and then internally, so that by fully flexing the joint, its cavity is so completely opened up that the greater part of it can be inspected. The crucial ligaments are only to be separated from the femoral condyles when absolutely necessary, and, as in resection, this should be done by removing at the same time a thin plate of bone from the outer and inner walls of the intercondyloid fossa in such a way as to maintain the continuity of the crucial ligaments with the periosteum at the posterior surface of the femur. All the recesses of the joint can now be inspected. If necessary, the whole synovial membrane may be extirpated,

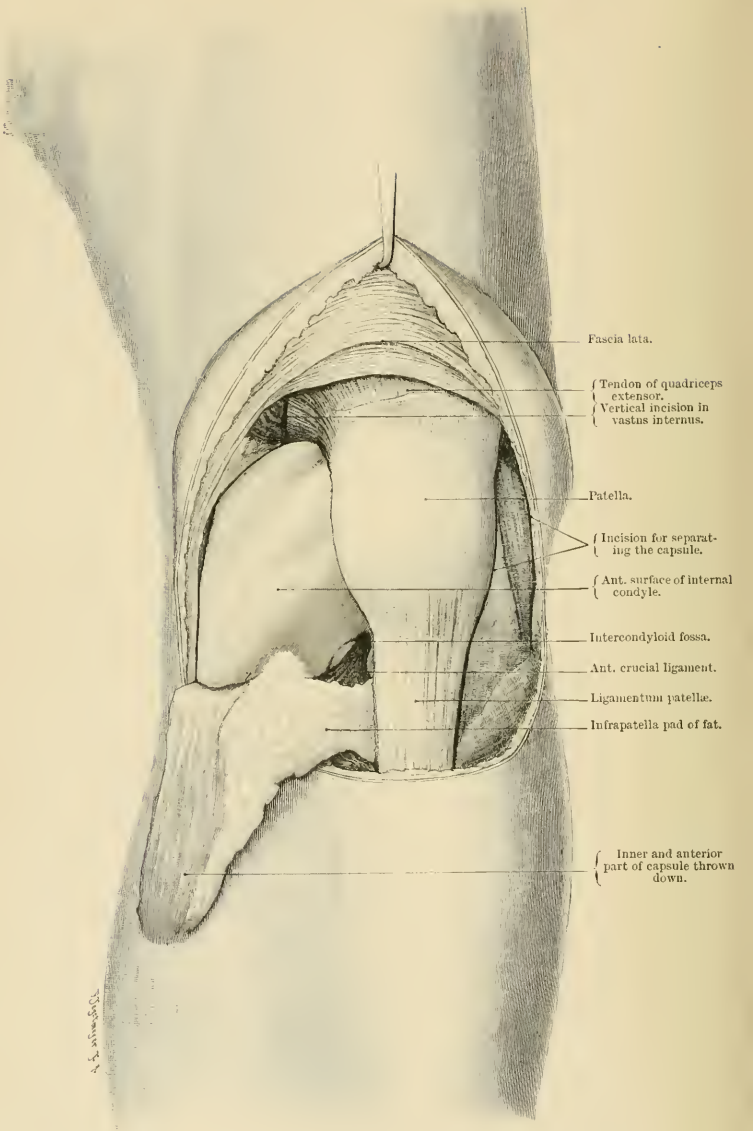

FIG. 123.—Arthrotomy of the knee by a convex incision through the skin; separation of the upper attachment of the capsule, the inner portion of which has been thrown down.

or circumscribed areas removed. Lastly, the surfaces of the patella are reversed so that its articular surface may, when necessary, be freed from adherent fungous (tubercular) granulations, or osseous foci thoroughly cleared out. At the same time the posterior surface of the quadriceps tendon is made clean and smooth by the removal of any remains of the

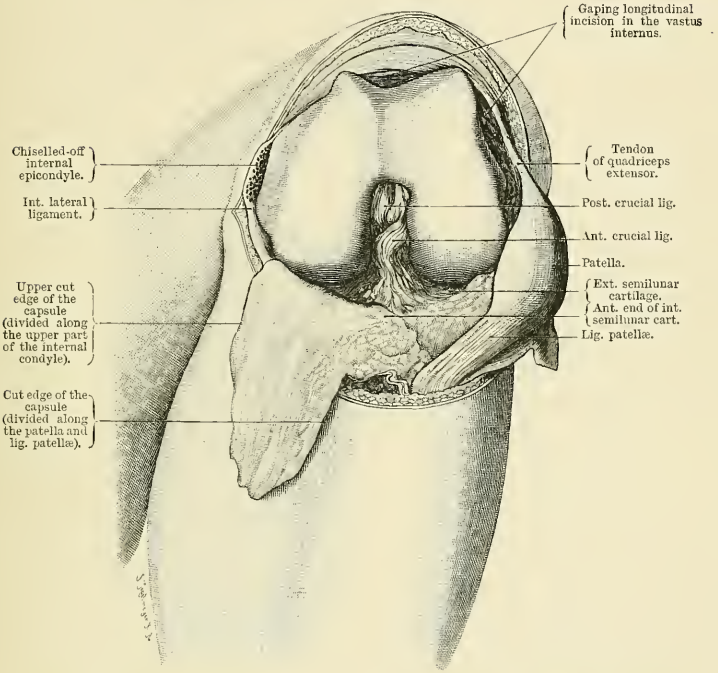

FIG. 124.—Arthrotomy of the knee by the anterior curved incision. Capsule thrown down; patella dislocated to outer side.

diseased synovial pouch which lies under it. The popliteal and semimembranosus bursæ may also be cleared out, should they be diseased. The cartilages are shaved off wherever they are in any way discoloured, or excavated by the invasion of subjacent granulations. This is especially necessary in order that osseous foci may not be overlooked, and to allow them to be thoroughly cleared out.

When the capsule is preserved, it is to be carefully sutured, after

which the fascio-cutaneous flap is brought into position with a few deep sutures, and then, after providing for drainage, the continuous cutaneous suture is applied. To secure permanent healing in tubercular cases, iodoform is rubbed into all the recesses and folds. When sinuses and open wounds exist, the cavities are stuffed with iodoform gauze, the skin being retained in position by introducing temporary sutures, which are removed after one to ten days, and the definite suture introduced (secondary suture) according to the plan recommended by us, and more recently somewhat modified by BERGMANN, SPRENGEL, HELFERICH, and others.

Atypical resections in connection with the knee-joint—for example, resection of one or other condyle or tuberosity—are only justifiable when one is certain of bringing about anchylosis of the other tuberosity or condyle with the opposing bone.

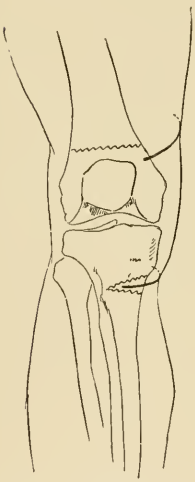

FIG. 125.—Osteotomy of the femur. Cuneiform osteotomy of the tibia.

196. Resection of the Patella. This is an important operation in primary disease of the patella in order to prevent diffuse disease of the joint. The individual steps of this very simple operation are—longitudinal incision; division of the fascia and of the smooth walled bursa which is generally found underneath it; stripping off of the quadriceps fascia and of the periosteum; and, lastly, separation from the anterior wall of the capsule. After removing the patella the cut edges of the capsule can be united in the longitudinal direction without difficulty, the joint being closed and the extensor apparatus re-established. The results are very satisfactory, as a completely movable joint can be obtained (Dr. KUMMER).

197. Osteotomy and Cuneiform Resection of the Tibia (Fig. 125). The skin and periosteum are divided two finger-breadths below the level of the joint in the line of cleavage of the skin, *i.e.* transversely from the tubercle of the tibia to the edge of the calf muscles. After separating the periosteum the chisel is applied in the direction of the skin incision. The attachment of the ligamentum patellæ must not be injured, because the bursa between it and the tibia may communicate with the joint. In an aggravated case of genu valgum it is better to remove a wedge from the tibia having its base directed inwards, otherwise, with the leg in the straight position, there is too great a strain on the head of the fibula, and paralysis of the external popliteal nerve which winds round it may be the result.

198. Supra-Condyloid Osteotomy of the Femur (Fig. 125). The incision, whether on the outer or inner side, is along the line of

cleavage of the skin, and passes obliquely from above downwards and forwards through the skin and the fascia lata, which is especially strong on the outer side. The vastus (internus or externus) is exposed at its posterior border and drawn upwards; the periosteum is split vertically above the epicondyle and separated forwards and backwards, and the bone divided with a chisel for two-thirds of its breadth, the remainder being broken across.

The superior internal (or external) articular artery is to be looked out for, and internally especially the deep branch to the anastomotic artery. Along with MACEWEN (to whom belongs the credit of developing this operation) we were the first to perform osteotomy of the femur for genu valgum.

FIG. 126.—Subtrochanteric osteotomy.

FIG. 127.

199. Osteotomy and Sub-Trochanteric Cuneiform Resection of the Femur (Figs. 126 and 127). A transverse incision is carried down to the bone through the skin, the tendon of the gluteus maximus, and the vastus externus, on the outer side of the limb at the level of the base of the great trochanter and below the trochanter minor. The transverse terminal branch of the external circumflex artery runs parallel to the incision. The bone is chiselled through obliquely downwards, forwards, and inwards, so as to prevent the lower fragment from being displaced inwards or forwards when the limb is forcibly abducted.

The operation is especially for the purpose of correcting adduction, flexion, and shortening, the result of old hip-joint disease and of old-standing and congenital dislocations of the hip.

The limb is put up in the abducted position with the pelvis rotated upwards on the same side. The parts are retained in position by a plaster of Paris bandage applied to the pelvis and both extremities.

200. Resection of the Diaphyses of the Femur. The outer side of the shaft of the femur may be cut down upon in its entire length, from the base of the great trochanter where the transverse terminal branch of the external circumflex artery passes under the vastus externus, to the external condyle where the superior external articular artery winds transversely around the bone. The incision extends between the posterior border of the vastus externus and the biceps, no structures of any importance being injured.

201. Resection of the Hip-Joint (Figs. 128, 129, and 130). We have tried the anterior resection, which has been warmly recommended, especially by LÜCKE, but we regard it as indicated only for partial resection, *i.e.* for the removal of the anterior part of the capsule and of the head of the bone. The posterior incision gives far more room in cases where the joint is to be freely exposed, especially if the following method be employed.

The incision is an angular one, extending from the base of the outer surface of the great trochanter upwards to its anterior superior angle, and from thence obliquely upwards and inwards in the direction of the fibres of the gluteus maximus. The skin and fatty tissue are divided. At the base of the trochanter branches of the external circumflex artery are divided and ligatured. The dense aponeurotic insertion of the gluteus maximus is now divided upon the outer aspect of the trochanter, exposing the periosteum and the insertion of the gluteus medius, which covers the whole of its upper border.

The upper and back part of the incision divides the fibres of the gluteus maximus, and generally some vessels of considerable size, which must be ligatured.

A fatty layer now appears, and after dividing it, the interval is reached between the lower border of the gluteus medius and minimus above, and the pyriformis below. By drawing the pyriformis downwards and working to the bottom of the space, the posterior surface of the capsule and the back part of the acetabulum are reached. The capsule is now divided along the upper border of the pyriformis, and after flexing the thigh and rotating it outwards, the whole breadth of the tendon of insertion of the gluteus medius is separated from behind forwards from the great trochanter along with the periosteum covering its outer surface, including also the insertion of the gluteus minimus at its anterior border.

Instead of dissecting off the tendinous insertions, they may be raised up along with the periosteum and a superficial layer of the bone and turned upwards and forwards. After separating the attachments of the glutei, the insertions of the external rotators come into view, and are

detached from the inner surface of the trochanter and from the digital fossa—first the pyriformis, then the obturator internus with the gemelli,

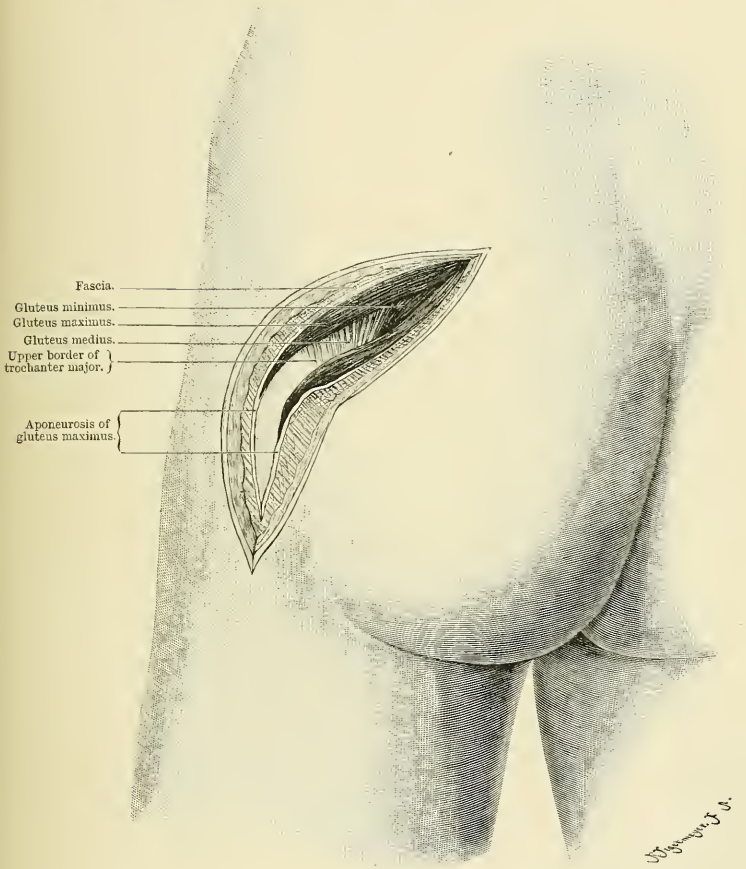

FIG. 128.—Resection of the hip by posterior angular incision. The skin, fascia, and aponeurosis of the gluteus maximus have been divided. The lower border of the gluteus medius and the outer surface of the great trochanter are exposed.

and lastly the obturator externus. The thigh being rotated inwards, these muscles are detached backwards along with the periosteum from the

inner and posterior aspects of the trochanter. In this way the muscles supplied by the superior gluteal nerve, namely, the gluteus medius and

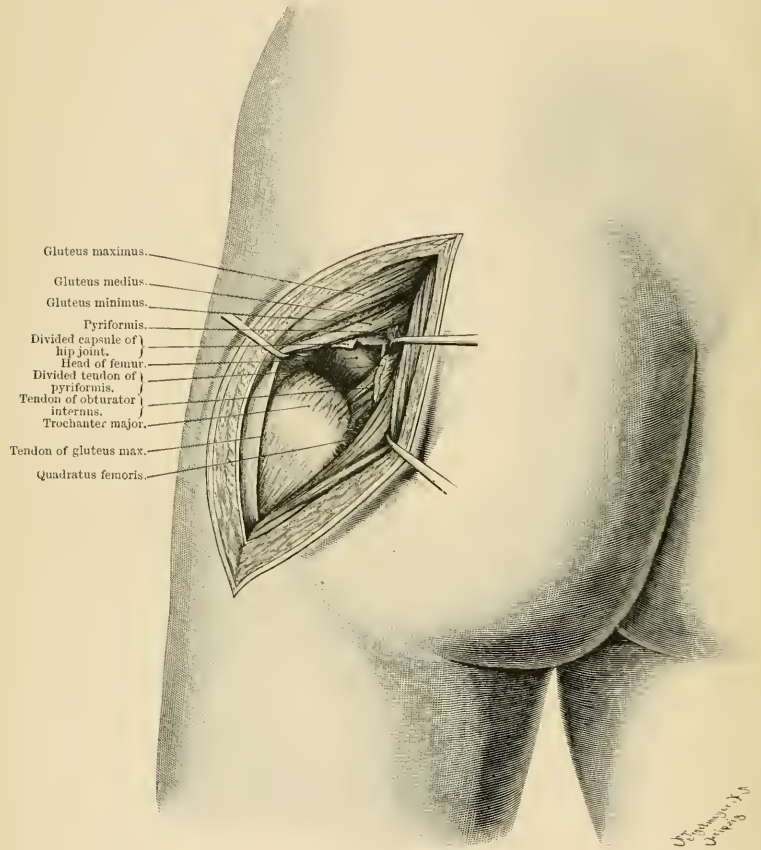

FIG. 129.—Resection of the hip. Second stage: gluteus medius and minimus separated close to the bone and drawn forwards; tendon of pyriformis detached from the trochanter and drawn backwards; capsule of the joint divided.

minimus, are drawn forwards and upwards towards the tensor fasciæ femoris muscle, which has the same nerve supply, and which along with the glutei is of special importance for the future abduction of the thigh;

while the remaining muscles, the gluteus maximus, the pyriformis, and the obturators, which are mainly supplied by the inferior gluteal nerve, are drawn downwards. The pyriformis now and then receives a branch also from the superior gluteal nerve, which, however, is given off so high up that there is no fear of injuring it.

By this means the posterior surface of the head and neck of the femur,

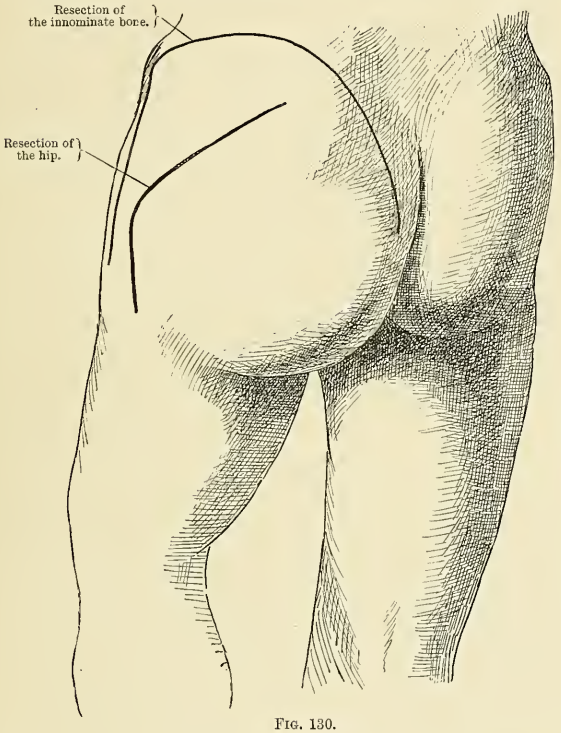

FIG. 130.

and as much as is necessary of the trochanter, are exposed. One or two branches of the internal circumflex artery which run transversely over the capsule at the neck of the femur require to be ligatured. It may be necessary also to ligature the transverse branch of the external circumflex artery where it winds round the base of the trochanter under the vastus externus. When the synovial membrane is tubercular and has to be excised, it is easy before opening the capsule to dissect down accurately

upon a large area of it from behind, and to separate it from its attachment to the acetabulum and neck of the femur, and so remove the posterior wall of the capsule *in toto*. The ligamentum teres is divided by cutting on the head of the bone from behind and below, the limb being powerfully adducted, flexed, and rotated inwards; the head is then dislocated backwards, and the acetabulum rendered visible. The tubercular tissue is now removed with scissors and forceps until one is satisfied that the whole joint has been cleared out.

Of the numerous methods employed for resecting the hip we know of none which allows of such free inspection of the joint with so little injury to the muscles, nerves, and bone. It is a further development of LANGENBECK'S method by the oblique incision, which, however, does not admit of extirpation of the capsule alone with at the same time preservation of the bone. We shall therefore dispense with a comparison of this with other methods of operation. If merely an arthrotomy is to be performed, then the attachments of the muscles to the trochanter are not separated, but the capsule is at once opened along the upper border of the pyriformis from the acetabulum to the neck of the femur. The capsule, along with the periosteum and muscular attachments, is then detached from the neck and trochanter.

202. Resection of one half of the Pelvis (Fig. 130) has been performed by KOCHER and ROUX with very satisfactory functional results. The patient of the former's, in whom the head of the femur was at the same time excised, can walk without a stick, although distinctly lame.

V. UPPER EXTREMITY

203. Excision of the Phalanges, Metacarpal Bones, Inter-Phalangeal and Metacarpo-Phalangeal Joints (Figs. 131 and 132). For the phalanges and their joints, lateral incisions are made; for the metacarpal bones, dorsal incisions. The incisions upon the fingers are placed near the dorsum, and this is to be the more particularly attended to the further they extend towards the tips. In the case of the fingers it is desirable in removing a bone to make bilateral incisions, in order to prevent unilateral contraction of the scar and consequent lateral bending of the finger. The extensor tendons and nerves on the dorsum are to be avoided, the incisions being made over the bones where they can be felt beneath the skin.

When not contra-indicated the subperiosteo-capsular resection is to be performed. The head of the bone is first exposed because it can be more easily rendered movable.

In the case of the metacarpal bone of the thumb, the extensor primi internodii pollicis along with the periosteum is detached to one side, and the muscles of the ball of the thumb to the other, the tendon of the

extensor ossis metacarpi pollicis being separated from the base of the bone. In the case of the remaining metacarpal bones, the interosseous muscles are separated along with the periosteum. The carpo-metacarpal joint of the thumb is the only one with a separate synovial membrane; the others are continuous with the intercarpal joints.

FIG. 131.—Resection of the phalanges and 1st metacarpal bone.

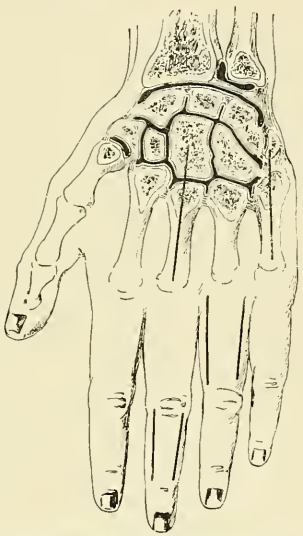

FIG. 132.—Resection of the phalanges and metacarpal bones. (Coronal section of the wrist, after HENLE.)

204. Resection of the Wrist (Figs. 133 and 134). For freely opening the wrist-joint, we have as a rule employed the method most usually adopted, viz. that known as LANGENBECK'S. FARABŒUF states that the dorso-radial incision was employed by BÖCKEL in 1869. We employed the same incision before LANGENBECK, not only on the living, but also demonstrated it in the operative course upon the cadaver. It is through LANGENBECK, however, that the method has become widely known. It has great advantages over the methods formerly employed.

Dorso-Radial Incision. With the hand forcibly flexed to the ulnar side, a straight incision is carried through the skin from the middle of the 2nd metacarpal bone over the middle of the wrist-joint, and upwards along the axis of the forearm for a corresponding distance above the joint. The incision strikes the interval between the tendons of the extensor communis digitorum and extensor indicis on the one side, and

the extensor secundi internodii pollicis on the other. The skin is divided gradually so as to avoid the branches of the radial nerve going to the

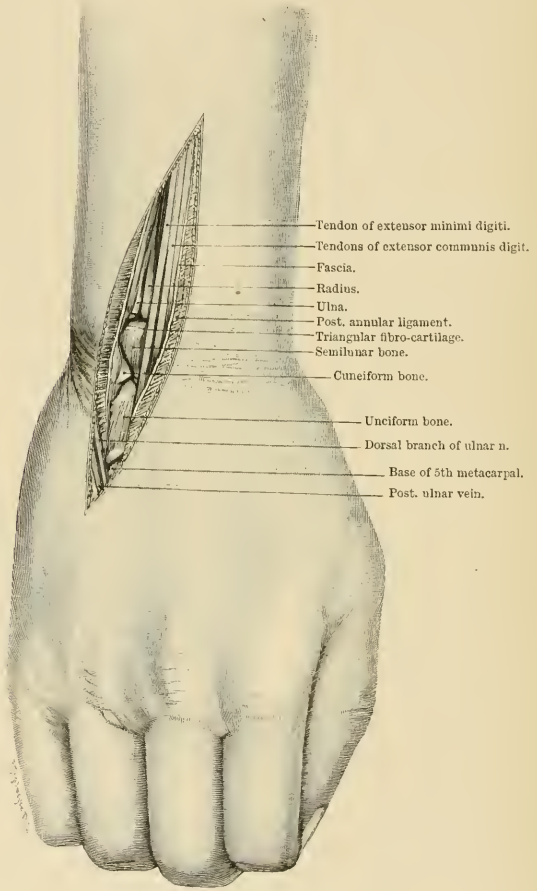

FIG. 133.—Resection of the wrist by the dorso-ulnar incision carried through the capsule.

middle finger. The upper part of the incision passes through the posterior annular ligament and the fascia, down to the radius. Opposite

the wrist-joint it is carried through the capsule and downwards upon the base of the 3rd metacarpal bone. The tendons of the extensor carpi radialis brevior and longior are now detached along with the periosteum

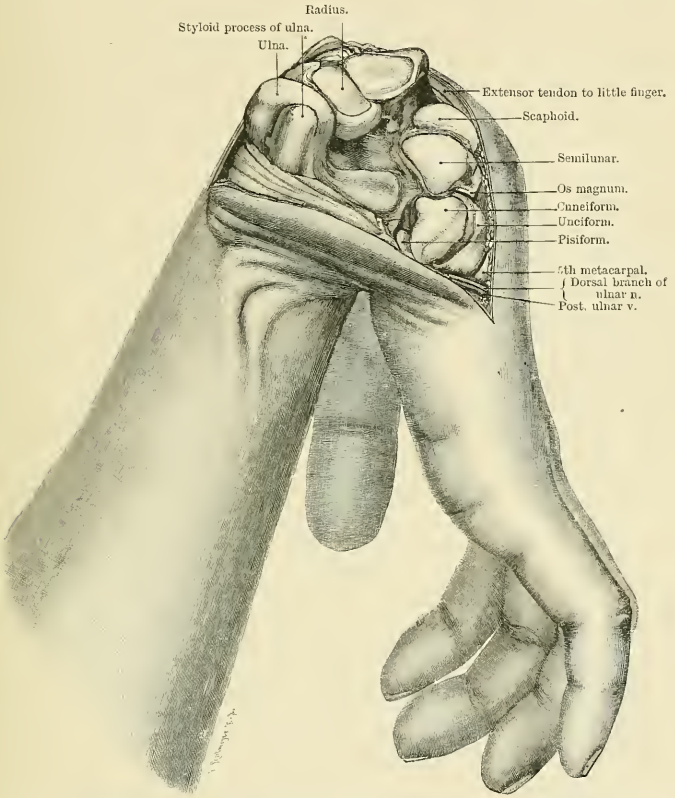

FIG. 134.—Resection of the wrist by the dorso-ulnar incision. Second stage: the wrist-joint is dislocated and the posterior ligament detached from the bones of the forearm.

from the bases of the 3rd and 2nd metacarpals respectively, and the posterior surface of these bones with the intervening interosseous muscle exposed. The tendons are now displaced laterally from their grooves in the bones, and the detachment of the capsule of the wrist-joint is commenced.

The disadvantage of the BÖCKEL-LANGENBECK method is, that in order to get sufficient room, it is necessary to detach the radial extensors. Even although the subperiosteal method is strictly adhered to (as recommended by TRÉLAT), considerable damage is nevertheless sustained by the chief dorsal flexors of the hand, which is apt to be flexed towards the palm and the power of dorsiflexion seriously impaired. It is therefore preferable, on account of the frequency with which the radial extensors are injured, to place the incision upon their ulnar side.

Dorso-ulnar incision (Figs. 133 and 134). The incision proposed by LISTER, and which is referred to as dorso-ulnar, lies much more towards the ulnar aspect, between the flexor and extensor carpi ulnaris tendons.

Our incision must be of considerable length, 7 to 8 cm. (3 to $3\frac{1}{2}$ in.), and so placed that with the hand slightly flexed to the radial side, it extends from the middle of the 5th metacarpal bone upwards over the middle of the wrist-joint, and from thence along the middle of the back of the forearm. At its lower end the incision avoids the origin of the posterior ulnar vein (*vena salvatella*) and the dorsal branch of the ulnar nerve, which is not so likely to be injured as is the radial nerve by the dorso-radial incision, because the dorsal branch of the ulnar winds towards the back of the hand at a lower level. After dividing the fascia along with the strong transversely striated posterior annular ligament, the incision opens the sheaths of the extensor minimi digiti and extensor communis tendons which are drawn to the radial side: beneath the tendons the ligaments upon the base of the 5th metacarpal, the unciform, the cuneiform, and the ulna, are divided. The capsule is now separated towards the ulnar side, and along with it the tendon of the extensor carpi ulnaris, which is attached to the 5th metacarpal.

The detachment of the tendon of the extensor carpi ulnaris has not the same disadvantage as has that of the two radial extensors. The ulnar extensor has much less share in dorsiflexing the hand than the radial extensors which lie upon the radio-carpal articulation, which forms the main part of the wrist-joint. The extensor carpi ulnaris assists mainly in producing ulnar flexion, which is the very movement which occurs to too great an extent after resection, in consequence of the weight of the hand, which is subsequently often displaced to the palmar and ulnar aspects, that is to say, appears to be contracted in this direction. The division of this tendon, therefore, may act rather beneficially than otherwise. Moreover, in the dorso-ulnar incision the extensor tendons have less tendency to protrude from the wound than in the dorso-radial incision. The special extensor of the little finger is the one most interfered with, but as this finger is provided with a double extensor, and has a far less important function than the index, this disadvantage may be disregarded.

Above, the tendon of the extensor carpi ulnaris is lifted out of its groove in the ulna, and the capsule is separated from around the bone.

When the inferior radio-ulnar joint is diseased, the miniscus must be excised. The separation of the attachment of the capsule around the ulna is easy. After dividing the capsule at the cuneiform, the joint between it and the pisiform is opened, the tendon of the flexor carpi ulnaris being left in connection with the latter. The hook of the unciform can be more easily exposed and cut across than by the dorso-radial incision. This is a matter of importance, because the deep branch of the ulnar nerve winds round it and must be preserved. The bundle of common flexor tendons can be lifted *en masse* out of their groove without difficulty, and the ligamentous connections between the three inner metacarpals can be separated upon the palmar aspect, the insertion of the flexor carpi radialis into the 2nd metacarpal being preserved. The attachment of the anterior ligament of the wrist-joint is separated from the anterior border of the lower end of the radius.

Upon the dorsal aspect, the posterior ligament is detached from the lower end of the radius as far as the radial extensors and the extensors of the thumb, and the tendons are raised from out of their grooves. The tendons, however, of the radial extensors are not detached from their insertions into the dorsal aspect of the 3rd and 2nd metacarpal bones respectively.

The hand is now forcibly and completely dislocated towards the radial and flexor aspects so that the thumb comes in contact with the radial border of the forearm, and the extensor tendons come to lie upon the radial side of the radius. When necessary the capsule may be still more thoroughly detached from the outer border of the radius, and the insertion of the supinator longus exposed. There is now no difficulty in dissecting out the carpal bones, and in removing as thin a layer as possible from the bones of the forearm and from the metacarpals. It is only in the region of the trapezium, the trapezoid, and the bases of the three radial metacarpals that access is not so readily obtained.

In cases where the disease chiefly involves or is limited to the radial aspect of the carpus and metacarpus, the dorso-radial incision possesses advantages over our own method. Especial care must be taken to avoid the radial artery which lies on the dorsum between the trapezium and trapezoid bones, and enters the palm between the bases of the 1st and 2nd metacarpals to form the deep palmar arch.

We especially claim for our method that the tendons of the radial extensors are preserved intact, and that by completely dislocating the joint it is possible to obtain a view of all its recesses, and of each individual bone.

In the after-treatment, it is of importance to secure dorsiflexion of the hand by means of a splint, such as we have been in the habit of using for years, and which, although keeping the wrist securely fixed, still allows of movement of the fingers. As the finer and more important movements of the fingers are associated with flexion, the wrist should be

dorsiflexed, so that by stretching the flexors the fingers are kept in a state of passive flexion, which can be rendered more complete and active by comparatively little muscular effort.

205. Resection of the Ulna. The ulna lies subcutaneously along the whole length of the forearm, in the interval between the flexor and extensor carpi ulnaris muscles. It can therefore be excised either partially or completely without any difficulty and without injury to the surrounding structures.

206. Resection of the Radius. The radius is much less easily accessible than the ulna. The head of the radius can always be felt under the skin at the outer part of the posterior surface of the elbow, and can therefore be resected by a part of the incision, the direction and position of which is fully described in our method of resection of the elbow (p. 261).

The middle third of the diaphysis may be felt upon the posterior surface of the limb, between the radial extensors of the wrist and the extensors of the fingers. It may be cut down upon here without fear of vessels, nor do the branches of the nerves come into question, as the adjacent muscles receive their nerve supply higher up. The upper third of the radius is covered by the supinator brevis muscle, through which the posterior interosseous nerve passes backwards. The lower third, besides being covered by the supinator longus and the two radial extensors, which run all the way along it, is also covered by the pronator quadratus, and by the extensors of the thumb which pass obliquely over its postero-external aspect.

An incision extending down to the radius in its whole length is only possible along the line for ligature of the radial artery, by drawing the radial nerve to the outer, and the radial artery to the inner side. In the upper third the nerve lies well to the radial side of the artery; in the lower fourth it winds to the dorsal aspect of the wrist.

Method of freely opening the Elbow-Joint

207. Resection of the Elbow (Figs. 135 and 136). In arthrotomy and resection of the elbow-joint, just as in all other joints in which a free exposure of the cavity is desired in order to remove accurately all diseased tissues, we adhere to the principle of making a somewhat more complicated skin incision, in order not only to preserve all the muscles along with their attachments, but especially also to spare the nerves which supply them. This was the main reason why we employed the posterior curved incision for arthrotomy of the shoulder (see page 266), and why we subsequently also modified the methods which had been employed for resection of the elbow.

To begin with, we employed the simple method of LANGENBECK with a posterior longitudinal incision; but we found, especially in tubercular

disease which was localised in or had extended to the region of the head of the radius, that the access was not so satisfactory. OLLIER's bayonet-shaped incision is an excellent method for gaining this access, but it has the disadvantage of throwing the anconeus out of action. It is true that the oblique middle portion of OLLIER's incision extends through the interval between the outer head of the triceps and the anconeus; but as the branch from the musculo-spiral nerve which supplies the latter muscle descends from the branch supplying the outer head of the triceps, it is necessarily divided, with the result that the anconeus atrophies. As it is our special duty in the case of the elbow to obtain an actively

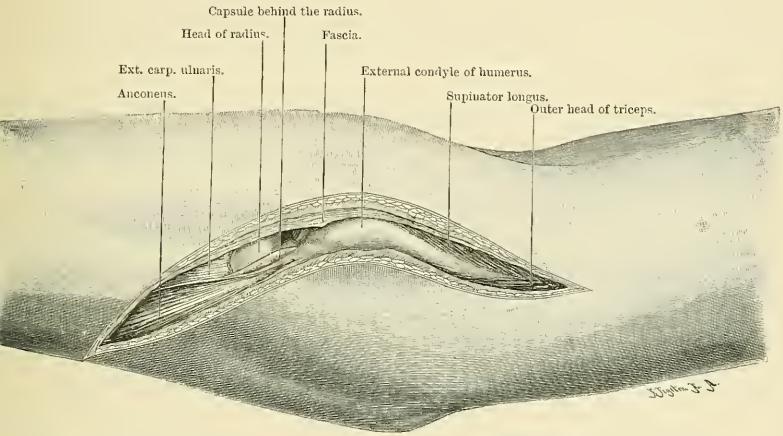

FIG. 135.—Arthrotomy of the elbow by the dorso-radial angular incision, which extends between the supinator longus and outer head of the triceps above, and below along the outer border of the anconeus, between it and the origin of the extensor carpi ulnaris.

movable joint, the function of the anconeus ought to be preserved, as it serves to stretch and fix the capsule of the joint. We attain this by the following method of operation.

With the elbow flexed to an angle of about 150°, an angular incision (Fig. 135) is, like OLLIER's incision, begun at the external supracondyloid ridge 3 to 5 cm. ($1\frac{1}{2}$ to 2 in.) above the line of the joint, and is carried downwards practically parallel to the axis of the humerus, *i.e.* vertically downwards to the head of the radius, and from thence along the outer border of the anconeus to the posterior border of the ulna, 3 inches below the tip of the olecranon; finally, the incision terminates by curving inwards over the inner surface of the ulna (see also Fig. 10, page 27). The first part of the incision extends down to the outer border

and external condyle of the humerus, between the supinator longus and radial extensors anteriorly, and the edge of the triceps posteriorly; below the external condyle it passes down to the bone between the extensor carpi ulnaris and the outer border of the anconeus, and divides the strong capsule over the head of the radius together with the annular ligament at its attachment to the ulna. The lower end of the incision divides the lower fibres of the anconeus transversely at their attachment to the posterior border of the ulna, because the muscle extends for a considerable distance down the forearm. The incision therefore falls accurately along the interval between the muscles supplied by branches of the musculo-spiral nerve and those supplied by the posterior interosseous, thus avoiding the possibility of subsequent muscular atrophy. The bone having been exposed and the capsule divided, the next step will depend upon whether the olecranon is diseased or not. When diseased it is chiselled obliquely through its base without unnecessary separation of muscular and tendinous attachments. The triceps along with the anconeus and the olecranon can now be displaced to the ulnar side in the form of a flap, and the joint freely exposed. The olecranon, according to the extent of the disease, can thus be scraped out and dealt with in a conservative manner. If, however, the olecranon is to be retained, the outer head of the triceps, together with the periosteum and the upper attachment of the capsule, is detached from the humerus, the anconeus from the posterior surface of the ulna, the insertion of the triceps from the tip of the olecranon (or a bit of the olecranon chiselled off along with the tendon), and the triceps-anconeus flap is (the joint being extended) displaced over the olecranon to its inner side (see Fig. 136). The external lateral ligament and the capsule attached to the external condyle and neck of the radius are separated and drawn forwards. The joint has now become so movable that the forearm can be completely dislocated inwards (Fig. 136). The whole extensor apparatus, both as regards muscles and nerves, is preserved in its continuity, and the internal lateral ligament is still intact. If complete resection is to be performed, after dislocating the joint as above described, the internal lateral ligament is separated subperiosteally along with the muscles from the inner border of the ulna and the internal condyle of the humerus, and the ends of the bones are removed. In separating the lateral ligaments it is better to remove a shell of bone along with them, so as to preserve their attachment to the periosteum.

For many years we have been in the habit of making curved sawn surfaces in performing resections; in this particular case in order to ensure an angular movement (flexion and extension) at the new joint. It is especially important to saw the olecranon in a curved direction, in order to preserve a lever into which the triceps is inserted. This goes a long way towards preventing partial dislocation forwards of the forearm.

We have already stated that as compared with the simple posterior

longitudinal incisions, of which LANGENBECK'S is the most generally employed, the curved incisions, especially advocated by OLLIER, have the great advantage of giving more room and better exposure of the joint, especially in the region of the head of the radius. It is not very likely that any one will care to employ transverse incisions (straight or curved), either alone or combined with one or two longitudinal incisions. The main direction of the incision must always be longitudinal if the muscles and their nerves are to be preserved. The only method which we need refer to is that of AUGUSTE NÉLATON, which is mentioned by FARABŒUF. It has nearly the same direction as our incision,

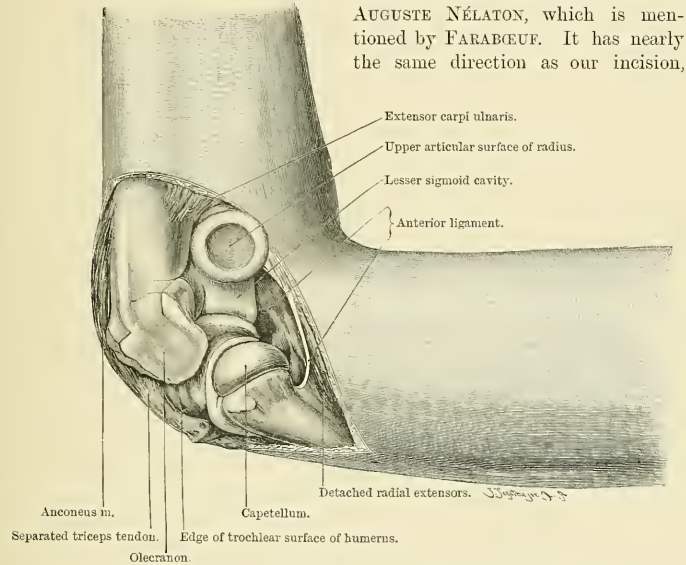

FIG. 136.—Arthrotomy and resection of the elbow by the external curved (angular) incision. Second stage: the forearm is dislocated inwards, and the triceps and anconeus are displaced to the inner side of the olecranon.

being carried longitudinally over the external condyle of the humerus and then bending at a right angle from the head of the radius towards the ulna. NÉLATON'S object in employing this incision is to thoroughly expose the head of the radius, but like OLLIER he pays little attention to the preservation of the anconeus. HUETER, and, according to FARABŒUF, MARANGOS have also recommended skin incisions which are allied to ours, but planned with a different object.

For cases in which the disease is confined to the olecranon the simple posterior longitudinal incision of LANGENBECK has the advantage

that it is carried directly down upon the seat of disease. In all cases, on the other hand, where a thorough view into the joint is desired, our method above described has great advantages.

208. Resection of the Diaphysis of the Humerus. For purposes of excision, the relations of the humerus are not so simple as those of the femur. The removal of the upper and lower ends of the bone is considered with excision of the respective joints. The most important relation to be borne in mind is the musculo-spiral nerve, which winds round the posterior and outer aspects of the shaft.

The external bicipital sulcus is the only line along which the entire length of the diaphysis may be exposed. The circumflex vessels and nerve are to be avoided at the surgical neck. The fascia of the deltoid is divided in order that (the arm being abducted) its anterior border may be drawn outwards; next the fascia covering the biceps is divided and the bone reached along the outer borders of the coraco-brachialis and brachialis anticus muscles. The musculo-spiral nerve and the accompanying superior profunda artery lie to the outer side, whilst, in the lower third, the musculo-cutaneous nerve, which descends between the biceps and brachialis anticus, is drawn inwards.

209. Resection of the Shoulder-Joint. *a. From the front*—when the disease involves the head of the bone (Figs. 137 and 138).

The head of the humerus overlaps the glenoid cavity to a considerable extent anteriorly. The diameter of the latter in the horizontal direction is only half that of the cartilaginous portion of the head: so that to expose the head from the front is easy, while exposure of the glenoid is difficult. The simplest method is by the anterior longitudinal incision employed by BAUDENS, MALGAIGNE, ROEKET, DUBREUIL, and developed especially by LANGENBECK and his pupils. The improvement by HUETER, OLLIER, and CHAVEL, which consists in making an oblique incision to preserve the deltoid (instead of the vertical incision downwards through it from the acromion), appears to be the most rational procedure, because this muscle plays the chief part in the subsequent movements of the arm.

The incision begins upon the clavicle above the coracoid process, and passes downwards along the anterior border of the deltoid. The edge of this muscle, which lies close to the clavicular portion of the pectoralis major, is recognised by its relation to the cephalic vein, which is drawn inwards along with the pectoral muscle, the deltoid being drawn outwards. The upper and anterior fibres of the latter muscle are divided close to the clavicle, as shown in Fig. 137; and a branch of the acromio-thoracic artery which lies under it is ligatured.

The muscles attached to the coracoid process, viz. the pectoralis minor, the short head of the biceps, and the coraco-brachialis, now appear, in front of which, at the lower part of the wound, the upper edge of the smooth tendon of the pectoralis major is seen passing to its insertion into

the humerus. The arm being slightly rotated inwards, the sheath of the biceps tendon is opened by cutting down to the bone at the outer border of the above muscles, where the bicipital groove may be distinctly felt. The sheath is now slit up along with the capsule as far as the edge of the glenoid, and the tendon which is thus freed is drawn inwards. The biceps tendon is exposed, not only that it may be preserved, but in order that the upper end of the bone may be rendered accessible along the line of the bicipital groove which corresponds to the boundary between the attachments of the anterior and posterior muscles. The tendons which are inserted into the upper end of the humerus and the capsule, viz. the subscapularis into the lesser tuberosity, the supra-

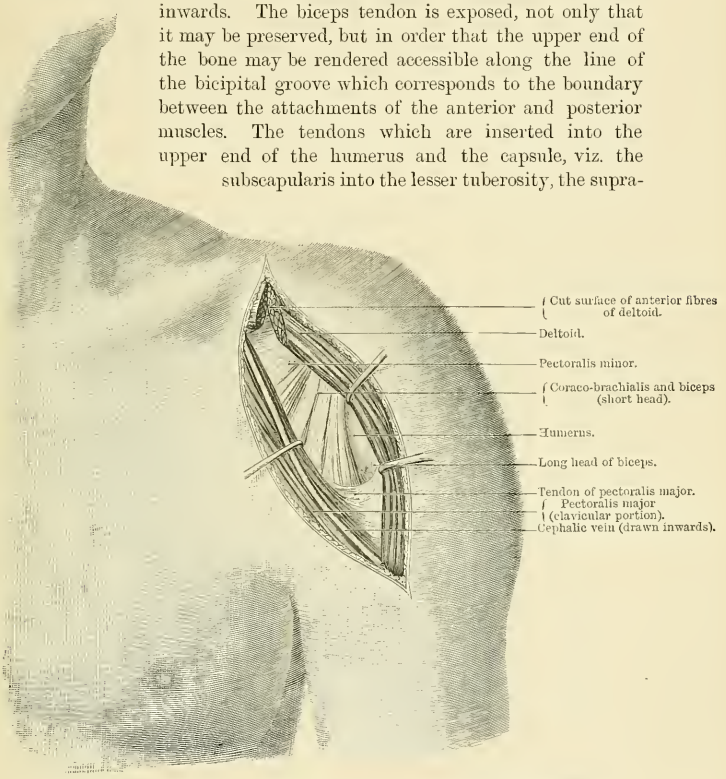

FIG. 137.—Resection of the head of the humerus by the anterior oblique incision.

spinatus, infraspinatus, and the teres minor into the great tuberosity, are now separated close to the bone by means of vertical cuts made parallel to the bicipital groove. In doing this the humerus is rotated first outwards and then inwards. *No* transverse incision is to be made in the capsule. In cases in which the humerus must be exposed farther downwards,

the anterior and posterior circumflex arteries and the circumflex nerve which surround the surgical neck must be borne in mind, and the former if necessary ligatured.

b. Resection from behind (Figs. 139 and 140) is employed when the disease involves more especially the glenoid cavity, or in diffuse disease of the joint.

The skin incision, as shown in Fig. 139, is carried from the acromio-clavicular joint over the top of the shoulder and along the upper border of the acromion to the outer part of the

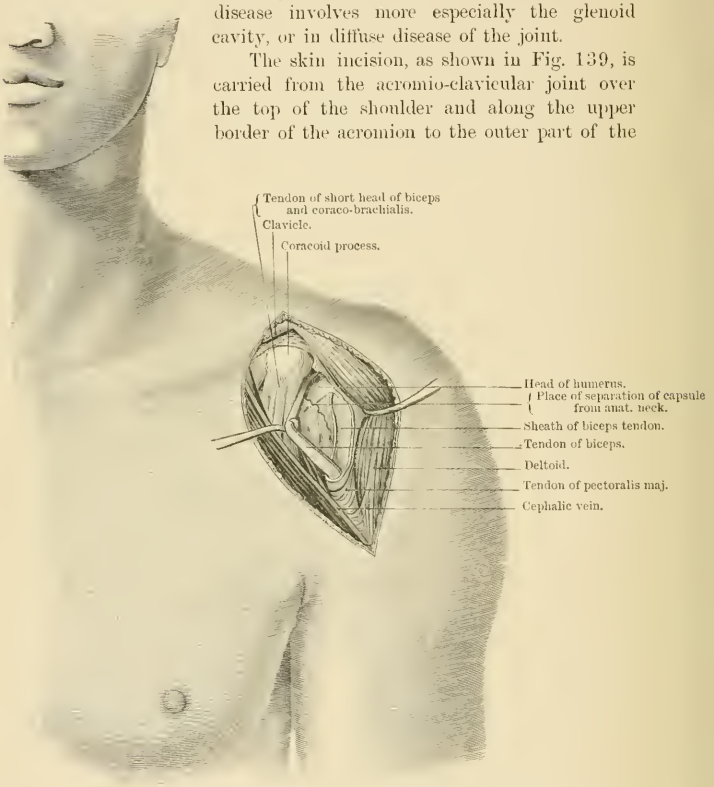

FIG. 138.—Resection of the head of the humerus by the anterior incision. Second stage: the biceps tendon is lifted out of its sheath, and the joint is opened.

spine of the scapula (root of the acromion), and from thence downwards in a curved direction towards the posterior fold of the axilla, ending two finger-breadths above it. The upper limb of the incision passes through the superior ligament right into the acromio-clavicular joint, and in the rest of its course down to the upper border of the acromion. The

descending limb of the incision divides the dense fascia at the posterior border of the deltoid, and exposes the fibres of the latter. The thumb is now introduced beneath the smooth under surface of the deltoid so as to separate it from the deeper muscles (with which it is connected merely by loose cellular tissue) up to its origin from the acromion, and its posterior fibres are divided as shown in Fig. 139. The finger is now carried along the upper border of the infraspinatus muscle so as to free it opposite the outer border of the spine and the root of the acromion. The insertion of the trapezius muscle is in like manner separated for a short

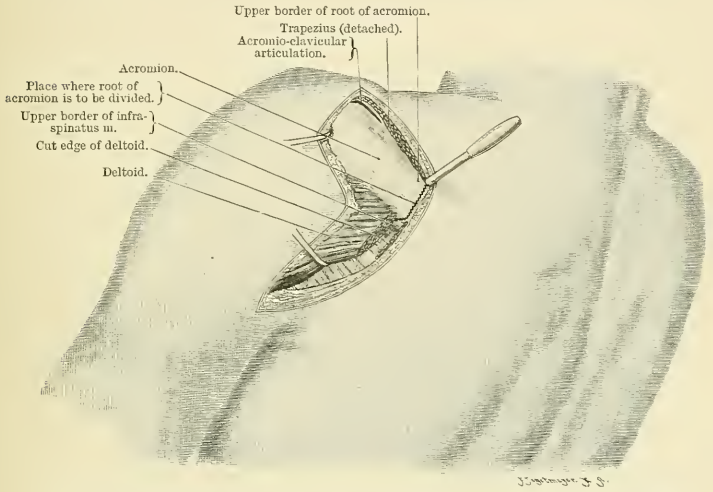

FIG. 139.—Arthrotomy and resection of the shoulder-joint by the posterior curved incision. First stage: acromio-clavicular joint opened; trapezius detached; posterior border of deltoid divided; root of acromion chiselled across.

distance from the upper border of the acromion where it springs from the spine, and the supraspinatus muscle is pushed backwards so that the finger can be passed from above also under the root of the acromion. The root of the acromion which is now freed is chiselled through obliquely.

In chiselling through the bone, care must be taken not to injure the suprascapular nerve which passes under the muscles from the supraspinous into the infraspinous fossa; the nerve is also protected by the transverse ligament of the scapula. It is desirable before chiselling the bone to bore the holes required for the subsequent suture. After dividing the bone the acromion is forcibly displaced forwards by means of a sharp hook, and dislocated at the acromio-clavicular joint. In doing so the

deltoid is at the same time raised from the posterior surface of the infraspinatus and teres minor muscles, to which it is only connected by loose cellular tissue (Fig. 140).

After reflecting the acromio-deltoid flap, the head of the bone is readily accessible in its upper, outer, and posterior aspects, covered by the tendons of the external rotators, viz. the supraspinatus, infraspinatus, and teres minor muscles. The posterior surfaces of these muscles are also exposed. An incision is now made over the head of the bone, and in

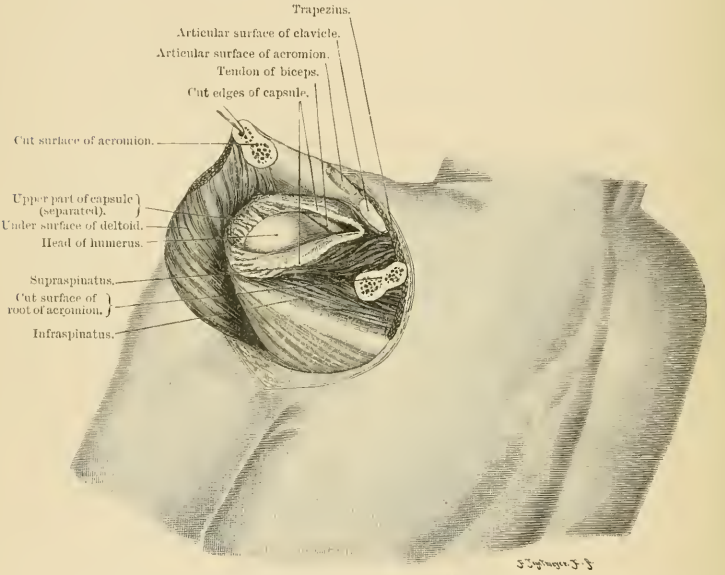

FIG. 140. – Arthrotomy and resection of the shoulder. Second stage: the root of the acromion is divided, and the process along with the posterior part of the deltoid being turned forwards, the capsule is opened posteriorly.

order to avoid unnecessary injury this must be done accurately. The arm being rotated outwards, a longitudinal incision is carried down to the bone in the coronal plane; commencing at the upper part of the posterior lip of the bicipital groove, it extends upwards through the capsule along the anterior edge of the insertions of the external rotator muscles and over the highest part of the head of the humerus, so as to expose the tendon of the biceps as far as its attachment to the upper edge of the glenoid cavity. The insertions of the external rotators are

now separated from the greater tuberosity and drawn backwards. The biceps tendon is freed from its groove and drawn forwards, so that its sheath may be inspected. The whole procedure is made easier by carrying the elbow forwards and at the same rotating the arm outwards. The insertion of the subscapularis is now exposed and separated forwards and inwards. The circumflex vessels and nerve which come out from under the teres minor can be preserved; indeed, if the operation be properly performed there need be no fear of injuring them (Fig. 140).

When the head has been thoroughly cleared, and especially if it be resected, an excellent view of the glenoid is obtained, much better than is possible by the anterior incision; and as it is most important to remove all the infected tissues in tubercular disease, this complete exposure of all parts of the joint is the great advantage of the method. Moreover, this free exposure is obtained without interfering with the function of the deltoid or other muscles of the shoulder. Yet another advantage over the anterior method is, that when the disease in the head is limited or absent, only the posterior muscles require to be separated, while the anterior part of the capsule, the coraco-humeral band, and the subscapularis muscle are preserved intact, and in this way there is no tendency of the head of the bone to be displaced upwards towards the coracoid, which so frequently occurs as the result of the anterior operation. The method is therefore especially valuable in partial arthrectomies.

210. Resection of the Clavicle, of the Acromio-Clavicular, and of the Sterno-Clavicular Articulations. As the clavicle is subcutaneous throughout its whole length, its resection is a simple matter, provided it can be done subperiosteally. After dividing the skin, platysma, clavicular branches of the descending superficial cervical nerve, and fascia, the periosteum is divided and reflected. The clavicle should be sawn through in the middle, as it is then easier to clear each half separately. The clavicular attachments of the sterno-mastoid and trapezius muscles are detached from the upper surface, and the clavicular portions of the pectoralis major and deltoid from its anterior surface, whilst from its under surface the subclavius muscle and the costo-clavicular ligament are to be separated.

In resecting the *acromio-clavicular joint* the outer end of the clavicle is freed merely by cutting through the strong ligaments upon the surface of the joint.

There is no difficulty in resecting the *sterno-clavicular joint* by an anterior incision, because the meniscus facilitates the separation of the articular ends. When, however, the excision cannot be done subcapsulo-periosteally, the transverse vein at the suprasternal notch must be kept in mind in dividing the interclavicular ligament, while in dividing the clavicular portion of the sterno-mastoid the anterior jugular vein, which runs outwards behind it to open into the external jugular, is to be looked

out for. In extensive division of the subclavius muscle and the costo-clavicular ligament the close proximity of the pleura and of the subclavian vein must not be forgotten.

211. Resection of the Scapula (Fig. 141). *Complete* resection of the scapula was first performed by Langenbeck (Gies) in 1855. A. Ceci has shown what excellent functional results can be obtained after its complete removal. In tumours of the scapula it is essential that the operation be thorough without at the same time inflicting unnecessary injury on the surrounding parts. When the periosteum can be retained, an endeavour must be made to preserve it together with the overlying muscles, with the object of obtaining as much regeneration as possible. In tumours, on the other hand, where preserving the periosteum is out of the question, it is better, with the object of preventing recurrence, to remove the muscles as well, because in the absence of the scapula they are no longer of any use. The muscles to which we refer are those which act upon the scapula alone, or which pass from it to the arm.

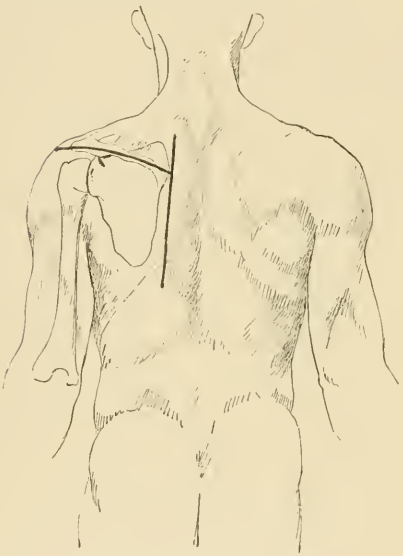

Fig. 141.—Resection of the scapula.

A curved incision is made along the acromion and spine of the scapula as far as its vertebral border. A second incision is carried along the vertebral border of the bone from its superior to its inferior angle. As far as the function of the arm is concerned, it is a great advantage if a considerable portion of the acromion can be retained, because the trapezius and deltoid muscles are attached, the former to its inner and the latter to its outer border. If the whole acromion is to be removed, the incision extends at once into the acromio-clavicular joint. If a portion of the acromion is to be preserved, it is divided with the chisel at the place selected.

The lower triangular flap is thrown back over the posterior fibres of the deltoid anteriorly, and the ascending portion of the trapezius

posteriorly, as far as the upper edge of the latissimus dorsi. The finger is introduced under the exposed posterior border of the deltoid, and the muscle is divided (if the disease admits) close to the spine and acromion as far as the acromio-clavicular joint, or to the place where the acromion has been chiselled through.

In this way the posterior surface of the shoulder-joint, together with the tendons of the external rotators, is exposed in the same way as in our method of resecting the shoulder-joint by the posterior incision. If the articular portion of the scapula can be retained, muscle after muscle is cut across upon an elevator, or upon the finger introduced beneath them. If, however, the articular portion of the scapula must be removed, the tendons are detached from the head of the humerus just as in resection of the shoulder-joint, viz. the supraspinatus, infraspinatus, and teres minor from the greater tuberosity, the subscapularis from the lesser tuberosity, and farther down the united insertions of the latissimus dorsi and teres major muscles from the inner bicipital ridge.

The circumflex nerve and the posterior circumflex artery are to be avoided, or the latter may have to be ligatured at the lower border of the teres minor, whilst farther backwards the dorsalis scapulæ artery must be ligatured.

Next follows the division of the trapezius. The finger is introduced under its fibres from the place where the acromion is divided, and the muscle is detached along the acromion and spine. The acromial branches of the acromio-thoracic artery will require to be ligatured in separating the anterior part of the muscle.

By drawing downwards the scapula, which has now become more movable, the muscles attached to its upper border are separated from before backwards, viz. the omo-hyoid (with ligature of the suprascapular artery) and the levator anguli scapulæ at the upper angle, branches of the posterior scapular artery being ligatured.

There still remains the broad insertion of the serratus magnus at the vertebral border, in dividing which the scapula is to be rotated towards the spine. Lastly, the insertions of the thin rhomboid muscles are cut across, the posterior scapular artery, which descends along the vertebral border of the scapula upon the serratus posticus superior muscle, being ligatured if necessary.

PART IV

AMPUTATIONS AND DISARTICULATIONS

INTRODUCTION

A LIMB is to be removed when as the result of injury or disease it is cut off from its blood supply or has become useless, or if it has become a source of danger to life. The complete removal of a limb or of a portion of a limb is spoken of as an *amputation*. When this takes place through a joint the term *disarticulation* is employed. Many of the indications for the selection of special methods of amputation have become invalid since the introduction of the antiseptic treatment of wounds and the improvement of technique which has been associated with it. Formerly, two considerations were regarded as essential in the removal of a limb. (1) The desire to promote rapid and undisturbed healing. (2) That the stump should be as useful and as painless as possible.

To attain the former object the wound was made as small as possible, placed so that its edges were well nourished and would allow of accurate apposition, and lastly, so as to ensure the best possible escape for the discharge.

At present, thanks to asepsis, we can bring about primary healing of the largest wounds, and that in spite of considerable stretching of the edges of the wound, and we can provide sufficiently for the discharges by making special openings for drainage.

The usefulness of the stump also depended formerly much more upon the method than at present, as by the method one had to provide for the mobility of the skin upon the stump, the proper placing of the tendons and muscles at the ends of the bones, and the removal of the cut ends of the nerves from the neighbourhood of the scar.

Nowadays with aseptic wounds these considerations have not the same importance. Amputations may be performed anywhere, as long as a sufficient covering of skin is provided for the stump, and the scar (superficial or deep) is securely placed away from injurious pressure.

At the same time the following conditions must be complied with.

1. To place the skin incision so that the edges of the wound come together without any drag or tension, so that the scar shall not be pressed upon, and so that the skin shall be movable over the stump.

2. To cover the bone with periosteum (or with joint capsule or fascia, as the case may be) and with functionally active muscles and tendons, which will enable an artificial limb to be adapted to the stump. The periosteo-plastic method was introduced by WALTHER in 1813 (SCHEDE). OLLIER, who is a zealous advocate of subperiosteal amputation and especially of subperiosteal disarticulation, refers to the possibility of regeneration of the bone. JAMES SHUTER observed a new formation of bone after disarticulation at the hip.

3. The removal from the stump of all parts sensitive to pressure, especially the ends of the divided nerve-trunks.

Evolution of the Methods of Amputation

In order to show the connection between the different methods of amputation we give in Figs. 144 to 148 a general view of the evolution of the more complicated incisions from the simple circular methods.

The simplest and oldest methods, viz. by the *circular incisions*, have recently again become the most frequent.

By the circular incision we mean, however, in contrast to other authors, not only those which run at right angles to the axis of the limb, but also those which run obliquely to it, provided that the line of incision continues in one direction, that is to say, lies in one plane. In the following illustrations we give a representation of the fundamental type of the transverse and oblique circular incisions—stated shortly, *transverse incisions* and *oblique incisions*—from which all other methods of amputation may be derived, in the first place by the addition of longitudinal incisions, and afterwards by rounding off the angles which are thus produced. If a longitudinal incision be added to a circular one, a *racket incision* results, and by rounding off the corners, the so-called *oval incision*, better termed the *lanceolate incision* (as an oval with a pointed segment is not really oval). If two longitudinal incisions are added, *rectangular flaps* are produced, and by rounding off the corners the *ordinary rounded flaps* result.

The *transverse circular incision*, or shortly the *transverse incision*, is the fundamental type of one method of amputation. It originated as a single incision from CELSUS, as a double incision from CHESELDEN and PETIT (SCHEDE). The sawing of the bone higher up was introduced by LOUIS and BOYER. While it is simple in execution, it has a number of disadvantages which prevent it being universally employed. (1) Seeing that in an amputation one endeavours to preserve as much as possible, the oblique incision is preferable whenever there is more healthy skin on one side than on the other, or when the skin on one

side is more adapted for a covering. (2) The separation of the skin to a sufficient extent is difficult where the limb to be amputated is conical. (3) In the transverse circular incision the cicatrix comes to lie upon the end of the stump, which is not the case with the oblique incision. Figs. 142 and 143 sufficiently illustrate the different positions of the lines of suture.

It is evident therefore that on the above grounds the *oblique circular incision* has a far wider range of employment, because it is applicable to most cases, is easily performed, and gives a movable skin covering free from a cicatrix over the end of the stump. The oblique circular incision is therefore the method to be selected in the majority of amputations and disarticulations when no special indications are to be fulfilled. The simple oblique circular incision does not always give sufficient space for dividing the deeper parts, especially the bones; and it is on account of the mechanical difficulties that more complicated incisions are employed, viz. the addition of *longitudinal incisions* to the circular one. If only



Fig. 142.—Position of the line of suture by the transverse circular incision.

Fig. 143.—Position of the line of suture by the oblique incision.

one longitudinal incision is added, then we have the racket incision with two triangular flaps. If two longitudinal incisions are made, then two rectangular flaps are formed.

The *racket* and *lanceolate incisions* give as much or it may be more room with less sacrifice of skin (and less sacrifice of the soft parts generally), and are therefore to be preferred in difficult disarticulations. They are especially valuable when the indication is to retain as many muscles as possible in the stump, as in disarticulation (and high amputation) at the hip, shoulder, and carpo-metacarpal joint of the thumb. A further advantage of this incision is that the larger vessels can be ligatured and the larger nerves cut across before the limb is severed. The racket is preferable to the lanceolate incision when the longitudinal part of the incision divides the soft parts down to the bone, and when the soft parts are to be separated subperiosteally. In other cases the lanceolate incision is more rapid.

The *flap methods* deserve the preference when the skin or the other soft parts demand special attention upon one or both aspects of the limb. This is the case, for example, as regards the skin of the sole and heel, the muscles of the shoulder and hip. The disadvantage of the flap method,

which applies also in a less degree to its fundamental type, the oblique circular incision, is the defective nutrition of the skin.

METHODS OF AMPUTATION

FIG. 144.

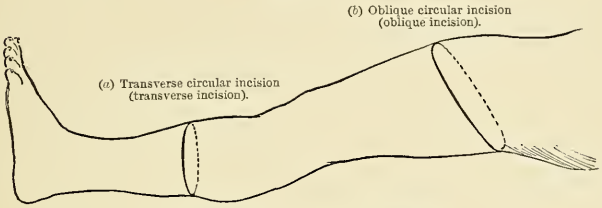

I. Fundamental type: circular incision.

FIG. 145.

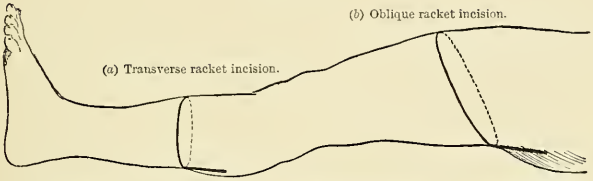

II. Addition of a longitudinal incision, to simplify the operation: racket incision.

Performance of the different Methods

The transverse circular method (Figs. 149, 150, 151). The skin and superficial fascia are divided circularly at right angles to the axis of the limb, first upon the under and then upon the upper segment of the circle. The assistant retracts the skin well upwards with both hands whilst the knife divides the fibres which are stretched between the superficial and deep fascia. The superficial muscles are then divided, and at the level up to which they have retracted the incision is continued through the deeper muscles down to the bone. The periosteum is divided and separated up to the level at which the bone is to be sawn through. The height at which the bone is sawn across above the skin incision is equal to fully half the diameter of the limb. The periosteal tube should always be long enough to completely cover the sawn surface of the bone. When a disarticulation is being performed, the joint capsule, which is practically a continuation of the periosteum, is to be treated in the same way; it is separated upwards from the bone as far as the line of the joint (OLLIER, SOCIN).

By making several circular incisions (the superficial parts being retracted to allow the deeper parts to be divided at a higher level), a funnel-shaped cut surface is obtained, at the bottom of which is the sawn surface of the bone. In this way a broad apposition of all the soft parts is ensured.

FIG. 146.

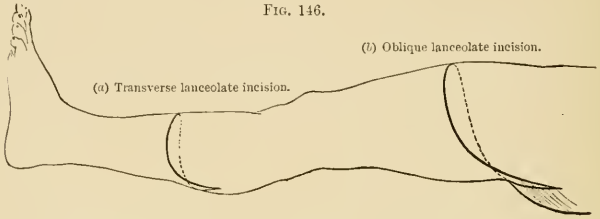

III. Angles of the racket incision rounded off so as to allow of the incision being made more rapidly by one sweep of the knife: lanceolate incision.[1]

FIG. 147.

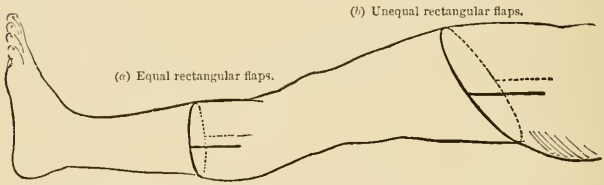

IV. Two longitudinal incisions added to the circular incision: rectangular flaps.

FIG. 148.

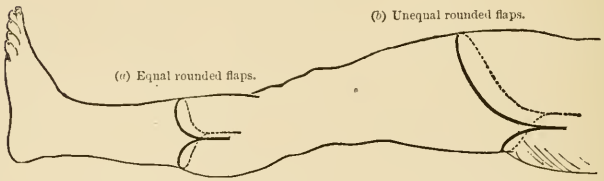

V. Angles of the rectangular flaps rounded off: rounded flaps.

The oblique circular incision (*oblique incision*) (Figs. 152, 153, 154). The upper and lower ends of the incision are indicated by making two short incisions into a fold of skin raised up between the finger and thumb, the distal incision being made at right angles to the surface, the proximal one parallel to the surface (see Figs. 152 and 153). The upper

[1] Formerly termed "oval incision"; a pointed figure, however, is not an oval. The term "oval incision" would apply only to our oblique incision (Fig. 144).

end lies at the level where the periosteum is to be divided; the lower end lies at a distance below it equal to the diameter of the limb. After dividing the skin and fascia, the lower ellipse of skin is seized with the left hand (Fig. 154) and drawn upwards, and the muscles are divided

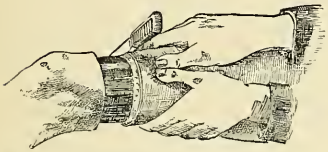

FIG. 149.—Transverse circular incision: method of retracting the skin, and position of the knife.

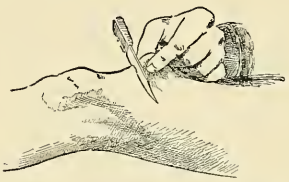

FIG. 152.—Oblique incision: the lower end made by cutting across a fold of skin raised up between the finger and thumb.

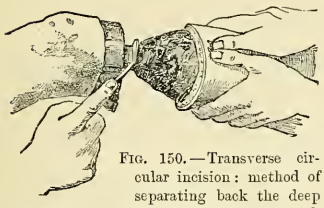

FIG. 150.—Transverse circular incision: method of separating back the deep muscles, together with the periosteum, with the periosteum detacher (raspatorium).

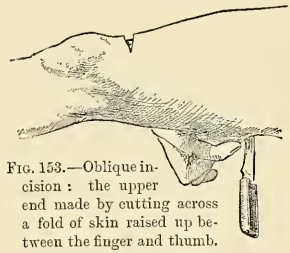

FIG. 153.—Oblique incision: the upper end made by cutting across a fold of skin raised up between the finger and thumb.

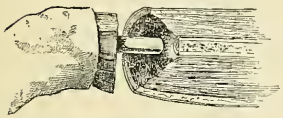

FIG. 151.—Transverse circular incision. Sagittal section, to show the hollow cone which is left after sawing through the bone.

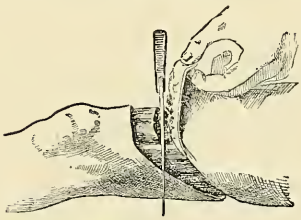

FIG. 154.—Oblique incision: position of the knife in order gradually to carry the incision deeper through the soft parts of the flap.

down to the bone, *the edge of the knife being directed towards the bone* so that a flap is formed which increases in thickness towards its base. The periosteum is divided transversely where the incision reaches the bone, and, as in the transverse circular incision, is separated upwards so that it

may cover the sawn surface. The musculo-cutaneous flap is now folded over the wound.

If for any reason the muscles and tendons cannot be retained, then after making the skin incision the lower end of the skin flap is seized and dissected up from the subjacent tissues to the level at which the periosteum is divided, the edge of the knife being never directed towards the flap but kept vertical to the muscles. After dissecting up the skin, the muscles and bone are dealt with in exactly the same way as in the transverse circular method.

The racket incision and its modification, the lanceolate incision (Figs. 145 and 146). It consists in the addition of a longitudinal incision directed upwards from a transverse (or oblique) circular incision. When possible the longitudinal incision is placed over an intermuscular septum which separates two areas of nerve supply, extends down to the bone avoiding the vessels and nerves, and divides the periosteum, which is then separated. Bleeding vessels are ligatured, and larger vessels are directly sought for in order to diminish the bleeding from the subsequent circular incision. In disarticulations the joint is opened by the longitudinal incision and the capsule separated from the bone. Lastly, the circular incision through the skin is added, the latter retracted, the muscles divided down to the bone, the periosteum separated upwards as far as where the bone is to be divided (in disarticulations as far as the joint), and the sawing across or the disarticulation completed.

Just as the oblique incision is the most important and most universal method of amputation in simple cases, so is the *racket incision* the type of amputation for all cases in which special value is placed upon retaining the muscles in the stump, especially in the shoulder, hip, and thumb. The longitudinal which is added to the circular incision allows the parts to be divided down to the periosteum or capsule of the joint (the muscles and nerves together with the vessels being avoided), and the whole of the soft parts around the end of the bone or around the periosteal tube to be so retained that the stump, although boneless, may still possess a certain degree of mobility. The racket incision also allows the larger vessels to be ligatured, and if necessary divided, before making the circular incision or before removing the limb.

The racket incision is the type of the subperiosteo-subcapsular method of Ollier.

The lanceolate incision, in which the angles of the racket incision are rounded off, is the more convenient and elegant modification of the latter, where rapidity of execution is of more importance than the careful preservation of all the soft parts.

The circular methods with two lateral incisions, or *the double flap methods* (Figs. 147 and 148), are modifications of the simple types for the purpose of simplifying the execution of the operation. They are therefore performed at all situations where the mere circular

method is difficult, especially in amputations through the joints of the foot.

The fundamental type consists of two longitudinal incisions placed opposite one another, and united at their lower ends by a circular incision. If this circular incision lies transversely, two rectangular flaps of equal length result. If it is placed obliquely, the flaps are of unequal length. As a rule, however, the flaps are rounded off as they are cut, so that only a portion of the longitudinal incisions is retained, and instead of a circular incision, we have two curved incisions which join the longitudinal ones at an acute angle. The mistake usually committed by beginners is that the two curved incisions are made to join one another at too wide an angle.

The skin is divided in a curved direction, first on the one and then on the other aspect of the limit. Just as in the simple oblique incision, the lower edge of the flap is raised up and the muscles divided obliquely down to the bone. The periosteum is divided circularly and separated up as far as the place where the bone is to be sawn. Two oblique raw surfaces are thus obtained, which in the case of flaps of equal length are applied to one another. With flaps of unequal length the larger one covers the main part of the wound surface. The relation of the skin incisions to the seat of amputation, that is to say, to the level at which the bone is sawn or to the line of disarticulation, is estimated, in the case of the lanceolate and flap methods, in the same way as for the simple transverse or oblique circular incision.

Mention must be made of that variety of the flap method in which the parts are *transfixed* by a double-edged knife. The limb is transfixed, and the flaps are formed by carrying the knife downwards along the bone, and dividing the muscles and skin in an arched direction towards the surface, first on one aspect and then on the other. This method produces a very clean wound, and is very rapid, but it has lost its importance since the introduction of anæsthetics and of ESMARCH'S prophylactic arrest of hæmorrhage. In all cases where the end of the bone, especially the epiphysis, is to be used for direct support, it must be rounded off, either by sawing it off in a curved direction, or by covering it osteoplastically with a rounded bony process, as is done in PIROGOFF'S and GRITTI'S amputations.

After removing the limb, the vessels are ligatured with fine silk. The nerve trunks are sought for, drawn forwards, and cut across. When the wound surfaces cannot be sutured into complete apposition in their whole extent, a glass drain (with large lateral openings) is introduced as directly as possible into the cavity which is left, through a small special opening (for its direction see Figs. 2 and 3).

Deep interrupted sutures are used to bring the muscles together, and an accurate continuous suture is used for the skin. Still more accurate union is obtained if the individual layers of the soft parts are separately

brought together by means of buried sutures; first the periosteum, then the deep and superficial muscles, the tendons, and lastly the skin.

X. LOWER EXTREMITY

Amputations at the Foot

The main rule to observe in amputations at the foot is to arrange the incisions so that there will be no cicatrix in the sole. The longer flap must always be taken from the plantar aspect. A second rule, except in amputations of individual toes, is that portions of the foot are always to be removed transversely to its long axis (Major).

212. Removal of a Toe with and without its Metatarsal Bone (Fig. 155). Amputations and disarticulations of the toes are analogous to those of the fingers. For the phalanges and inter-phalangeal joints the oblique circular incision is indicated, whilst for the metatarsi and metatarso-phalangeal joints the racket incision is made. The dorsal part of the incision extends down to the bone, which is removed subperiosteally.

In the case of the great and little toe the dorsal portion of the incision is not placed over the middle of the phalanx and metatarsus, but more towards the middle line of the foot, so that the cicatrix may be out of reach of lateral pressure.

213. Disarticulation of all the Toes (Metatarso-Phalangeal Disarticulation) (Fig. 156). Each toe is dealt with separately as follows. It is dorsiflexed, and an incision is carried round it where it emerges from the general cutaneous envelope of the foot. When complete, all the incisions should unite at the webs. Upon the plantar aspect this incision runs exactly along the furrow between the digits and the ball of the toes. A dorso-lateral incision is added over the metatarso-phalangeal joints of the great and little toes. In this way two rectangular flaps are formed.

The toes being now markedly bent towards the sole, the extensor tendons are divided as high up as possible, the lateral ligaments and the dorsal and plantar portions of the capsule are divided with a small knife, and lastly the plantar tendons are cut across as high up as possible.

214. Amputation through the Metatarsus (Fig. 157). This operation has the advantage over the tarso-metatarsal disarticulation in that the insertions of the chief muscles of the foot are all retained, not merely the tibialis posticus and peroneus longus, but also the tibialis anticus and the peroneus brevis and tertius. Hence the foot retains its normal movements in all directions. It is also very serviceable as a

support, as the important projection at the base of the 5th metatarsal is left, and the only one which is wanting is that of the head of the 1st metatarsal.

An oblique circular incision is made so as to form a plantar flap. This is at once dissected up in such a way that the place of division of the bones is reached by dividing the muscles obliquely upwards with

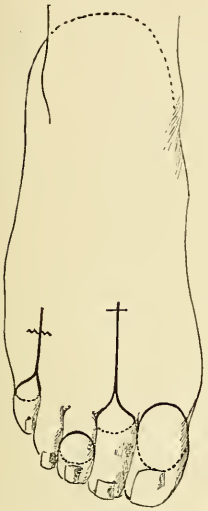

FIG. 155.—Disarticulation of the great toe at the metatarso-phalangeal joint, and of the 2nd toe along with its metacarpal bone; amputation through the 3rd toe, and through the 5th metatarsal bone.

FIG. 156.—Disarticulation of all the toes at the metatarso-phalangeal joints.

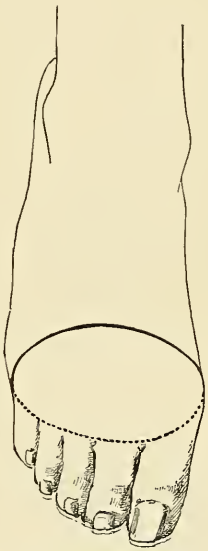

FIG. 157.—Amputation through the metatarsus.

long strokes of the knife, in order to preserve the branches of the internal and external plantar arteries. After cutting round the metatarsal bones one after another with a small scalpel, they are sawn through.

215. Disarticulation at the Tarso-Metatarsal Joints—between the metatarsus anteriorly and the three cuneiforms and cuboid posteriorly (LISFRANC'S operation) (Figs. 158 and 159). The plantar flap extends down to the middle of the ball of the toes. The line of disarticulation is indicated laterally by the projection of the tuberosity at the base of the 5th metatarsal, immediately behind which is the line of the joint

(Fig. 159). At the inner side a small projection may be distinctly felt at the base of the 1st metatarsal. The line of the joint is exposed by adding two dorso-lateral incisions to the obliquely circular one.

It is easier to make a longer rounded-off plantar flap passing through the middle of the ball of the toes, and a short dorsal flap (convex incision) a thumb's breadth in front of the line of the joint, the two meeting laterally behind the joint. The line of the joint is convex forwards and outwards; it has an upward indentation cor-

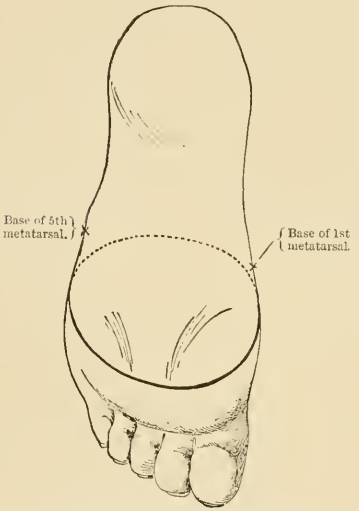

FIG. 158.—Disarticulation at the tarso-metatarsal joints (LISFRANC'S operation).

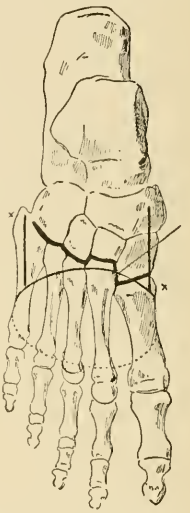

FIG. 159.—Line of the tarso-metatarsal joints; and incisions for LISFRANC'S operation.

responding to the retreating middle cuneiform bone, which lies, as compared with the internal cuneiform, as much as 2 to 3 mm. behind the convex joint line, and 1 cm. behind it as compared with the external. The joint is opened opposite the 1st, 3rd, 4th, and 5th, and lastly opposite the 2nd metatarsal. The strongest ligament is between the internal cuneiform and the base of the 2nd metatarsal (Fig. 159), and it is only after this has been divided that the joint can be opened out.

As in all operations upon the foot, the vessels are retained in the plantar flap.

In cases where there is an insufficient skin covering, removal of the projecting internal cuneiform does not interfere with the functional

activity of the foot any more than does the typical LISFRANC'S operation.

216. Anterior Intertarsal Disarticulation (JÄGER) (Fig. 160)—between the three cuneiform bones anteriorly and the scaphoid posteriorly, the cuboid being sawn across. The operation is performed in a manner similar to LISFRANC'S, except that somewhat less skin is preserved. The method has an advantage over CHOPART'S amputation in retaining the strong ligaments which pass from the os calcis to the cuboid and scaphoid bones.

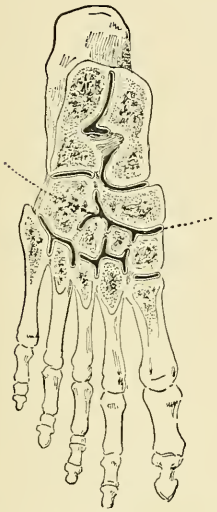

FIG. 160.—Anterior intertarsal disarticulation (JÄGER). Horizontal section of the foot (HEITZMANN).

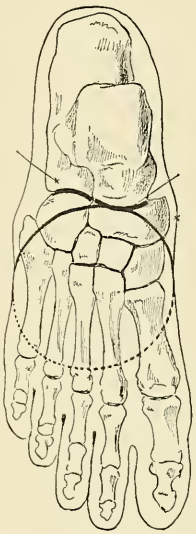

FIG. 161.—Posterior intertarsal disarticulation (CHOPART'S operation).

217. Posterior Intertarsal Disarticulation (CHOPART'S operation) (Fig. 161). The disarticulation takes place between the os calcis and astragalus posteriorly and the cuboid and scaphoid anteriorly. The operation often results in a bad stump from the foot assuming the equinus position, and pressure occurring at the anterior and lower part of the os calcis. To prevent this, it is recommended to divide the tendo Achillis, and to secure primary healing.

Internally the joint line lies behind the projecting tubercle of the scaphoid, externally in front of the ridge on the greater process

of the os calcis. The oblique incision corresponds on the dorsum to the line of the joint, and crosses the sole at the posterior part of the ball of the toes. Disarticulation is facilitated by the addition of two short dorsal incisions close to the borders of the foot. The operation is still easier if two rounded flaps are made, the dorsal extending a thumb's breadth in front of the line of the joint, and the plantar reaching down to the balls of the toes.

The joint between the astragalus and scaphoid, which is convex forwards, is opened from above; that between the os calcis and cuboid, which is concave forwards, is opened from the outer aspect, the knife being directed somewhat forwards towards the toes. If the knife be directed backwards, it may open the joint between the os calcis and astragalus.

The chief structures which unite the bones are the inferior calcaneo-scaphoid and the calcaneo-cuboid ligaments.

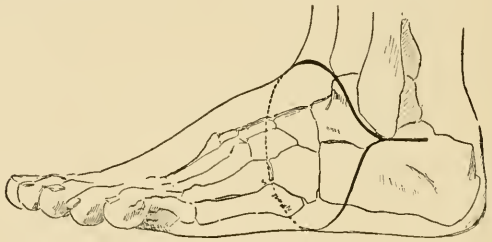

Fig. 162.—Subastragaloid disarticulation (Malgaigne, Textor).

218. Amputation through the Posterior Tarsus. When the soft parts are insufficient for a Chopart's amputation, the articular surfaces of the astragalus and os calcis are sawn off after disarticulating as in Chopart's operation. A movable stump may still be obtained, as the capsule of the ankle-joint (which does not extend farther forwards than 1 cm. behind the cartilage of the head of the astragalus) need not be opened.

219. Subastragaloid Disarticulation (Malgaigne, Textor) (Fig. 162). A racket-shaped incision is made, the handle being placed horizontally immediately behind and below the tip of the external malleolus, and the circular incision carried round the foot at the level of Chopart's joint. The joint between the astragalus and scaphoid is opened from the dorsum, without opening the calcaneo-cuboid joint. A narrow knife is then passed backwards and slightly upwards beneath the head of the astragalus so as to divide the strong interosseous ligament between it and the os calcis. The soft parts are then dissected off the os calcis, first from its upper surface, then from its outer and under

surfaces, and lastly from its inner and posterior surfaces. The greatest difficulty is met with at the inner side in clearing the projecting sustentaculum tali.

If the soft parts are insufficient, the projecting head of the astragalus may be sawn off.

220. Subastragaloid Osteoplastic Amputation. This operation, introduced by HANCOCK, consists in sawing off the tuberosity of the os calcis, and applying it to the lower surface of the astragalus, from which the articular cartilage has been sawn off. The circumstances in which this operation is called for are exceptional.

221. Disarticulation at the Ankle-Joint (SYME'S operation) (Figs. 163, 164). This operation was performed by SYME by means of a flap taken from the heel. The disadvantage of the method is that after the heel flap has been brought into position a cavity still exists between it and the bones.

FIG. 163.—Disarticulation at the ankle-joint (SYME'S amputation modified).

We recommend a flap from the inner aspect of the foot made by means of a racket-shaped incision, as shown in Fig. 163.

After dividing the skin, the strong bands of the external lateral ligament, the peroneal tendons, and the extensor tendons are cut across at the level of the retracted skin. The ankle-joint is opened, and the inner aspect of the os calcis is dissected from above downwards from the internal flap by keeping close to the bone. The malleoli are cleared and the ends of the bones sawn off.

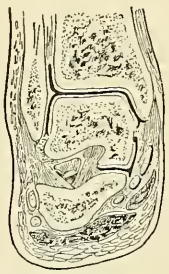

FIG. 164.—Coronal section through the ankle-joint (HENLE).

222. Osteoplastic Amputation at the Ankle-Joint (PIROGOFF) (Fig. 165). The tuberosity of the os calcis is sawn off and applied to the sawn surface of the tibia and fibula. The great advantage of retaining the tuberosity of the os calcis is that it fills the cavity or cup in the

heel flap, and that the skin of the latter is well nourished. It is thus preferable to the original operation of SYME.

The simplest and most certain method of performing the operation is as follows. Tenotomy of the tendo Achillis is first performed. The foot being held at a right angle, an incision is carried from the middle of one malleolus vertically downwards in the axis of the leg and across the heel to end at the middle of the opposite malleolus (stirrup incision). The whole of the incision extends down to the bone so as to divide all the tendons completely. Its extremities are united by a second incision passing forwards across the dorsum of the foot exactly at right angles to the stirrup incision, and reaching a full thumb's breadth in front of the line of the ankle-joint. It is carried through the skin and fascia only, the extensor tendons being divided at its retracted edge.

The ankle-joint is now opened from the front, the lateral ligaments

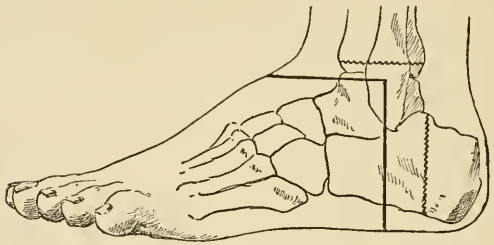

FIG. 165.—Osteoplastic disarticulation of the foot (PIROGOFF).

divided, and the astragalus exposed as far back as its posterior surface. The tuberosity of the os calcis is then sawn off vertically immediately behind the astragalus in the same plane as the heel incision, and is turned upwards along with the skin of the heel. The malleoli are freed and sawn off along with the articular surfaces of the tibia and fibula. The sawn surfaces are brought into accurate apposition by suturing the flap. The subsequent gait is excellent. Many surgeons have sawn the os calcis obliquely (SCHEDE, VOLKMANN), or horizontally (DUPASQUIER, LEFORT), or in a curved and angular direction (BRUNS, BÖCKEL).

An oval incision (similar to that shown in Fig. 162) beginning horizontally under the apex of the external malleolus, is to be recommended for sawing the os calcis horizontally. The horizontal portion of the incision gives sufficient room for sawing.

Compared with the method above described, all these modifications have the disadvantage that a part of the scar comes to lie near the under surface of the stump.

223. Amputations through the Leg (Figs. 166, 167, 168). The

incisions to be recommended are sufficiently indicated in the illustrations; and for the way in which the operation is performed reference must be made to the description of amputations in general. The oblique circular incision is that which we most frequently employ. At the upper and lower extremities of the leg the flap is best placed anteriorly so as to

FIG. 166.—Amputation through the malleoli.

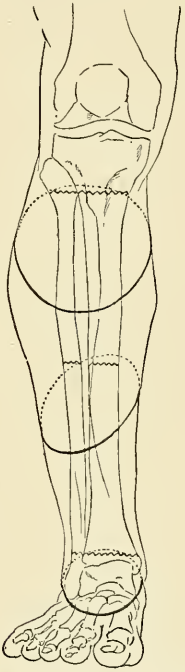

FIG. 167.—Amputations through the leg below the knee, in the middle third, and through the malleoli.

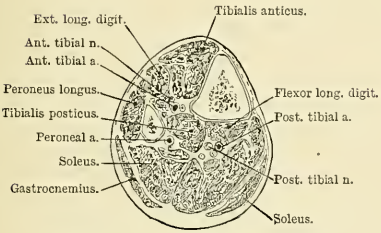

FIG. 168.—Transverse section through the leg above its middle (from a photograph).

cover the epiphyses, which should be sawn across in a curved direction. POUCET'S observations have shown that the foot may also be disarticulated by means of a dorsal flap, and that the stump obtained is suitable for bearing pressure.

In the region of the shaft, on the other hand, the oblique circular incision is directed in such a way that the flap is placed antero-externally, so that the anterior border of the tibia (which should always be rounded

off) does not press so much upon it. The periosteum of the inner surface of the tibia should be included in the flap, to act as a further protection against the bone.

More recently it has been sought to obtain a cushion to cover the ends of the bones in the case also of amputations through the shafts of the bones of the leg, and so make it possible for the patient to bear his weight upon the stump. Ollier has employed a heel flap for amputations above the ankle, and Kummer has reduced the heel flap to a suitable length simply by allowing it to granulate and shrink before applying it to the stump.

The interosseous membrane adheres firmly to the bones, and is to be dissected back with a knife along with the periosteum. The muscles

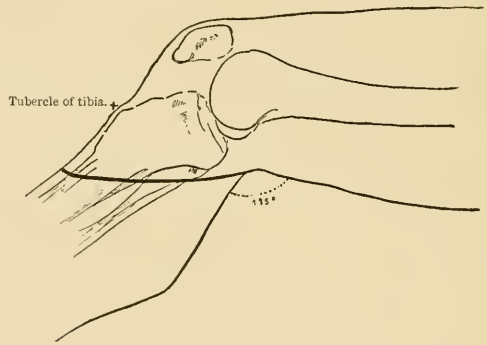

Fig. 169.—Disarticulation at the knee-joint.

which lie between the bones must be cut across transversely so as to divide the vessels at the lower extremity of the flap.

The anterior and posterior tibial vessels—the former lying upon the interosseous membrane, the latter upon the deep muscles of the calf—are met with along the whole length of the leg; and in addition, in the lower two-thirds, the peroneal artery, which lies between the flexor longus hallucis and the posterior surface of the fibula.

Attempts have recently been made to obtain, at the lower half of the leg, a stump which is capable of bearing the weight of the body. With a stump at the upper half of the leg the patient can walk with the knee flexed.

Bier, following the principle of Sabanejeff (see page 291), has made a sort of substitute for the foot by first amputating through the lower part of the leg, and then performing a cuneiform osteotomy of the tibia above the stump, so as to allow the latter along with the lower fragment

to be bent forwards to a right angle to the upper fragment, to which it becomes osseously united. The patient walks upon the posterior surface of the lower fragment, which is padded by the muscles of the leg.

BRUNS, after well retracting the skin, makes a circular incision passing at once down to the bones. To this are added two vertical lateral incisions, and the two flaps along with the periosteum are dissected up as far as the place at which the bones are to be sawn across.

224. Disarticulation at the Knee-Joint (Figs. 169 and 170). If the wound runs an aseptic course, this operation gives an excellent stump. It is not yet certain whether the preservation of the cavity of the joint (SOCIN) is a permanent advantage. An anterior flap is obtained by making an oblique oval incision, beginning posteriorly opposite the level of the joint, and ending anteriorly four finger-breadths below the tubercle of the tibia. If the leg be held with the knee half bent (making an angle

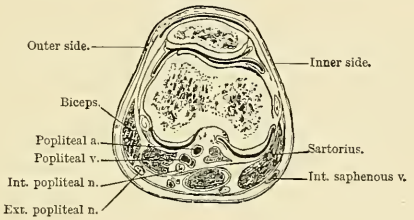

FIG. 170.

of 135° with the thigh), the incision falls in the continuation of the long axis of the thigh (Fig. 169). After dissecting up the skin and fascia, the capsule with the ligamentum patellæ, the semilunar cartilages, and lateral ligaments are cut through anteriorly and laterally; the crucial ligaments are separated from the spine of the tibia; the posterior part of the capsule is cut through along the tibia; and the operation is completed by making a transverse incision through the soft parts posteriorly.

When it is necessary to remove the patella, the flap is folded back, and after cutting round the edge of the patella the latter is removed subperiosteally.

225. Amputations through the Thigh (Figs. 171 to 174) were formerly among the most frequent amputations, and are so still. The oblique circular incision is to be recommended at all levels. Circular incisions may also be employed, but not at the lower end, on account of the bad position of the scar.

226. Amputation through the Condyles (CARDEN and BUCHANAN)

(Fig. 171). BUCHANAN, in amputating at the lower end of the femur in children, simply separated the lower epiphysis of the femur.

CARDEN sawed off the condyles in a curved direction through their greatest breadth, obtaining in this way an excellent stump, and one

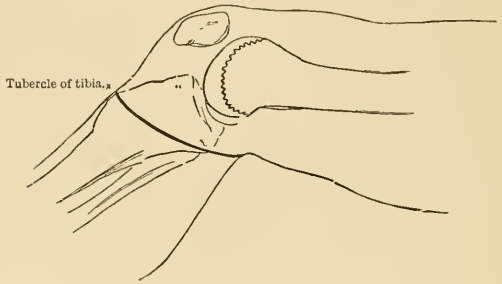

FIG. 171.—Amputation through the condyles (CARDEN).

FIG. 172.—Osteoplastic supracondyloid amputation (GRITTI).

well adapted for bearing weight. The incision begins posteriorly at the level of the epicondyles, and reaches down to the tubercle of the tibia anteriorly.

227. The Supracondyloid Amputation (Fig. 173) is performed by an oblique incision with the flap towards the anterior and inner aspect (LANGENBECK), because, were a strictly anterior flap made, the adductors

of the thigh, which draw the femur forwards and inwards, would cause it to press against the inner angle of the wound.

A modification of this operation (which is frequently called for) is GRITTI'S supracondyloid amputation (Fig. 172).

An oblique incision is made with its upper end situated posteriorly immediately above the condyles; its lower end extends anteriorly to two finger-breadths below the patella. The ligamentum patellæ is divided at its upper end. The articular surface of the patella is sawn off, and is applied to the sawn surface of the femur, and if necessary firmly nailed down to it.

Along with GRITTI'S operation is to be placed that of SABANEJEFF, which according to EHRLICH is well spoken of by W. KOCH. It consists in sawing horizontally through the broadest part of the condyles, and applying to them a flap of bone removed from the anterior surface of the upper end of the tibia. For this purpose an anterior flap must be made extending as far down as the middle third of the leg. The knee-joint is opened from behind.

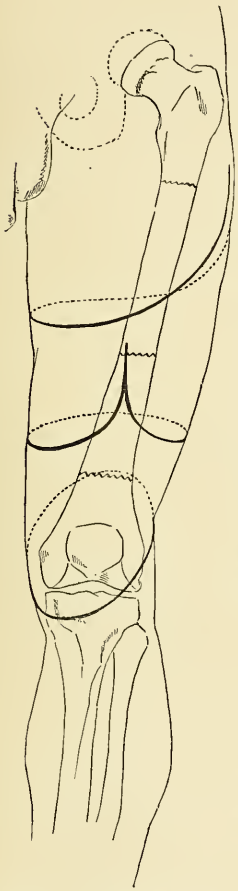

FIG. 173.—Amputation of the thigh below the trochanters; through the middle of the femur; above the condyles (supracondyloid).

228. Amputation through the Middle of the Thigh. In muscular limbs two short flaps are made, and after retracting them, a clean cut is carried transversely through

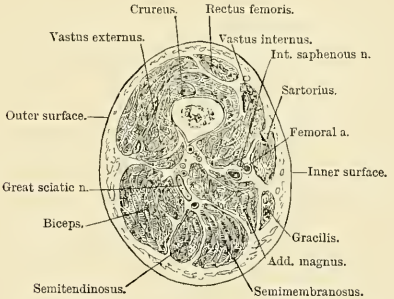

FIG. 174.—Transverse section through the thigh (from a photograph).

the muscles (Lisfranc and Esmarch). A very clean wound can also be made by dividing the muscles by transfixion, after the skin has been divided. In very muscular limbs, the periosteum is separated upwards for several centimetres so that a sufficient skin covering may be obtained, and in order to provide a periosteal covering for the sawn surface of the bone.

229. Amputation below the Trochanters (Fig. 173) is performed by an oval incision in the same way as in disarticulating at the hip-joint. The longitudinal portion of the incision is made upon the outer aspect of the thigh, extends down to the bone, and allows it to be cleared subperiosteally up to where it is sawn across.

In amputating in the lower third of the thigh, the femoral vessels, and anteriorly and internally the anastomotica magna, and possibly also the superior articular branches of the popliteal, require to be ligatured. In the upper two-thirds, besides the femoral vessels, the profunda, and in the upper third the large branches of the external circumflex, must be ligatured.

230. Disarticulation at the Hip-Joint (Figs. 175 and 176). Formerly the removal of the lower extremity at the hip-joint was attended with immediate danger to life. Thanks, however, to the improvements in the method of operation, it may now be undertaken without hesitation even in comparatively feeble persons.

Rose, following the example of Beck (Lüning), removed the thigh like a tumour by dividing the larger vessels between two ligatures, and ligaturing the others immediately after dividing them. This *extirpation method* is the most suitable when the tumour extends high up in the region of the hip-joint. In such cases the soft parts can only be partially retained. For this reason no special description can be given of the operation to be performed, as this must necessarily vary in different cases. It is always desirable, however, to place the incision so that the main vessels (as in removing the upper extremity along with the shoulder girdle) can be ligatured at the outset, *i.e.* the angle of the incision is to be placed over the femoral vessels. In this way all bleeding is prevented with the exception of that from the obturator, gluteal, sciatic, and possibly the internal pudic arteries. If, however, forceps be at once applied to the bleeding vessels after dividing them, further hæmorrhage is reduced to a minimum. This should be carried out in all cases where the soft parts in the region of the hip-joint may be retained, because the function of the muscles in the stump is of the greatest value subsequently. Especially when the operation is done subperiosteally, a stump is obtained which can be actively moved in all directions, just as in amputation below the trochanters.

Hæmorrhage is arrested by an elastic tourniquet, which, to prevent it slipping downwards, must always be applied in the form of a figure of eight round the thigh and pelvis. The complicated

precautions of TRENDELENBURG, SENN, and WYETH may have advantages in individual cases, but as a rule they are unnecessary. TRENDELENBURG transfixes the limb with steel rods passed towards the inner side from the resection wound, and then winds a rubber tube around them in the form of figures of eight. SENN passes a double rubber tube through the limb from the wound for resecting the hip-joint, and ties the soft parts in two halves. WYETH prevents the rubber tourniquet from slipping by transfixing the limb with two large steel pins.

A circular incision is made through the skin at the level estimated in the usual way (*vide* p. 275), the muscles are divided down to the bone at the level of the edge of the retracted skin, and after dividing the periosteum the bone is sawn across. The vessels are now carefully ligatured and the tourniquet removed.

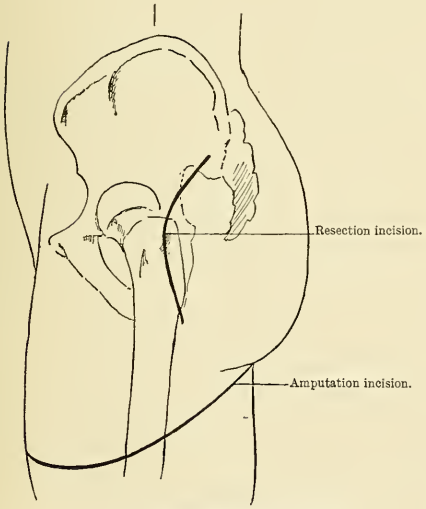

FIG. 175.—Disarticulation at the hip-joint.

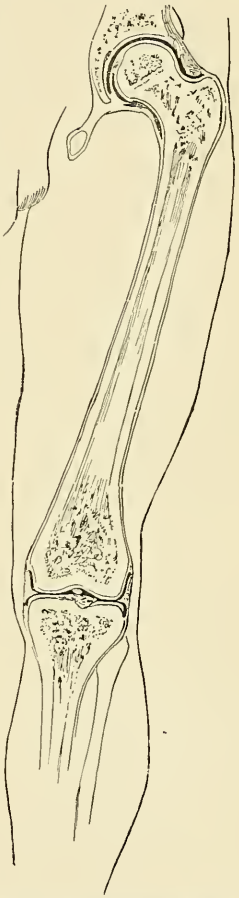

FIG. 176.—Coronal section of the hip- and knee-joints (after HENLE).

Instead of the simple circular incision, it is better to make an oval incision prolonged upwards upon the outer side of the bone (Fig. 173). In some cases it may be necessary to make short anterior and posterior flaps.

The disarticulation of the upper end of the femur is performed in various ways.

Beck, after amputating, divides the soft parts at the outer surface of the femur, and dissects out the bone subperiosteally by detaching with a knife the attachment of the periosteum at the linea aspera, the insertions of the muscles (glutei, pyriformis, obturator externus, obturator internus and gemelli, and the quadratus femoris) into and below the great trochanter, the ilio-psoas into the lesser trochanter, and the attachments of the capsule in the region of the anterior and posterior inter-trochanteric lines. The ligamentum teres is torn across by twisting round the femur.

Since 1876 we have had faultless results—nine cases, with no deaths (reported by Roux). Our method of operating is as follows. Incision the same as that described for excision of the hip, namely, in a curved direction over the great trochanter and through the fibres of the gluteus maximus, but shorter than the ordinary resection incision. The fibres of the gluteus maximus are separated in the line of the incision, and drawn apart. Branches of the gluteal and circumflex arteries are ligatured, the capsule of the joint is divided, and the insertions of the muscles (the glutei anteriorly, and the pyriformis, obturators, and quadratus posteriorly) are separated from their attachments close to the trochanter. The head of the femur is now dislocated, the ligamentum teres being divided or torn through. The soft parts are separated forwards and backwards from the great trochanter as far down as the lesser trochanter, where the strong insertion of the ilio-psoas is divided with a knife.

After completely arresting the bleeding, the limb is held up vertically, and an Esmarch's tourniquet applied in the form of a figure of eight around the highest part of the thigh and pelvis. The crossing of the figure of eight must be upon the posterior and outer aspect, that is to say, behind and above the great trochanter, so that sufficient pressure is exerted anteriorly.

The limb is now amputated below the trochanters. The skin incision is either circular or lanceolate, or two short skin flaps are formed according to the amount of skin available. The skin is then retracted, and the muscles are cut with a clean sweep down to the bone. The soft coverings must always be abundantly calculated for. After being divided the periosteum must be separated up with a blunt instrument, but the knife must be used to detach it from the linea aspera. The bone is then sawn across, and all visible vessels—first the femoral, then the profunda vessels, the internal saphenous vein, and the

numerous small arteries—must be carefully ligatured, and the tourniquet removed.

The stump of the upper part of the femur is now surrounded with aseptic gauze and grasped while the remaining connections are freed from it subperiosteally, after which it is drawn out of the wound. Drains are introduced through special openings close to the resection and amputation wounds, both of which are closed by layers of sutures.

Roux, in the paper already referred to, has drawn some comparisons between our operation and the methods employed by Volkmann, Guyon, and Reverdin.

Y. UPPER EXTREMITY

231. Amputation and Disarticulation of the Fingers (Figs. 177 and 178). The chief rule in the fingers is to endeavour to retain a stump, no matter how short, provided the tendons remain connected with it, and that it can be covered with sound skin. Any method may therefore be used, but a flap from the palmar aspect is preferable, as it avoids a palmar cicatrix. The oblique circular incision is most to be recommended, and is essential in the case of

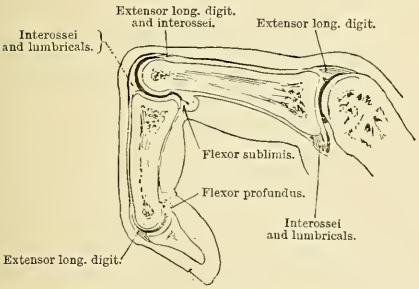

Fig. 177.—To show the line of the joints in the flexed position of the finger.

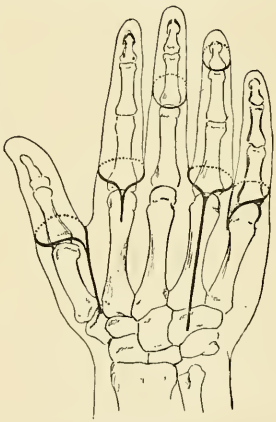

Fig. 178.
Disarticulation of little finger.
,, ,, index finger.
,, ,, ring finger along with its metacarpal bone.
,, ,, thumb along with its metacarpal bone.
(Dorsal aspect of hand.)

the terminal phalanx. The line of the joints is easily made out, because with the finger flexed they are always placed on the distal side of the dorsal

bony prominences (Fig. 177). In disarticulations at the interphalangeal joints the knife is applied over the joint line, and directed obliquely downwards towards the palmar aspect. By forcibly flexing the finger, the attachment of the extensors at the base of the phalanx, then the dorsal part of the capsule, the lateral ligaments, the anterior part of the capsule, and lastly the flexor tendons, are divided.

In amputations, the palmar flap must be turned back before the rest of the incision is carried round the bone.

In disarticulating a finger at the metacarpo-phalangeal or at the carpo-metacarpal joint, the *lanceolate incision* is used, the longitudinal portion extending backwards over the head of the metacarpal bone, or, in the latter case, over its base. The tendons are divided at the edge of the retracted skin. The periosteum is divided and separated along with the capsule.

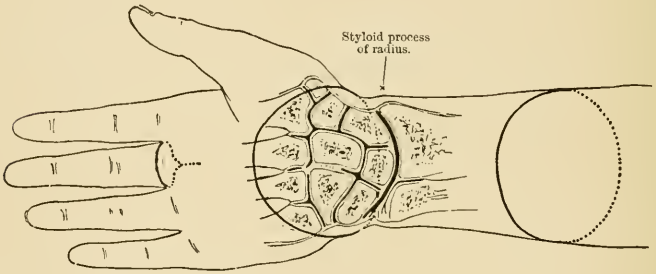

FIG. 179.—Disarticulation of middle finger. Disarticulation of the hand at the wrist-joint. Amputation through the forearm.

In the case of the thumb, the index finger, and the little finger, the dorsal part of the incision is placed towards the middle line of the hand instead of over the middle of the bone or joint.

In removing the metacarpal bone of the thumb or little finger, it is especially important to preserve intact the short muscles of the thenar and hypothenar eminences, because by so doing a very useful and movable stump is obtained, especially if the bone is removed subperiosteally.

In disarticulating a finger, with or without its metacarpal bone, the transverse incision follows exactly the line of the web of the fingers; incisions must not be made higher up in the palm.

232. Disarticulation at the Wrist-Joint (Fig. 179). Very different methods are admissible for this operation, as for amputation through the forearm, the object being to obtain as long a stump as possible. In contrast to the main rule for the foot, an amputation must not be

performed transversely through the wrist as long as a movable finger or portion of the hand can be retained.

An oblique incision is made with its upper end at the level of the wrist-joint and its lower end about the middle of the palm. With the hand fully flexed towards the palm, the extensor tendons and the posterior ligament are divided, whilst below the projecting styloid processes the lateral ligaments and tendons (extensor carpi ulnaris and the three extensors of the thumb) are cut across, and the joint is opened. The bundle of flexor tendons are separated from the carpus and divided along with the skin at the extremity of the palmar flap. The palmar flap has the advantage of being very well nourished, of possessing fine tactile sensibility, and, in certain circumstances, of forming a movable muscular stump.

The vessels which require a ligature are these—on the palmar aspect the ulnar or the superficial palmar arch, the branch to the deep arch, and the superficial volar branch of the radial; on the dorsal aspect the radial artery.

233. Amputations through the Forearm (Figs. 179 and 180) present no peculiarities which necessitate departure from the general rules. For the same reasons as in the hand, an oblique incision with

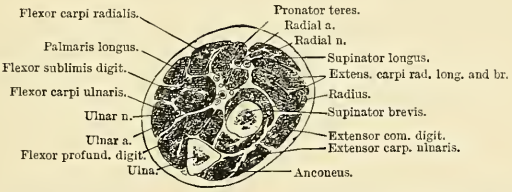

Fig. 180.—Transverse section through the upper third of the forearm (from a photograph).

an anterior flap is to be recommended. This prevents the formation of a cicatrix in front.

The radial, ulnar, and interosseous arteries must be ligatured.

234. Disarticulation at the Elbow (Figs. 181 and 182). In the operative course the error is repeatedly made of regarding the tip of the olecranon as the guide to the line of the elbow-joint. The head of the radius is the proper guide. It can always be felt at the posterior aspect of the elbow.

An oblique incision is made, beginning above and anteriorly at the line of the joint, and ending posteriorly a hand-breadth below the tip of the olecranon. With the elbow bent to an angle of 135°, the incision is parallel to the prolonged axis of the upper arm. The posterior flap, together with the periosteum, the anconeus, and the insertion of the triceps,

is dissected up beyond the tip of the olecranon as far as the posterior surface of the humerus. In front, the soft parts and capsule of the joint

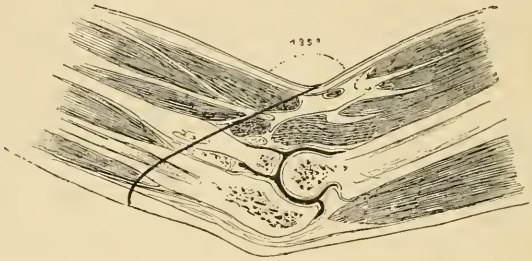

FIG. 181.—Disarticulation at the elbow-joint.
(Longitudinal section through the elbow-joint, after BRAUNE.)

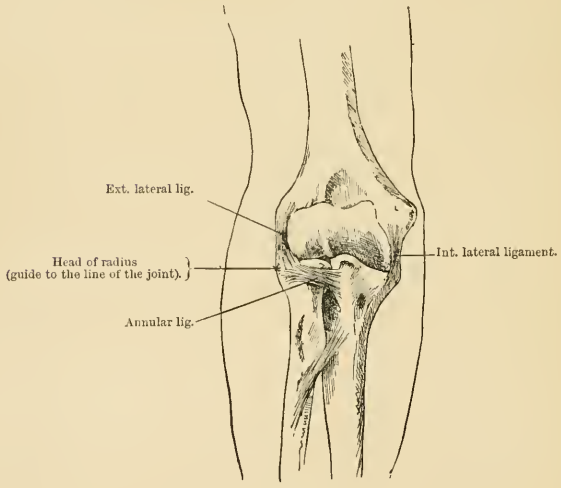

FIG. 182.

are divided transversely. The flap being held aside, the radio-humeral joint is opened from without inwards.

235. Amputation through the Upper Arm (Fig. 183). In order that a broad covering may be obtained for the stump, it must be borne in mind that the upper arm is markedly flattened from side to side.

Flaps are to be taken from the broad aspect. Accordingly, when oblique incisions are made, the upper end should fall over the internal bicipital sulcus. The biceps retracts very much.

The surgical neck of the humerus limits the height up to which a useful stump can be got in amputating through the upper arm, because the capsule extends down to this level internally. The other factors determining the future usefulness of the stump are the insertions of the deltoid, pectoralis major, and latissimus dorsi muscles, these being the chief adductors and abductors of the stump. The brachial and superior profunda

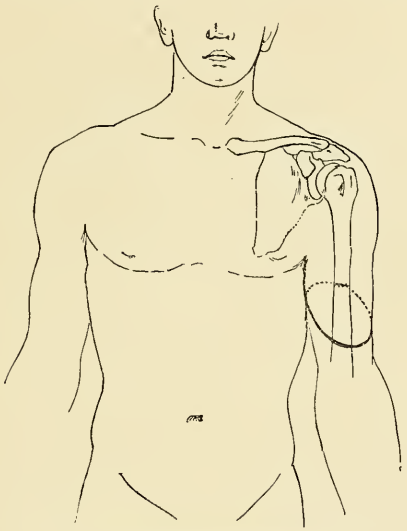

FIG. 183.—Amputation through the upper arm.

arteries, together with the smaller arteries, namely, the inferior profunda and possibly the anastomotica magna, must be ligatured. When the bone is sawn where the musculo-spiral nerve winds round it, it is very important to resect the end of the nerve.

As regards the rules for the high amputation, compare disarticulation of the humerus.

236. Disarticulation at the Shoulder-Joint (Fig. 184). In disarticulation at the shoulder-joint, as in the corresponding operation at the hip, it is important whenever possible to preserve a musculo-periosteal stump so that an artificial limb may be worn.

The incision is planned with a view to this object. As in the hip, a circular amputation may be performed at the level of the axillary fold, and after sawing the bone an anterior longitudinal incision is added, through which the upper end of the humerus is removed (*racket incision*). This, however, is not necessary, as the hæmorrhage may be controlled with equal certainty by a continuous *lanceolate incision*.

This method is especially applicable in cases in which the arm is

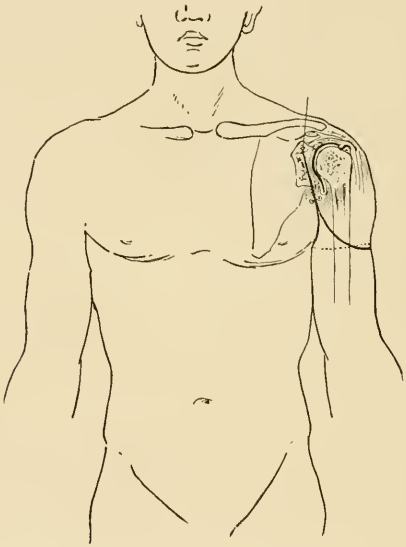

FIG. 184.—Disarticulation at the shoulder-joint.

crushed and the humerus broken. Bleeding must be carefully arrested because of the accompanying shock and anæmia.

The longitudinal part of the incision begins at the clavicle external to the coracoid process, and passes downwards, dividing the anterior fibres of the deltoid. Bleeding vessels and the cephalic vein are ligatured. In the upper part of the wound the acromial branches of the acromio-thoracic are also ligatured. The knife is carried down to the bone at the edge of the deltoid (only the upper fibres of which have been divided). The capsule is divided over the lesser tuberosity and the bicipital groove. The periosteum, the insertions of the subscapularis, pectoralis major,

latissimus dorsi, and teres major are detached along with the capsule. The capsule, along with the insertions of the supraspinatus, infraspinatus, and teres minor muscles, is also detached from the upper part of the head and from the great tuberosity. The head of the humerus can now be protruded from the wound. In cutting down over the surgical neck it may be necessary to ligature the circumflex arteries, in any case the anterior.

The racket incision is now completed by dividing the skin circularly

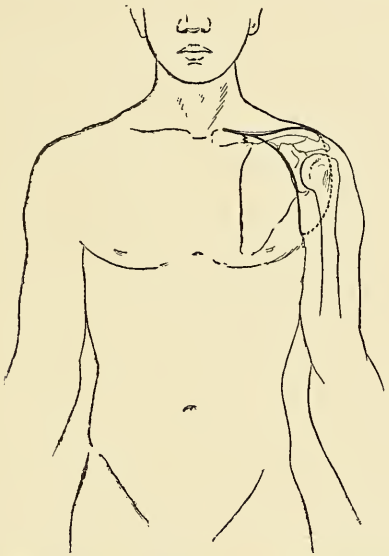

FIG. 185.—Removal of the upper extremity together with the shoulder girdle.

at the level of the axillary folds. The vessels and nerves are then easily isolated, the former being ligatured and the latter divided. The subscapular artery and nerves can be grasped and dealt with. The circumflex nerve, which courses over the teres major and behind the bone to supply the deltoid, is to be carefully avoided, as the deltoid is the chief muscle of the future stump.

237. Removal of the Upper Extremity together with the Shoulder Girdle (Fig. 185). This operation is usually performed on account of tumours which involve the shoulder-joint, the scapula, and possibly also the axillary glands, vessels, and nerves. There is therefore

no question of obtaining a stump. Cases are sometimes met with in which only a part of the scapula (acromion and glenoid) requires to be removed.

Hæmorrhage is best controlled by preliminary ligature of the great vessels, the incision being planned with this object, and of course modified when the skin is involved by the tumour.

A *lanceolate incision* is usually employed, beginning at the sternal end of the clavicle and passing along it to the acromion process. The periosteum of the clavicle is divided, and the bone sawn through at its inner third, drawn outwards with a hook, and the subclavius muscle carefully separated. The subclavian artery and vein, along with the cords of the brachial plexus, are exposed by dividing the muscle and the fascia. The nerves are cut across individually, and the vessels are divided between two ligatures.

If it be desired to restrict the hæmorrhage to a minimum, it is necessary to secure the branches of the subclavian which pass outwards in front of the scaleni. These are the ascending cervical passing vertically upwards, the superficial cervical passing upwards and outwards, the suprascapular passing horizontally beneath the clavicle, and lastly and most important the transversalis colli artery, which passes outwards and backwards over or through the brachial plexus to supply the levator anguli scapulæ and supraspinatus muscles, and is continued downwards as the posterior scapular artery along the vertical border of the scapula, between the rhomboids and the serratus posticus superior. No important hæmorrhage need now be anticipated.

The operation is now proceeded with according to the method originally proposed by Rose for disarticulation at the hip, that is to say, as if the arm and scapula constituted a tumour which one had to excise. The skin incision is prolonged downwards towards the anterior fold of the axilla, the pectoralis major and minor cut across, and the vessels secured and ligatured. When the axilla contains infected glands, the muscles are divided close to the thorax and the vessels secured. In the absence of infected glands the muscles are divided close to their insertions into the humerus and coracoid process respectively.

The dissection is continued along the outer wall of the thorax towards the serratus magnus and ventral surface of the scapula, infected glands should they exist being at the same time raised from the thorax. When the posterior fold of the axilla is reached, the latissimus dorsi is divided close to its insertion, or nearer the thorax if the glands are involved.

The arm and shoulder are now rotated outwards so as to completely expose the ventral aspect of the scapula and its muscles. At the upper angle, the thick insertion of the levator anguli scapulæ is divided and branches of the posterior scapular artery secured. The thick serratus magnus and the thinner rhomboids are then divided in succession along

the vertebral border of the scapula. The arm and the scapula being now drawn away from the trunk, the trapezius is separated from the spine, and the omo-hyoid from the upper border of the scapula. The posterior skin incision is now completed from behind, as shown in Fig. 185, and the arm and shoulder girdle removed, without appreciable loss of blood.

Our method may be compared with that of BERGER, to whom belongs the credit of developing this operation. According to NASSE, BERGMANN proceeds on similar lines. It was ESMARCH who established the principle of dividing the clavicle and applying a preliminary ligature to the subclavian vessels.

THE END

Printed by R. & R. CLARK, *Edinburgh.*

COLUMBIA UNIVERSITY LIBRARIES

This book is due on the date indicated below, or at the expiration of a definite period after the date of borrowing, as provided by the library rules or by special arrangement with the Librarian in charge.

DATE BORROWED	DATE DUE	DATE BORROWED	DATE DUE
	SEP 3 1975		
C28(946)M100			

COLUMBIA UNIVERSITY LIBRARIES (hsl.stx)
RD 32 K811 1895 C.1
Chirurgische Operationslehre
[redacted]

RD32 K811
1895

Kocher
Text-book of operative surgery

SEP 3 1975 R. Trefferman

RD32 K811
1895

I. A.